

The implications of intradural extension in paraspinal malignant peripheral nerve sheath tumors: effects on central nervous system metastases and overall survival

Hannah Gilder M.D.¹, Ross C. Puffer M.D.¹, Mohamad Bydon M.D.¹, Robert J. Spinner M.D.¹

¹Department of Neurosurgery, Mayo Clinic, Rochester, Minnesota, USA

Abstract

Object: In this study, we sought to compare tumors with intradural extension to those remaining in the epidural or paraspinal space with the hypothesis that intradural extension may be a mechanism for seeding of the cerebrospinal fluid (CSF) with malignant cells, thereby resulting in higher rates of CNS metastases and shorter overall survival

Methods: All patients included in the study had tumor specimens reviewed by our surgical pathology department. Further information was collected on all patients with and without intradural extension, including date of diagnosis by pathology specimen review, nerve or nerves of tumor origin, presence, location, and diagnostic date of any central nervous system (CNS) metastases, and either the date of death or date of last follow-up.

Results: We identified 6/179 (3.4%) patients who had intradural tumor extension, and they were compared to 12 patients with paraspinal tumors that did not have intradural extension. Four out of six (66.7%) patients with intradural extension had documented CNS metastases. Time from diagnosis until death was 11.2 months in the intradural group, compared to approximately 72 months in the paraspinal, extradural cohort

Conclusions: In patients with intradural extension of paraspinal MPNSTs, significantly higher rates of CNS metastases are seen with a lower overall survival compared to those that don't progress intradurally..

Introduction

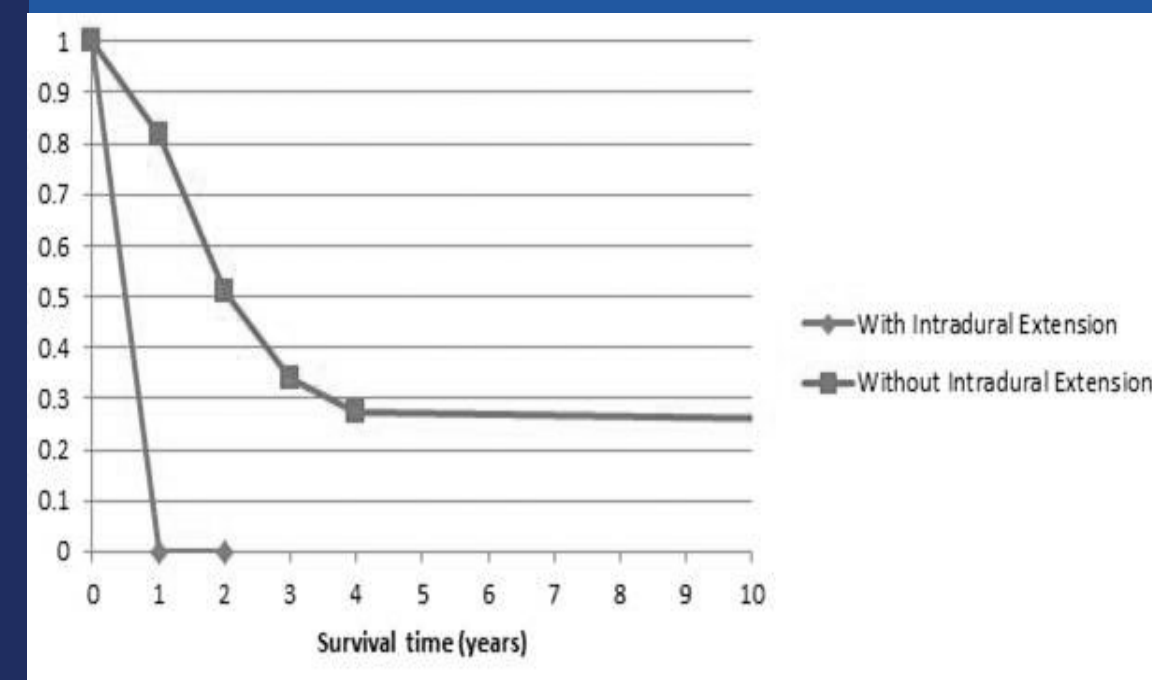
Malignant peripheral nerve sheath tumors (MPNSTs) are rare neoplasms accounting for less than 10% of all soft tissue sarcomas with an overall incidence of 0.001% in the general population

Although truncal location has been identified as a poor prognostic indicator and, more specifically, spinal tumors have been theorized to have a greater potential for brain metastases, no published literature to date has shown a potential mechanism for these hypotheses, although cerebrospinal fluid is the hypothesized route for malignant dissemination. In this study, we sought to compare tumors with intradural extension to those remaining in the epidural or paraspinal space with the hypothesis that intradural extension may be a mechanism for seeding of the cerebrospinal fluid (CSF) with malignant cells, thereby resulting in higher rates of CNS metastases and shorter overall survival.

Methods

We searched the medical record for cases of MPNSTs identified from 1994 to 2017. Within the cohort of patients with paraspinal MPNST, radiology and operative reports were reviewed in order to identify tumors with intradural spread. For the purposes of this study, intradural spread was established either by a radiology report identifying a tumor involving a spinal nerve with contiguous spread of the mass through the epidural space and into the spinal canal; or by an operative report in which the surgeon described that in an attempt to resect the mass, the tumor had been dissected away from the dura and it was either apparent in the intraoperative setting that the tumor extended through the dura, or the pathology margins were found to be positive where the tumor came into contact with the dura. All patients included in the study had tumor specimens reviewed by our surgical pathology department. Further information was collected on all patients with and without intradural extension, including date of diagnosis by pathology specimen review, nerve or nerves of tumor origin, presence, location, and diagnostic date of any central nervous system (CNS) metastases, and either the date of death or date of last follow-up. This information was then analyzed and compared between groups.

Kaplan-Meier



Kaplan-Meier survival curves for patients with paraspinal MPNSTs with and without intradural extension

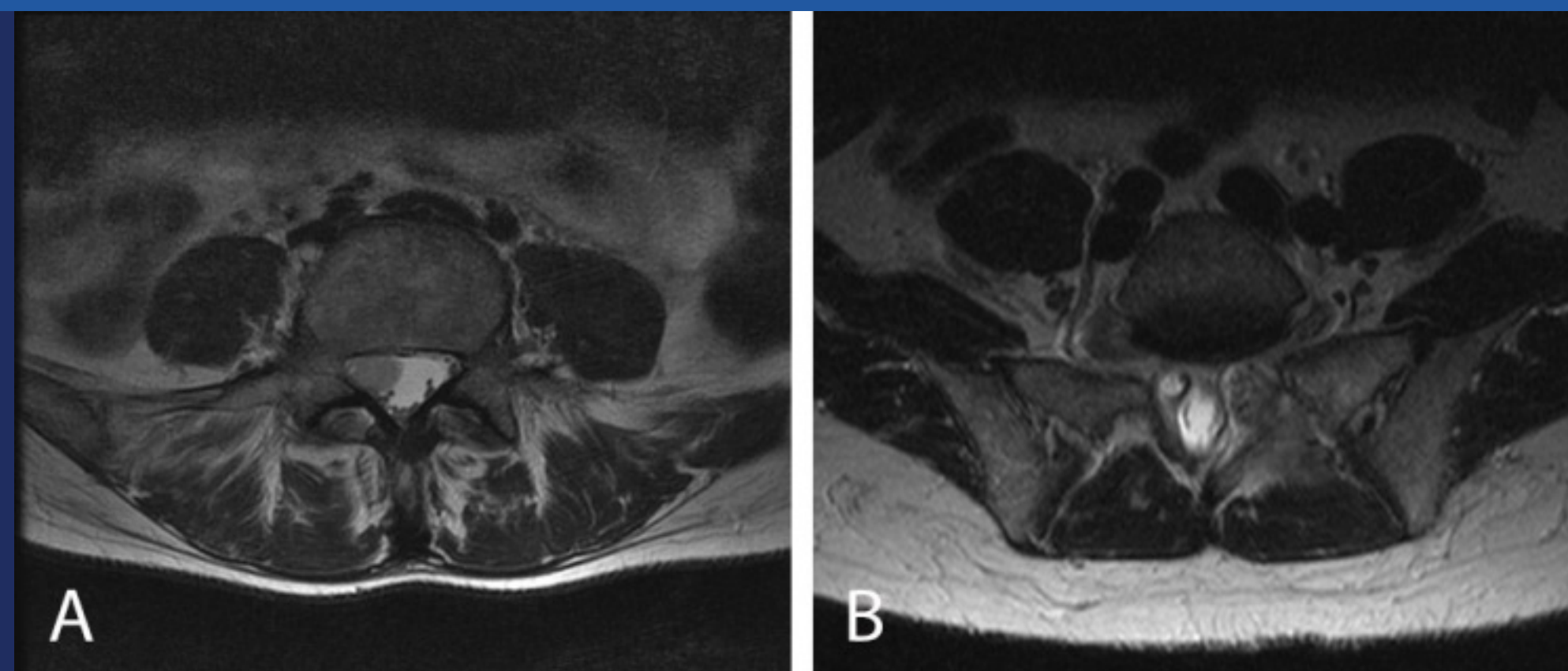
Results

Out of the entire cohort, we identified 6/179 (3.4%) patients who had intradural tumor extension. All tumors were diagnosed as high grade MPNST by surgical pathology. Five of these were in the lumbosacral region and one patient was found to have a mass along the spinal accessory nerve with extension through the jugular foramen, descending intradurally within the lower cranial nerve complex. In the cohort of patients with intradural extension, four out of six (66.7%) had documented CNS metastases. In the patients with metastatic disease, three had lesions discovered within the spine and one was diagnosed with brain metastases.

The presence of CNS metastases was significantly higher in the intradural group compared to the paraspinal group (intradural – 66.7% vs. paraspinal – 0%, $p < 0.01$). Time from diagnosis of intradural MPNST until discovery of CNS metastases ranged from three months to six months with a mean of 4.25 (SD=1.3 months). Time from diagnosis until death ranged from 3-22 months, with mean of 11.2 (SD=9.5 months), excluding one patient lost to follow-up.

Twelve patients were identified as comparison patients with lumbar or sacral spinal nerve high-grade MPNSTs that did not enter into the intradural space. In this cohort of patients, none were identified with metastatic disease to the brain or spine. Nine patients were deceased and three remained alive at final follow-up. Of the deceased patients, the average time from MPNST diagnosis to death was approximately 72 months. Three patients survived longer than 60 months, making the five-year survival rate 23%.

Figure 1



A 43-year-old woman presented with a 2 year history of unprovoked neuropathic pain extending from the left buttock, down the posterior leg, to the lateral calf. The pain had continued to worsen in intensity, and was accompanied by numbness extending into the left foot, and mild weakness of left foot dorsiflexion at the time of presentation. She had a medical history of cervical cancer, treated with full pelvis external beam radiation (4500 cGy) and cisplatin chemotherapy 9 years before her symptoms began. Preoperative MR imaging studies of the lumbar spine demonstrated a well-circumscribed, avidly-enhancing, fusiform mass with dumbbell morphology centered on the left L5 nerve and extending distally along the lumbosacral plexus. There was associated bony remodeling and expansion of the L5-S1 foramen.

Conclusions

- Paraspinal MPNSTs may have a propensity for progression into the intradural space
- The rate of CNS metastases is significantly higher, and overall survival is significantly shorter in patients with MPNSTs extending into the intradural space
- Identifying the presence of intradural extension of MPNST can have important treatment and prognostic implications