

Corneal Neurotization by Ipsilateral Great Auricular Nerve Transfer & Scleral Tunnel Incisions for Neurotrophic Keratopathy

Nate Jowett, MD and Roberto Pineda II, MD

Departments of Otolaryngology and Ophthalmology, Massachusetts Eye and Ear and Harvard Medical School, 243 Charles St, Boston, MA

BACKGROUND

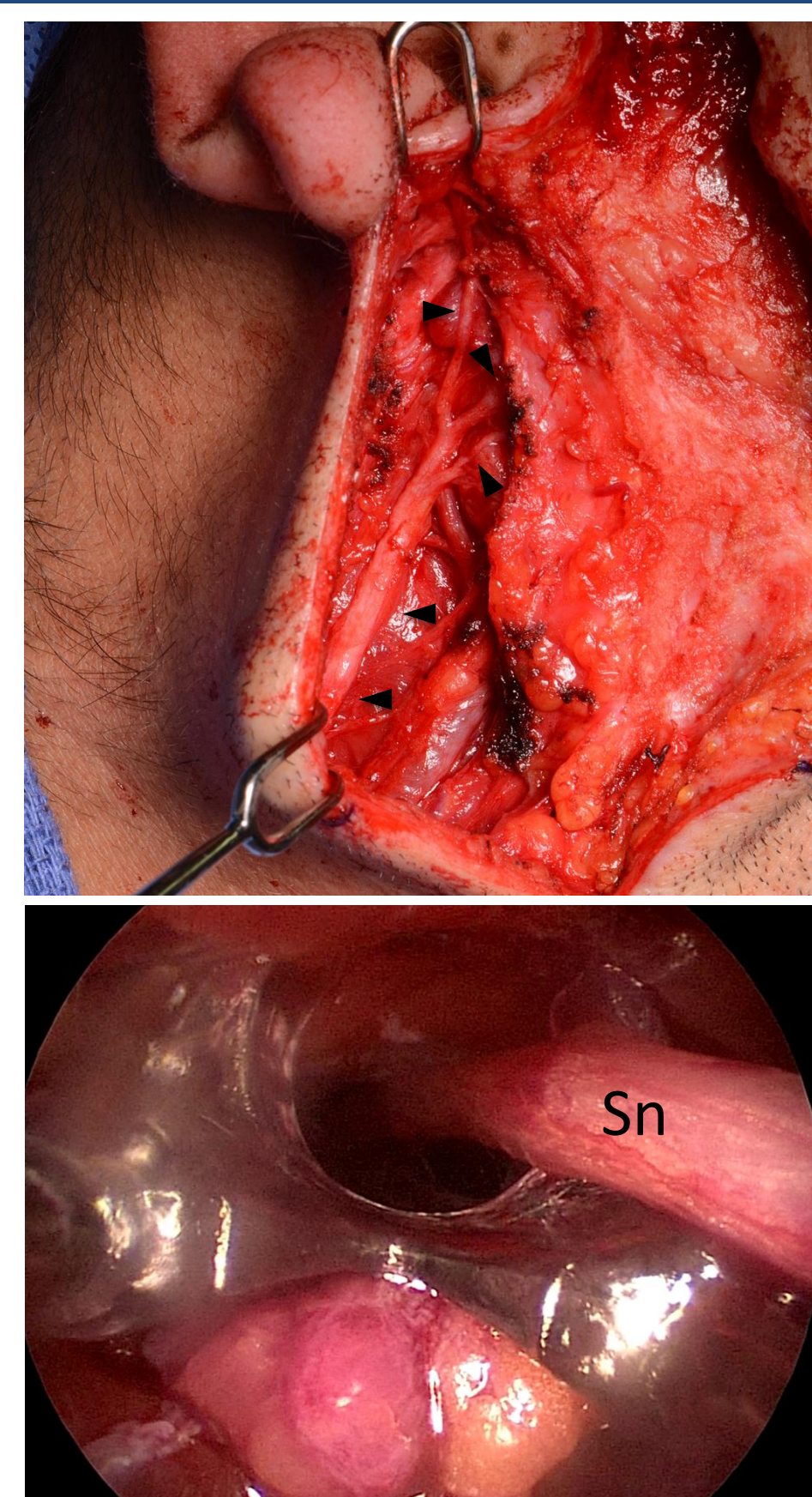
- Combined facial palsy and corneal anesthesia leads to rapid corneal blindness
- First described by Terzis et al¹ and refined by Elbaz et al², corneal neurotization by transfer of contralateral supraorbital and/or supratrochlear nerves has proven effective for management of neurotrophic keratopathy
- Here, a novel approach to corneal neurotization by ipsilateral great auricular nerve transfer and scleral tunnel incisions – as opposed to scleral sutures – is described

CASES

- Case 1: 31M presented with combined right facial and trigeminal nerve insult following vestibular schwannoma resection five years prior. He had previously undergone free gracilis transfer for smile reanimation and eyelid weighting. Pre-operative examination demonstrated complete absence of corneal sensation with inferior corneal scarring and neovascularization
- Case 2: 28M presented with combined left facial and trigeminal nerve insult following a gunshot wound to the skull five years prior. He had also previously undergone free gracilis transfer for smile reanimation and eyelid weighting. Pre-operative examination demonstrated complete absence of corneal sensation with diffuse corneal scarring and neovascularization

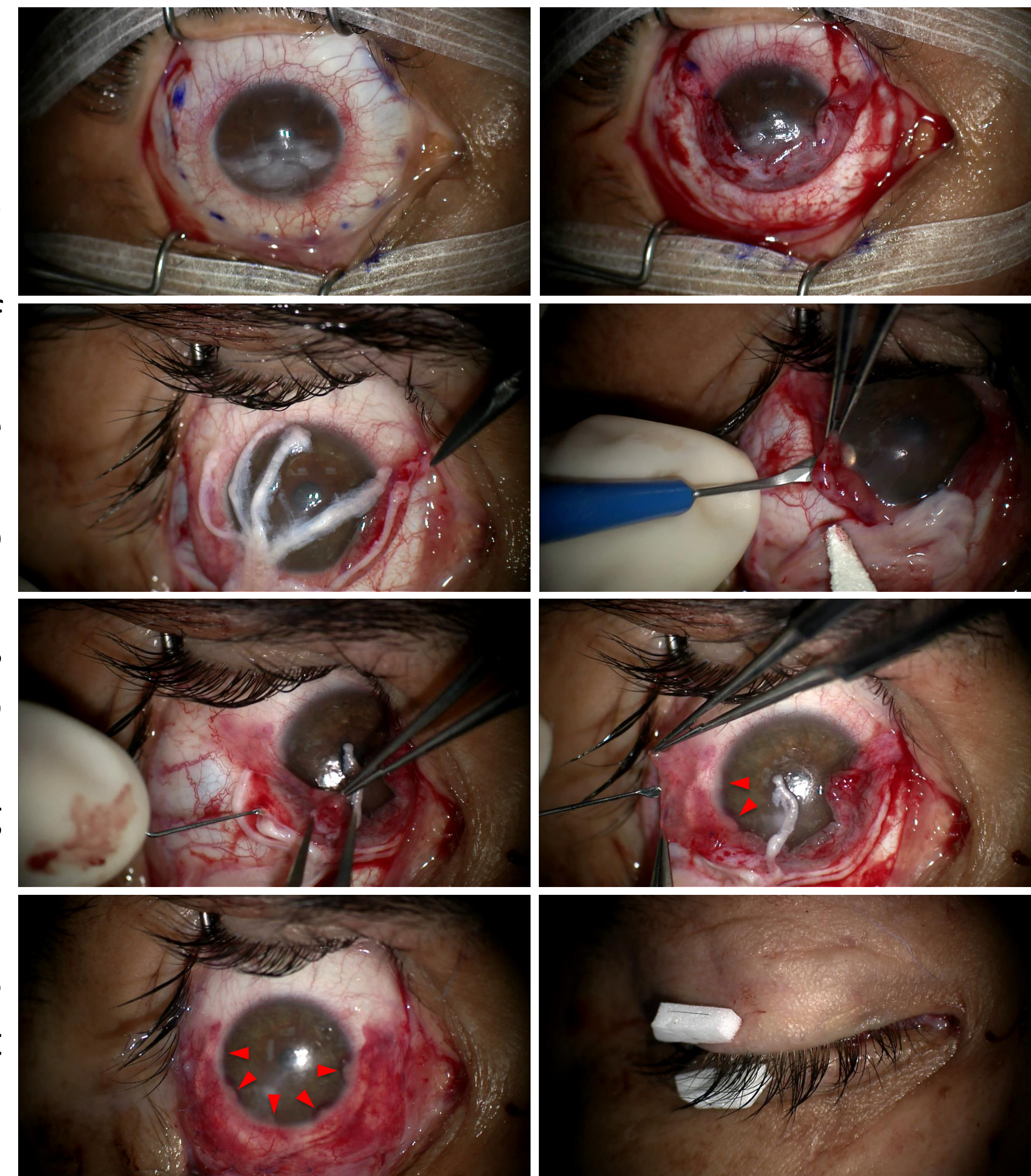SURGICAL APPROACH

- A sub-superficial musculo-aponeurotic system (SMAS) flap is elevated on the ipsilateral side
- The ipsilateral great auricular nerve, including its anterior and posterior divisions (arrowheads), is mobilized to the posterior border of the sternocleidomastoid muscle
- Nerve branches are distally transected and transposed towards the lower lid over the parotidomasseteric fascia (distance to lower lid < 6 cm)
- A sural nerve (Sn) interposition graft is harvested using an endoscopic approach
- To decrease potential axon loss along side branches, only the medial sural cutaneous component from the tibial nerve is employed



SURGICAL APPROACH

- A superiorly-based sub-conjunctival flap is elevated
- Nerve graft tunnelled through lower lid to sub-SMAS plane (not shown)
- Interfascicular dissection of the graft is performed; scleral tunnels are made into the anterior corneal stroma circumferential to the limbus for each fascicle
- Tips of individual fascicles are bluntly inserted into scleral tunnels just beyond the limbus without suturing (arrowheads)
- Conjunctival flap is closed with fibrin glue; five fascicles are visible about the limbus (arrowheads)
- Tarsorrhaphy suture placed
- Interposition graft then trimmed to length for coaptation to great auricular nerve branches atop parotidomasseteric fascia without tension using interrupted 10-0 nylon sutures and fibrin glue



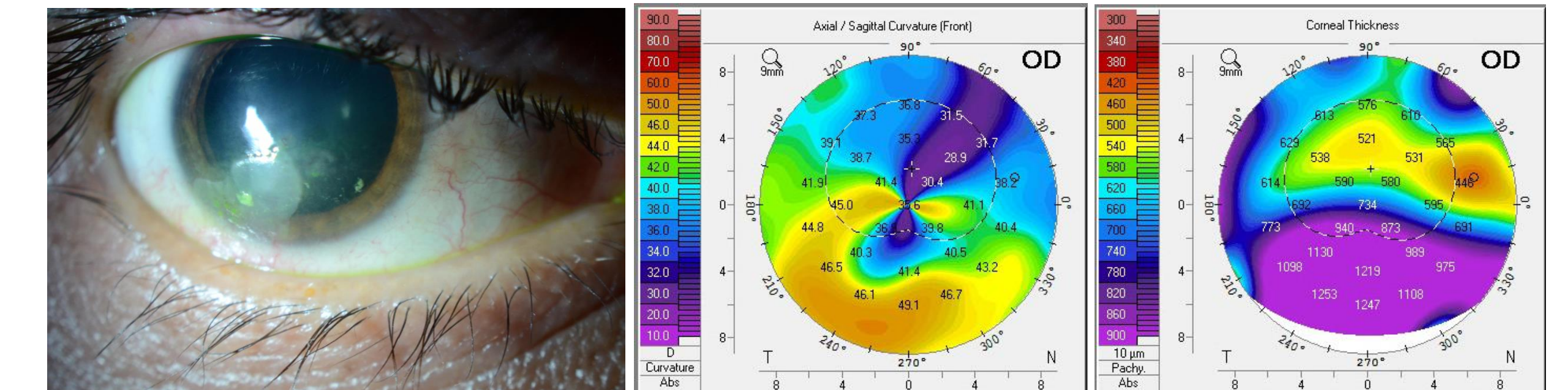
RESULTS

- There were no complications. Patients were discharged on POD #1, and tarsorrhaphy taken down at POD #14
- Case 1 reported subjective vision improvement in the affected eye eight weeks post-op, and pain sensation in ipsilateral earlobe relieved by ocular irrigation at nine weeks; ocular irrigation was perceived as cold sensation in earlobe
- Case 2 reported earlobe paresthesia with ocular irrigation beginning 11 weeks post-op
- Visual acuity in the affected eye improved from:
 - 20/125 at baseline to 20/100 at 20 weeks follow-up for case 1
 - 20/300 at baseline to 20/150 at 11 weeks follow-up for case 2

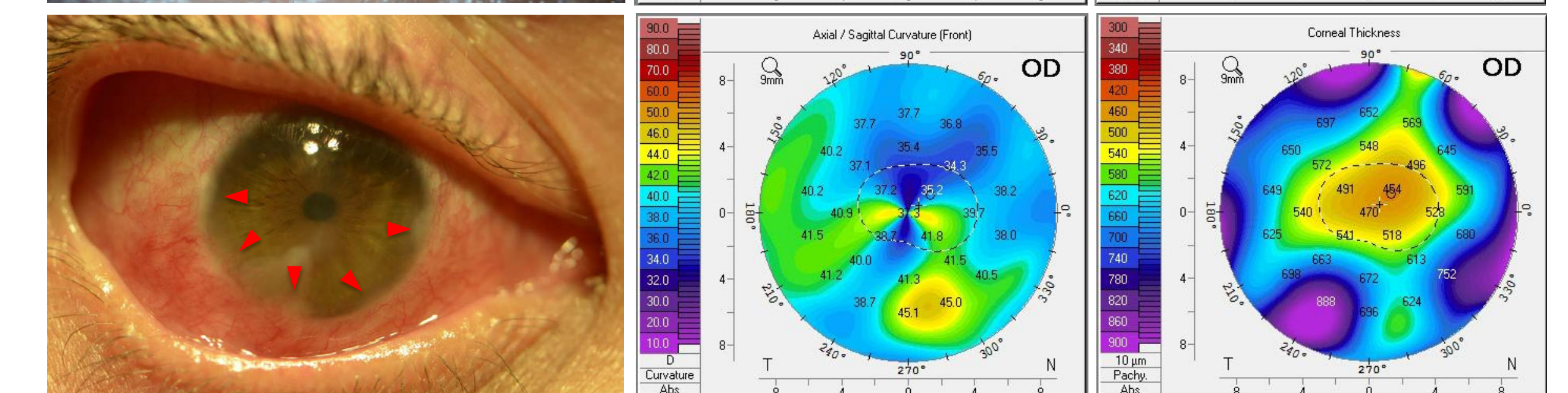
RESULTS

Corneal Imaging, Tomography, and Confocal Microscopy (Case 1)


Pre-op



Post-op
(20 weeks)



- Fascicles remained visible (arrowheads, above image) in scleral tunnels within cornea without neuromas noted at 20 weeks follow-up
- A reduction of astigmatism with improvement in inferior pachymetry was noted post-operatively (Oculus Pentacam, above image)
- In vivo corneal confocal microscopy demonstrated robust neural regeneration (white filaments, right image) within the sub-basal layer
- Imaging was not yet available for case 2



CONCLUSIONS & REFERENCES

- The great auricular nerve is an option for re-innervation of corneal sensation; benefits include minimal donor site sensory loss and ipsilateral referred sensation
- Its use should follow smile reanimation procedures in patients with facial palsy to avoid later inadvertent injury to the transferred nerve
- Placement of fascicles into the mid-stroma of the cornea via scleral tunnel incisions results in rapid and robust corneal neurotization

1. Terzis JK, Dryer MM, Bodner BI. Corneal neurotization: a novel solution to neurotrophic keratopathy. *Plast Reconstr Surg.* 2009;123(1):112-20.
2. Elbaz U, Bains R, Zuker RM, Borschel GH, Ali A. Restoration of corneal sensation with regional nerve transfers and nerve grafts: a new approach to a difficult problem. *JAMA Ophthalmol.* 2014;132(11):1289-95.