



2018 ePoster Abstracts

PN EP1 Socioeconomic Disparities in the Receipt of Brachial Plexus Surgery: A National Analysis

Alexandra Bucknor, MBBS, MRCS, MSc¹; Sabine A. Egeler, MD¹; Anmol Chattha, BA²; Samuel J. Lin, MD, MBA, FACS¹

¹*Beth Israel Deaconess Medical Center / Harvard Medical School, Boston, MA;* ²*Albany Medical College, Boston, MA*

Introduction

Previous studies have highlighted the disparities present in the provision of upper limb services within the United States. This study aims to characterize socioeconomic disparities and regional variation in an adult population with brachial plexus injuries.

Methods

Analysis of the Healthcare Cost and Utilization Project National Inpatient Sample Database (NIS) for the years 2009-2014 was undertaken. Data for adults with a primary diagnosis of brachial plexus injury with or without nerve repair during an emergency admission were retrieved using International Classification of Diseases Clinical Modification Ninth Revision codes 3530 and 9534. Patient and hospital level characteristics in addition to concomitant injuries were analyzed and the impact on receipt of brachial plexus surgery was assessed using a multivariable binary logistic regression model. The impact of surgery on discharge status (home or supported) was also assessed.

Results

Over the six-year study period, data for 5,355 cases were retrieved; of these, 494(9.2%) underwent brachial plexus surgery during their admission. Overall, a majority were white (64.8%) males (50.7%) most commonly aged 34-55 (40.1%), treated at large bed size (75.0%), non-teaching (72.0%) hospitals in the South (33.5%); 5.2% had a concomitant major orthopaedic injury. After adjustment, factors decreasing the odds of surgery were older age (35-54 years: OR 0.737, CI 0.578-0.939; 55+ years: OR 0.532, 0.376-0.754), Hispanic (OR 0.352, CI 0.205-0.604) or other non-African American racial minority (OR 0.405, CI 0.216-0.759), medium (OR 0.145, CI 0.088-0.239) or large bed size hospital (OR 0.553, CI 0.396-0.773), teaching hospital (OR 0.450, CI 0.341-0.592), and highest three income quartiles compared with the lowest ($p < 0.001$). Patients had increased odds of having surgery if they had private insurance compared with Medicare/Medicaid (OR 1.411, CI 1.084-1.838). Results are summarized in table 1. On multivariable analysis, those undergoing brachial plexus surgery were significantly less likely to require supported discharge (OR 0.515, CI 0.350-0.759).

Conclusions

Results suggest that those undergoing brachial plexus nerve repair during the acute admission are more likely to be discharged home, rather than to supported care. Despite this, there are evident socioeconomic disparities in the receipt of brachial plexus surgery, particularly affecting certain racial minorities and those with government-based insurance. This may suggest a need for a centralized referral system to help improve access to more vulnerable populations.

Table 1. Multivariable analysis: odds of undergoing brachial plexus surgery		
Outcomes	Odds ratio (95% CI)	P value
Gender		
Male	(Ref.)	
Female	1.142 (0.924-1.412)	0.219
Age		
18-34	(Ref.)	
35-54	0.737 (0.578-0.939)	0.014
55+	0.532 (0.376-0.754)	<0.001
Race		
White	(Ref.)	
African American	0.684 (0.458-1.023)	0.064
Hispanic	0.352 (0.205-0.604)	<0.001
Other	0.405 (0.216-0.759)	0.005
Missing	0.708 (0.422-1.188)	0.191
Comorbidities		
Anemia	0.300 (0.153-0.586)	<0.001
Alcohol	0.122 (0.049-0.305)	<0.001
Diabetes	0.452 (0.281-0.727)	0.001
Hypertension	0.493 (0.368-0.659)	<0.001
Obesity	1.863 (1.288-2.695)	0.001
Psychoses	0.192 (0.093-0.394)	<0.001
Hospital Bed Size		
Small	(Ref.)	
Medium	0.145 (0.088-0.239)	<0.001
Large	0.553 (0.396-0.773)	0.001
Hospital Teaching Status		
Non-teaching	(Ref.)	
Teaching	0.450 (0.341-0.592)	<0.001
Region		
Northeast	(Ref.)	
Midwest	0.739 (0.492-1.110)	0.145
South	4.983 (3.642-6.818)	<0.001
West	0.860 (0.545-1.356)	0.515
Median Household Income		
1 (lowest)	(Ref.)	
2	0.594 (0.453-0.780)	<0.001
3	0.453 (0.324-0.585)	<0.001
4 (highest)	0.354 (0.254-0.492)	<0.001
Payer		
Government	(Ref.)	
Private	1.411 (1.084-1.838)	0.011
Other	0.582 (0.410-0.827)	0.002
Orthopedic injury	0.201 (0.080-0.502)	0.001

PN EP2 Anatomy of the Mimetic Muscles and the Implications on Muscle Insetting During Facial Reanimation

Jorga Zabojava, MD, PhD¹, Philip Tolley, MS², Nikhitha Thrikutam, MS², Justin Perez, MD², Shai Rozen, MD²; Andres Rodriguez, MD, PhD²

¹*Uppsala University Hospital, Uppsala, Sweden;* ²*UT Southwestern Medical Center, Dallas, TX*

Introduction: The human smile is recognizable predominantly by a supero-lateral pull at the commissure and elevation of the upper lip, therefore accurate identification of muscle angle of pull during muscle in-setting in facial reanimation is critical to achieve a normal and symmetric smile. A number of studies have previously sought to describe the anatomical variability of the facial musculature however cannot accurately describe the line of pull and consequent motion generated by each of the mimetic muscles.

The aim of this study was to revisit and accurately measure the angular relation of the mimetic muscles providing elevation and lateral pull to the upper lip and commissure in addition to analyzing the implications of this information in muscle inseting in smile restoration.

Methods: Nineteen hemifaces from fresh cadaveric specimens were dissected. A subsmas skin flap was elevated from lateral to medial exposing the zygomaticus major (ZM), zygomaticus minor(Zm), levator labii superioris(LLS) and levator labii superioris aleque nasi (LAN). Muscle anatomy including location, length, width, angle of pull, and any anatomical variation was noted. Comparison for symmetry between sides was also performed. Data is represented as mean + standard deviation. Significance was assessed by two-tailed Student's T test and $p \leq 0.05$ was deemed to be significant

Results: All assessed specimens had ZM, LLS and LAN present bilaterally. Conversely, the Zm was only present bilaterally in 33.3% of specimens and 52% of hemifaces. We observed a single incidence of bifid ZM. There was no significant difference in muscle length or width between specimen sides.

The line of pull of the smile muscles with respect to the horizontal was assessed in each hemiface: of all the assessed muscles, the Zm had the most transverse line of pull, at $31.6 + 2$ degrees, ZM was more oblique with a line of pull of $55.5 + 1$ degrees and the LLS and LAN were oriented almost vertically with angles of $74.7 + 1$ and $78.9 + 1$ degrees respectively.

Conclusion: In our study we found 4 clear different vectors of pull with angles ranging from 30 to 79 degrees for upper lip elevation and lateral commissure excursion without significant differences between hemifaces. These findings need to be considered in orientation and inseting of the muscle flap in facial reanimation.

PN EP3 Cost-Effectiveness of Lower Extremity Nerve Decompression Surgery in the Prevention of ulcers and Amputations: a Markov Analysis

Willem D. Rinkel, MD¹; Manuel Castro Cabezas, MD, PhD²; J Henk Coert, MD, PhD^{2,3}
¹Erasmus Medical University Center, Rotterdam, Netherlands; ²Franciscus Gasthuis & Vlietland, Rotterdam, Netherlands; ³University Medical center Utrecht, Utrecht, Netherlands

Abstract

Background: The costs associated with diabetic foot disease are an increasing burden to society. In selected patients, lower extremity nerve decompression (LEND) reduces complaints of neuropathy and the concomitant risks of ulcers and lower extremity amputations. To estimate the health and economic effects of this type of surgery, cost-effectiveness of this intervention was studied.

Methods: A Markov model was developed to simulate the onset and progression of diabetic foot disease in patients with diabetes and neuropathy receiving current care, compared to a group who undergo LEND surgery. Current care was the reference comparison. Mean survival time, quality of life, foot complications and costs were the outcome measures assessed. Data from the Rotterdam Diabetic Foot Study were used on the epidemiology of diabetic foot disease, resource use and costs, complemented with information from international studies to feed the model.

Results: Compared to current care, LEND surgery resulted in improved life expectancy, gain of quality-adjusted life-years (QALYs) and reduced incidence of foot complications. The 10-year costs of management of the diabetic after decompression surgery resulted in a cost per QALY gained of EUR < 25.000.

Conclusions: Decompression surgery of lower extremity nerves improved survival, reduces diabetic foot complications, is cost-effective and even cost saving compared with standard care.

PN EP4 Enhancing Peripheral Nerve Regeneration after Neurorrhaphy: a Systematic Review of Animal Models

Matthew Wordsworth, MRCS, MA¹; Nicholas Robbins, DO²; Warren Breidenbach, MD²; Rory Rickard, FRCS, PhD³; Bijaya Parida, PhD¹; Michael R. Davis, MD, FACS¹; Andrew Hart, MD, PhD⁴; Erik K Weitzel, MD¹

¹United States Army Institute of Surgical Research, San Antonio, TX; ²59th Medical Wing, San Antonio, TX; ³Academic Department of Military Surgery and Trauma, Birmingham, United Kingdom; ⁴University of Glasgow, Glasgow, United Kingdom

Background: Primary neurorrhaphy of peripheral nerve injuries remains a significant clinical problem. Full functional recovery is usually not achieved particularly in severe or proximal nerve injuries. Attempts to enhance peripheral nerve regeneration have been widely studied in animal models but translation of this research into clinical practice has been limited.

Methods: The authors searched PubMed and Medline database for all animal studies that had primary epineural neurorrhaphy as the control group and with at least one quantitative outcome measure of nerve regeneration. The methodology, interventions and outcomes were analysed.

Results: 180 published studies were identified. The majority used the rat sciatic nerve model and a technical refinement to the standard epineural microsurgical suture repair was the most commonly studied intervention. Eight studies were in large animal models. 123 (68%) studies demonstrated at least one significant improvement to regeneration in the chosen outcome measure; only 18 (10%) demonstrated significant improvement in an electrophysiological, histomorphological and a functional outcome measure. Tacrolimus (FK506) was the single most studied drug intervention in ten studies. 41 studies measured the rat Sciatic Function Index (SFI) in the control arm of epineural repair with no intervention. The best-measured SFI recovery in these control groups across the studies varied from no improvement (SFI=-127) to near complete improvement (SFI=-14). A Pearson correlation coefficient analysis of this data demonstrated the correlation between all control outcomes of SFI in rats was weak (R=0.038).

Conclusions: The majority of studies investigating single interventions to enhance nerve regeneration report positive outcomes but with a wide variety of outcome measures. Several therapeutic options are highlighted that may be of benefit particularly if used synergistically. This review highlights recent trends in peripheral nerve research and offers insights into the strengths and weaknesses of the traditional animal models.

PN EP5 Are Current Nerve Tissue Processing Methodologies Similar Enough to Use Their Data Interchangeably? An Assessment of the Key Factors Relevant to Regeneration and Functional Outcomes Data

Erick DeVinney, MD¹; Anne Engemann, PhD²; Curt Deister, PhD²; Ivica Ducic, MD, PhD¹

¹*Washington Nerve Institute, McLean, VA*; ²*AxoGen, Alachua, FL*

In the past few decades interest in nerve allograft technology has increased greatly. Numerous institutions have developed processing and preservation methodologies in an attempt to create a nerve graft that is safe, physically stable, immunologically tolerated, structurally intact, biologically active and conveniently stored. Unfortunately, achieving this has proven challenging, with only a few reaching commercialization. Nuances in tissue sourcing, processing reagents, processing conditions, quality controls, sterilization methods and storage conditions play a role in the final functionality of each type of nerve allograft. However, general statements are often made on availability, utility and functionality of nerve allografts as a group. To better characterize the similarities and differences between preparation methods, a review of the processes, their characterization assessments and critical factors to success was conducted.

Methods:

A systematic review of MEDLINE and EMBASE databases was conducted using a comprehensive combination of keywords and a search algorithm according to PRISMA guidelines. Identified candidates were evaluated based on key criteria, categorized and compared to examine key similarities and differences.

Results:

Since 1990, 16 institutions have developed and/or patented unique nerve processing methods. Globally, 3 of these methods have been successfully developed to a clinical stage. Processing methodologies were found to vary by tissue source, processing agents, structural preservation, growth factor content, growth inhibitor content, biological activity, mechanical integrity and sterility.

The most prevalent method for reducing the immunologic burden is chemical extraction, with or without detergents. Tissue sources included rat, rabbit, porcine and human. Assessments of cellular extraction, growth factor preservation and growth inhibitor modification/removal were rarely performed, and varied greatly between processes. Preservation of basement membrane structure and laminin assessments were available for many, but not all processes. The degree of structural preservation as well as functional regeneration in both short and long gap models varied greatly by processing methodology. Improved functionality was significantly correlated with a greater degree of structural and laminin preservation as well as enzymatic removal of growth inhibitors. All processing methods demonstrated a favorable safety profile.

Conclusion.

Tissue source, processing methodologies, and both structural and bioactive laminin preservation play key roles in the utility of nerve allografts. While safety data and general utility data may be used interchangeably, functional data varied greatly between processing methods and should not be used interchangeably. Given the high degree of variability in the data examined, the tissue source and the processor and/or processing methodology used should be specified to avoid misinterpretation of relevant data.

PN EP6 Complete Recovery of an Ulnar Nerve Transection using Processed Nerve Allograft in the Setting of a Pregnant Patient: Does Prolactin Play a Roll?

Michael T. Friel, MD, FACS, FAAP¹; Joseph Ogrodnik, MD²

¹*Ochsner Hospital for Children, New Orleans, LA;* ²*University of Mississippi Medical Center, Jackson, MS*

Background: Processed nerve allografts have been shown to be safe and effective for reconstruction of peripheral nerves in the upper extremity[1][2]. To the best of our knowledge there is no published data for management of a traumatic injury to a peripheral nerve in the setting of a pregnant patient. There have been numerous reports of multiple sclerosis going into remission during pregnancy[3], suggesting a hormonal connection to nerve regeneration. This has been attributed to the hormone prolactin, which has been shown to have important neuroprotective and remyelinating properties[4].

Case Report: We present a case of a woman who sustained a deep laceration to her volar distal forearm. At the time of her injury, she was 9-weeks pregnant. She sustained complete transections of several flexor tendons, the ulnar nerve proximal to the wrist, and the ulnar artery. She underwent operative exploration under axillary nerve block. After debridement, there was a 20 mm gap in the ulnar nerve. This was repaired using a cadaveric allograft followed by a nerve wrap. The tendons were repaired in the usual fashion. She recovered uneventfully and participated well with occupational therapy. She went on to deliver a healthy baby. At 10 months post-op, she had regained S3 sensation and M4 motor function. She has recovered full use of her hand and has returned to work as a typist.

Conclusion: To our knowledge, there are no other published cases of such a remarkable recovery after complete ulnar nerve transection in the setting of pregnancy. While the effect of prolactin on the central nervous system has been studied, there are no studies showing the effect of prolactin on peripheral nerve injuries. Perhaps this could open up treatment options or adjunct therapies in the future for patients with peripheral nerve injuries. Prolactin is not without its own side-effects, and it is our hope that this case could lead to the development of animal studies to further characterize the effect of prolactin, or other maternal hormones, on the effects of peripheral nerve healing.

[1] [Microsurgery](#). 2012 Jan;32(1):1-14. doi: 10.1002/micr.20975. Epub 2011 Nov 28.

[2] [J Hand Surg Am](#). 2012 Nov;37(11):2340-9. doi: 10.1016/j.jhssa.2012.08.028.

[3] [Mult Scler](#). 2013 Jan;19(1):15-23. doi: 10.1177/1352458512458555. Epub 2012 Aug 29.

[4] [Int J Mol Sci](#). 2016 Dec 2;17(12). doi: 10.3390/ijms17122026. 2 December 2016

PN EP7 Nerve Surgeons' Assessment of the Role of Eduard Pernkopf's Atlas of Topographic and Applied Human Anatomy in Surgical Practice

Demetrius Michael Coombs, MD¹; Andrew Yee, BS²; Sabine Hildebrandt, MD³; J. Henk Coert MD, PhD⁴; Susan Mackinnon, MD²;

¹The Cleveland Clinic, Cleveland, OH; ²Washington University School of Medicine, Saint Louis, MO; ³Boston Children's Hospital, Harvard Medical School, Boston, MA ; ⁴UMC Utrecht, Utrecht, Netherlands

Introduction

Eduard Pernkopf's *Atlas of Topographic and Applied Human Anatomy* continues to be controversial due to its origination during the Third Reich, yet it has surgical application for providing intricate and detailed nerve anatomy. Initial inquiries in the 1980's resulted in the Senatorial Project of University of Vienna in 1996 and the subsequent removal of the atlas from print. However, it continues to circulate in the used book market without disclosure. The purpose of this study is to assess surgeon perception of the surgical utility for Pernkopf's atlas and obtain guidance to determine its ethical handling.

Materials & Methods

Members of the American Society for Peripheral Nerve (ASPN) and PASSIO Education were surveyed and 206 responses were collected (25.1% response rate, 76.9% completion rate). The survey introduced members to the origin of Pernkopf's atlas and asked for the surgical utility and recommendation on the ethical handling of this atlas. This involved the development of a four-point proposal to address current issues as the response from nerve surgeons in part of a multi-institutional effort for its ethical handling. This proposal includes (1) a formal disclosure, (2) consensus from the bioethical community, (3) consensus from *Bet Din* (Jewish religious rabbinical court) for preserving human life, and (4) establishing an official memorial for the victims of the atlas.

Results

Fifty-eight percent (58.7%) of respondents were aware of Pernkopf's atlas with 19.3% currently using it. Of those that were aware, 75.0% were conscious of its historical origin. Respondents identified Pernkopf's atlas as having greater anatomical detail (range 78.8-90.6%) and surgical utility (range 64.4-80.8%) when compared with Netter's anatomical atlas ($p < .003$). Following a factual explanation of the history surrounding the atlas, 66.0% felt comfortable using the atlas as reference material, 17.3% undecided, and 16.7% uncomfortable. Following the four-point proposal for the ethical handling of the atlas, 65.5% would use the atlas, 28.5% would use it regardless of the proposal, and 6.1% would not use it.

Conclusion

While a majority of nerve surgeons are aware of the historical origin of Pernkopf's atlas, there still exists a division in opinion on whether this detailed, yet controversial, atlas could be used to benefit the lives of patients.

PN EP8 Improved Recovery from a Dual Nerve and Muscle Injury with Increased Frequency of Pudendal Nerve Stimulation

Brian Michael Balog, BS^{1,3}; Dan Li Lin, MD²; Brett Hanzlicek, MS²; Margot Damaser, PhD^{1,2}
¹*Cleveland Clinic Lerner Research Institute, Cleveland, OH*; ²*Louis Stokes Veteran Service Hospital, Cleveland, OH*; ³*University of Akron, Akron, OH*

Women who leak urine due to an increase in abdominal pressure (e.g. coughing, laughing or sneezing), have stress urinary incontinence (SUI). During childbirth the pudendal nerve and external urethral sphincter (EUS) are injured causing a dual nerve & muscle injury, which results in pudendal nerve dysfunction observed 5 years after delivery and SUI. Accelerated nerve regeneration and functional recovery have been demonstrated with electrical stimulation (ES) of injured nerves. Recovery after simulated childbirth in rats is accelerated with twice weekly ES. Our hypotheses is that daily ES will improve recovery to a greater extent than less frequent stimulation.

Rats received either sham injury or pudendal nerve crush (PNC) & vaginal distention (VD) as a model of SUI. Wire electrodes were implanted in all PNC+VD animals and half the sham injured rats. One third of PNC+VD received sham stimulation (PNC+VD+SS) and all sham injury rats with electrodes received sham stimulation (SI + SS). The remaining PNC+VD rats were divided between daily ES (PNC+VD+DES) and 4 times/week ES (PNC+VD+4ES). Stimulation parameters were 20Hz, 0.1ms, 0.3mA for 1 hour under isoflurane anesthesia, while 1 hour of isoflurane with no ES was utilized for sham stimulation. Stimulation occurred for 2 weeks after the injury and 2 weeks later leak point pressure (LPP) with simultaneous EUS electromyography (EUS EMG) and pudendal nerve sensory branch potential (PNSBP) were recorded. ANOVA followed by a Student Newman-Keuls post hoc test was used to determine significant differences between groups ($p < 0.05$). Data is shown as mean \pm SEM.

LPP was significantly decreased after PNC+VD + SS (19.0 ± 2.43 cm H₂O) and PNC+VD + DES (26.5 ± 1.96 cm H₂O) compared to sham injury with no implant (SI + NI; 40.6 ± 3.45 cm H₂O) or SI + SS groups (39.9 ± 2.31 cm H₂O), but LPP was not significantly decreased after PNC+VD + 4ES (39.9 ± 3.0 cm H₂O). EUS EMG was not significantly decreased after PNC+VD + 4ES (5.8 ± 1.92 mV) compared to SI + NI (13.5 ± 3.79 mV) or SI + SS (13.7 ± 3.97 mV), but after PNC+VD + SS (1.5 ± 2.33 mV) and PNC+VD + DES (1.2 ± 0.52 mV) it was significantly decreased.

LPP and EUS EMG improved most with 4 stimulations per week, but frequency of stimulation did not influence PNSBP recovery. Daily stimulation may be too frequent and provide overstimulation and a mild re-injury.

PN EP9 The Prevalence and Practice Patterns of Anterior Interosseous Nerve to Ulnar Motor Nerve Transfer Use: a Survey of Hand Surgeons

Solomon Azouz, MD; Heather Lucas, PA-C; Raman C. Mahabir, MD, MSc; Shelley S. Noland, MD

Mayo Clinic, Phoenix, AZ

Introduction:

Nerve transfers have become increasingly popular but current adoption of new techniques and their current coding practices have yet to be studied.

Materials & Methods:

A twenty-question electronic survey of hand surgeons was performed to evaluate comfort with and coding of anterior interosseous nerve to ulnar motor nerve transfer.

Results:

Of the 461 respondents, the majority were trained in orthopedic surgery (76%) or plastic surgery (19%). There was a wide range of years in practice with 38% practicing less than 10 years, 24% practicing 11-20 years, and 36% practicing for more than 20 years. For those who completed a fellowship, 98% completed a hand surgery fellowship, 11% completed a peripheral nerve fellowship, and 7% completed a different fellowship. There was a significant difference in the use of nerve transfer depending on the type of practice ($p=.0001$) and number of years in practice ($p=.0001$), but not the volume of nerve cases per month ($p=0.3356$). The survey included a scenario of a high ulnar nerve lesion, no expectation of nerve regeneration, and plan for an end-to-end anterior interosseous nerve to ulnar motor nerve transfer. 53.7% were comfortable with the above nerve transfer, whereas 46.3% were not. Of the surgeons who were comfortable with the nerve transfer, the majority (69.5%) rated intraoperative complexity as the highest possible (5/5). When asked the Current Procedural Terminology (CPT) code they would use for the above procedure, the most common response was 64905 (first stage of nerve pedicle transfer, 45.5%) followed by 64856 (Suture of major peripheral nerve, arm or leg, except sciatic; including transposition, 31.7%).

Conclusions:

Over 46% of hand surgeons were uncomfortable performing an anterior interosseous to ulnar motor nerve transfer and the majority rated the procedure as having the highest possible intraoperative complexity. There was no consensus on CPT coding for the nerve transfer.

PN EP10 Results of a New Botox Injection Paradigm for Treatment of Migraines: Anatomical, Regional, and Targeted (ART)

Kyle Sanniec, MD; Bardia Amirlak, MD; Michael Chung, BS; Xingchen Li, BA
University of Texas Southwestern Medical Center, Dallas, TX

Introduction

Migraine headaches currently affect 37 million people. OnabotulinumtoxinA is an effective prophylactic treatment for chronic migraines, with efficacy established by the Phase III Research Evaluating Migraine Prophylaxis Therapy (PREEMPT) trials. The PREEMPT injection protocol only targets broad muscle groups, and no alternative injection technique has been studied for improvements in safety, efficacy, or efficiency. Based on recent studies and experience with nerve decompression surgery, we now know that onabotulinumtoxinA directly affects nerves. The senior author combined the knowledge of topographical nerve locations, anatomical depth, regional location of the pain, and targeted physical examination to develop the Anatomical, Regional, and Targeted (ART) injection protocol and compared this to the PREEMPT protocol for improvement in treating chronic migraines.

Methods

A retrospective review of 105 patients who underwent ART injection following failure of traditional medications, was performed. Of this group, 13 were excluded due to lack of follow-up, confounding treatments, or lack of migraine diagnosis. Headache characteristics (migraine headache index (MHI), frequency, duration, severity) were recorded before and after ART injection and evaluated.

Results

ART injection resulted in reduction of all measures ($P < 0.001$), including reductions of 15.9 headache days/month, 5.32 points on a 1-10 severity scale, and 0.68 days of headache episode duration. MHI dropped from 181.1 to 32.4 which remained stable even after 56-week follow-up (Table 1). On average, 118 units were injected, leading to complete elimination of symptoms in 44% of patients. 77% experienced $\geq 50\%$ reduction in headache days frequency, and 53% experienced $\geq 75\%$ reduction in headache days frequency.

Measure	Pre-ART	Post-ART	Reduction
Frequency (days/month)	22.7 days	6.82 days	15.9 days (95% CI: 13.8-18.0, $P < 0.001$)
Severity (1-10)	8.3	2.98	5.32 (95% CI: 4.7-5.9, $P < 0.001$)
Duration (fraction of days)	1.04 days	0.36 days	0.68 days (95% CI: 0.49-0.87, $P < 0.001$)

Migraine Headache Index (MHI)	181.1	32.4	154.42 (95% CI: 123-185, P<0.00001)
-------------------------------	-------	------	---

Table 1. Baseline, and changes in frequency, severity, duration and MHI (at 1 year).

Conclusion

The Anatomical, Regional, and Targeted onabotulinumtoxinA injection paradigm is effective in reducing frequency, duration, and severity of migraine headaches. Headache days per month was reduced by 15.9 days with an average of 118 units compared with the PREEMPT studies which demonstrated a mean reduction of only 8.4 days with 155-195 units injected. While not a side-by-side randomized prospective trial, this study suggests the more dynamic ART injection protocol may be more effective, efficient, and more tolerable than the current PREEMPT protocol.

PN EP11 Personal and Familial Cancer Histories in Patients with Malignant Peripheral Nerve Sheath Tumors

Megan C. Kaszuba, MD; Ross Puffer, MD; Robert J Spinner, MD
Mayo Clinic, Rochester, MN

Introduction

Malignant peripheral nerve sheath tumors (MPNSTs) are found at increased incidence in individuals affected by neurofibromatosis type 1 (NF1) and prior radiation therapy. Association of MPNSTs with additional cancers and genetic syndromes is not broadly described.

Methods

A retrospective search involving MPNST cases at our institution after 1994 was performed. The electronic medical record was reviewed by examining the clinical problem list and standard patient and family history form for cancer diagnoses and genetic diagnoses. We reviewed available documentation from Radiation Oncology, Medical Genetics, and Medical Oncology for adult patients or Hematology Oncology for pediatric patients.

Results

A total of 188 patients were included (Table 1). Of these, 66 patients (35%) had a personal history of additional malignancy, 148 (79%) had family history of malignancy, 73 (39%) had a genetic syndrome which was most commonly NF1, and 22 (12%) had history of local radiation. In spontaneous group patients without radiation exposure or known genetic disorder, melanoma was the most frequently reported with 7.4% incidence in the spontaneous group (Table 2).

Discussion

Though melanoma was the most common prior diagnosis in patients with spontaneous MPNST, melanoma and skin cancers are the fifth most common cancer in the United States, with an estimated incidence of 5.2%. Breast, lung, prostate, and colorectal cancers comprise the first-through fourth-most common, which is a trend similar to that in our study population (Table 3).

Conclusion

Targeted treatments are in development for NF1-affected patients, which may offer additional treatments for MPNSTs. Future research on associated malignancies and genetic syndromes may prompt changes in cancer screening recommendations after MPNST diagnosis and may broaden targeted treatment options. A possible association with increased risk of melanoma warrants further research.

Table 1: Patient and family characteristics

Total patients	188	
	n	%
Personal history of cancer	66	35%
Personal and family history of cancer	56	85%
Personal history of cancer without genetic diagnosis	48	73%
Family history of cancer	148	79%
Genetic diagnosis	73	39%
Genetic diagnosis and personal history of malignancy	16	22%
Genetic diagnosis and family history of malignancy	68	93%
Neurofibromatosis-1 diagnosis	70	96%
Personal and familial NF-1 diagnosis	32	44%
Prior radiation exposure at MPNST site	22	12%
Personal history of cancer	21	95%
Family history of cancer	17	77%
Personal history of NF1	3	14%
Spontaneous MPNST	95	51%
Personal history of cancer	28	29%
Family history of cancer	73	77%

Table 2: Number of cancer incidences in patients with spontaneous MPNSTs and a personal history of cancer

Cancer reported	n
Melanoma	7
Prostate	5
Colon	4
Lung	3
Breast	2
Neuroendocrine	2
Non-melanoma skin, basal cell, or squamous cell (each)	2
Bladder, chemodectoma, histiocytoma, tongue, thymus, pancreas, pituitary, renal cell (each)	1

Table 3: Number of cancer incidences in family members of patients with spontaneous MPNSTs

Cancer reported	n
Breast	27
Other/Unknown type	26
Prostate	22
Lung	19
Colon	17
Melanoma	9
Leukemia	5
Ovarian	4
Stomach/gastric	4
Bladder	2
Gastrointestinal	2
Mesothelioma	2
Non-melanoma skin	2
Pancreatic	2
Renal	2
Brain, cholangiocarcinoma, esophagus, liver, myeloma, nasopharyngeal, throat, thyroid, uterus (each)	1

PN EP12 Shoulder Function Reconstruction in Upper Brachial Plexus (C5-C6) Injuries by Nerve Transfers. A Technique to Improve Shoulder External Rotation

Jorge Clifton, MD¹; Eduardo Pablo Zancolli, MD²

¹Clinica Mielina Brachial Plexus, Guadalajara, Mexico; ²Fundacion Favaloro, Buenos Aires, Argentina

Background: In Upper Plexus Injuries C5-C6, restoration of elbow flexion, shoulder abduction and external is required. When proximal root stumps are not available for nerve grafting such as in avulsion injuries, or when the time from the injury won't allow a brachial plexus primary reconstruction to reinnervate motor end plates; functional loss can be re establish through nerve transfers if the timing from the injury is suitable for the procedure. Double nerve transfers have shown better outcomes restoring each shoulder function. **Purpose:** The authors describe a surgical technique through an axillary approach for the reconstruction of shoulder function in upper brachial plexus injuries, to obtain better outcomes of shoulder external rotation by selectively neurotizing the teres minor and the anterior axillary nerve branches. **Methods:** Surgical procedure was done in 10 patients with C5-C6 injuries were nerve transfers are indicated, in the context of spinal accessory nerve (SAN) to supraescapular nerve (SSN) transfer and double Oberlin procedure to restore shoulder and elbow function. An axillary approach to access the radial and axillary nerves was used. By following the long head of the triceps nerve branch distally into the arm from the axilla, a terminal nerve division was obtained before the nerve enters into the triceps muscle. This branch and its terminal divisions were used to selective neurotize the anterior branch of the axillary nerve and the nerve to the teres minor muscle. **Results:** All patients obtain a muscle grading strength of 4 or more of shoulder external rotation in adduction and 90 degrees shoulder abduction. **Conclusion:** This technique has the advantage of neurotizing the anterior motor component of the axillary nerve and teres minor without any axon loss in the sensory or articular distribution of the axillary nerve. SAN to SSN and Radial nerve branch to teres minor accomplished the concept of double nerve transfers to restore shoulder external rotation. By this means shoulder external rotation outcomes are improved either in shoulder adduction and abduction. The use of an axillary approach permits keeping the patient in a supine position during the whole procedure.

PN EP13 Timing of Nerve Recovery after Nerve Grafting in Obstetrical Brachial Plexus Palsy Patients with Isolated Upper Trunk Neuromas

Jessica A Lee, MD¹; Meg Stanger, PT²; Megan Natali, PA²; Lorelei J Grunwaldt, MD²

¹University of Pittsburgh, Pittsburgh, PA, ²Children's Hospital of Pittsburgh of UPMC, Pittsburgh, PA

Background: Traditionally, nerve recovery is quoted from adult literature at 1mm/day when educating families on postoperative recovery after nerve grafting in Obstetrical Brachial Plexus Palsy (OBPP). However, nerve recovery in infants and young children is typically faster than adults given shorter limb lengths, greater axonal regeneration, and increased cortical plasticity. One prior study reported a return to baseline function at 3-6 months postoperatively. However, there is a paucity of studies to corroborate this, and there have been no studies delineating the timeline to obtain clinically meaningful function.

Methods: A retrospective chart review was performed of all patients who underwent surgery by a single surgeon at a multidisciplinary OBPP Center. Patients with isolated upper trunk neuromas-in-continuity who underwent resection and grafting were identified. Demographics were analyzed. Time to return to baseline function was assessed by comparing Active Movement Scale (AMS) scores preoperatively and postoperatively. Time to clinically meaningful function, defined as an AMS score of ≥ 6 , was also assessed.

Results: Of 37 patients who underwent surgical intervention, 11 had isolated upper trunk neuromas-in-continuity and underwent excision and reversed sural nerve interpositional grafting. 3 of 11 patients also underwent spinal accessory to suprascapular nerve transfers. Average age at surgery was 9.8 ± 1.9 months (range 6.3-12.4 months). 1 patient did not have follow-up data and was excluded. Average follow-up was 37.1 ± 16.8 months (range 9.5-63.3 months).

Median return to baseline AMS score was 7.6 months for shoulder abduction, 6.9 months for shoulder flexion, 4.2 months for shoulder external rotation, 6.7 months for elbow flexion, and 4.1 months for forearm supination. Clinically meaningful function was obtained in 8/10 patients at a median of 11.2 months for shoulder abduction, 10/10 patients at 9.7 months for shoulder flexion, 9/10 patients at 12.0 months for shoulder external rotation, 9/10 patients at 7.5 months for elbow flexion, and 10/10 patients at 9.7 months for forearm supination. The remaining patients who did not achieve clinically meaningful function all obtained scores of 5.

Conclusions: Return of nerve function after surgical intervention in OBPP patients who undergo resection of an upper trunk neuroma-in-continuity and nerve grafting is more rapid than reported in adult literature. In our cohort, return to baseline was approximately 4-8 months, as opposed to 3-6 months as previously reported. Clinically meaningful function was obtained in almost all patients by 9-15 months. Our study provides an important datapoint on timing of nerve recovery in OBPP patients.

PN EP14 Morbidity Following a Modified Sural Nerve Harvesting Procedure in Pediatric Patients

Mark Shafarenko, Medical Student¹; Joseph Catapano, MD, PhD²; Emily S. Ho, BSc OT Reg (Ont), MEd², Gregory H. Borschel, MD, FAAP, FACS²; Ronald M. Zuker, MD, FRCSC, FACS, FAAP²

¹*University of Toronto, Toronto, ON, Canada;* ²*The Hospital for Sick Children, Toronto, ON, Canada*

Introduction: While sural nerve harvest is common for reconstruction of peripheral nerve injuries, only one study describes sensory deficits following this procedure in children. All patients in this study underwent bilateral sural harvest in the neonatal period for the reconstruction of obstetrical brachial plexus palsy. This study may not accurately describe the sensory deficits expected following unilateral harvest in older children. At our institution, we use a modified sural nerve harvest technique intended to decrease sensory morbidity by harvesting the tibial contribution to the sural nerve, while leaving the peroneal component intact. The purpose of this study is to provide the first analysis of sensory outcomes following sural nerve harvest in older children using a modified technique of unilateral sural nerve harvest.

Materials and Methods: A cross-sectional study was conducted on pediatric patients older than six years of age who had undergone unilateral sural nerve harvest. Patients were recruited during routine clinic visits at a minimum follow-up of six months. Sensory threshold testing was conducted on four standardized locations in the sural nerve distribution of both feet using Semmes Weinstein Monofilaments. Results were compared to the unoperated contralateral foot using Fisher's exact test. Patients also completed a sensory function and pain questionnaire.

Results: Sensory outcomes were evaluated for 14 patients. Mean age at operation was 10.7 ± 4.2 years with a mean follow up time of 1.84 ± 1.43 years. Sensory thresholds were restricted to the two most sensitive Semmes Weinstein monofilaments in the control group, indicating no sensory deficit. In contrast, after sural nerve harvest, 25% of all locations tested demonstrated abnormal sensation. Significant sensory deficits were found at all four locations in the sural nerve distribution ($p < 0.05$). The questionnaire revealed that only two patients expressed concerns about foot functionality, both in relation to physical activity, and no patients reported pain in their feet.

Conclusions: Unilateral sural nerve harvest using a modified procedure in older children results in measurable sensory deficits that are larger than expected based a previous study describing outcomes in neonates. This can be attributed to an older patient age and any deficits may be more appreciable in the presence of an unoperated leg for comparison. Despite differences in objective sensory testing, there remains minimal subjective functional impairment, which is in line with previous literature. This study can be used as a valuable resource to inform patients and their families of the expected outcomes of these procedures.

PN EP15 Nerve Graft Prefabrication by Lateral Axonal Sprouting Induced by Mesenchymal Stem Cells and Fat Tissue into Nerve Conduit Derived From Allogeneic Epineural Sheath

Ceyhun Cesur, MD¹; Huseyin Karagoz, MD, PhD¹; Omer Ozcan, MD¹; Mustafa Tansel Kendirli, MD¹; Zafer Kucukodaci, MD²; Ekrem Keskin, MD¹

¹University of Health Sciences, S. Abdulhamid Han Training Hospital, Istanbul, Turkey;

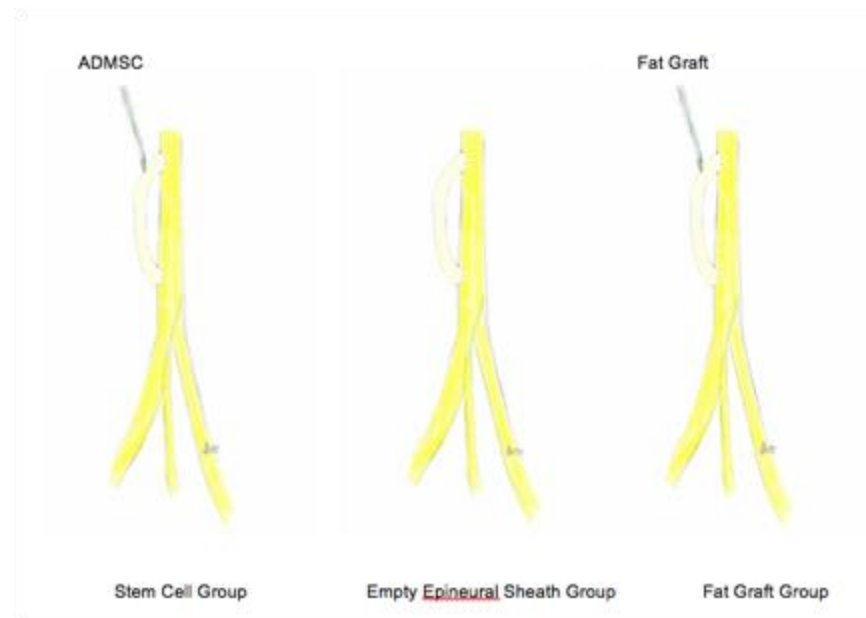²Pathology Department, Katip Celebi University, Ataturk Training Hospital, Izmir, Turkey

Background

Alternative nerve defect repair techniques to autologous nerve grafts are investigated due to donor site morbidities. In our previous studies, we successfully prefabricated nerve graft by using VEGF gene therapy, and VEGF-loaded PLGA microspheres^{1,2}. In this study, we sought to produce prefabricated nerve grafts using an epineural sheath filled with adipose tissue derived mesenchymal stem cells (ADMSC) and emulsified fat grafts. We aimed to introduce the benefits of epineural sheath on nerve healing when offering a new alternative, as a prefabricated nerve graft as effective as autogenous nerve graft but it does not cause donor site morbidity.

Methods

Epineural sheaths and adipose tissue were harvested from sciatic nerves and bilateral inguinal fat pads of 9 donor lewis rats to obtain ADMSC and fat grafts. The remaining animals were divided into three groups, each containing 6 rats. Two epineural windows on the proximal and distal site of sciatic nerve was opened in all animals, and the epineural sheaths were coated to form a parallel path (Figure 1).



ADMSC was injected into the epineural sheaths in the 1st group, and emulsified fat grafts in the 3rd group. No additional procedure was performed in the 2nd group. Following the recovery

period of 12 weeks, electromyography (EMG) and histopathological evaluations were performed.

Results

We could succeed to prefabricate nerve grafts cannot be distinguished macroscopically from a normal nerve in all groups. Statistical analysis of axon counting showed no significant difference between the groups, which demonstrated that epineural sheath can direct the nerve regeneration. Considering the mean values of axon counting, in stem cell group, axon counts were at least 1,5 times more than the other groups. In the other two groups, mean axon counts were close; however, axon progression in 3 subjects of fat graft group were interrupted due to intense scar.

Conclusion

Autologous nerve graft prefabrication can be performed with epineural sheath. Its effectiveness could be even improved with ADMSC. With its highly neurogenic and proangiogenic features and low antigenic character, epineural sheath can be used in nerve graft prefabrication in patients with nerve defects for whom elective peripheral nerve repair's planned.

References

1. Ulkur E, Karagoz H, Celikoz B, Yapar M, Arbak S. Nerve graft prefabrication: preliminary study. *J Reconstr Microsurg* 2008;24(2):137-145.
2. Karagoz H, Ulkur E, Kerimoglu O, Alarcin E, Sahin C, Akakin D, Dortunc B. [Nerve graft prefabrication using controlled release system](#). *Microsurgery*. 2012;32(8):635-641.

PN EP16 Sciatic Nerve Injury After Gunshot Wound: A Role for Fat Grafting

Prashanthi Divakar, MD; Justin T Zelones, MD; Joseph Rosen, MD

Dartmouth-Hitchcock Medical Center, Lebanon, NH

Introduction Over 180 per million people develop peripheral nerve injuries annually. Gunshot wounds (GSWs) are a particularly challenging cause due to complications, such as soft tissue loss, vascular injury, and infection. We present a case of a patient with a GSW to the left thigh resulting in a distal femur fracture that required open reduction, internal fixation, and an intramedullary rod. Post-operatively, the patient was noted to have weakness, numbness, and pain in the affected leg. Computed tomography (CT) and electromyography (EMG) demonstrated injury to the sciatic nerve with perineural bullet fragments. The patient underwent neurolysis of the sciatic nerve and fat grafting. This is the first case in the literature of fat grafting after sciatic nerve injury in conjunction with neurolysis. **Materials & Methods** A CT scan one and a half months after injury demonstrated extensive ballistic fragments throughout soft tissues in the left lower thigh and adjacent to the sciatic nerve with associated fusiform thickening (Fig. 1). EMG three months after the accident revealed greater injury to the left tibial than the left peroneal divisions of the sciatic nerve. The patient underwent neurolysis of the sciatic, tibial, and deep/superficial nerves along with removal bullet fragments from the neuroma followed by and fat grafting four and a half months after initial injury (Fig. 2). **Results** The patient was seen one and a half months after the procedure with reports of improvement in left lower leg strength and function. On exam he had a well-healed posterior thigh incision, less plantar numbness, and increased ankle dorsiflexion. **Conclusions** Autologous fat grafting in other studies has shown a regenerative effect on scar tissue, peripheral nerve activity improvement, neuropathic pain relief, and extremity mobility in the setting of painful neuromas. This is the first published peripheral nerve injury case report of autologous fat grafting for sciatic nerve injury demonstrating motor/sensory function improvement and reduced neuropathic pain. Fat grafting should be considered an adjunct to neurolysis in complex peripheral nerve injuries.

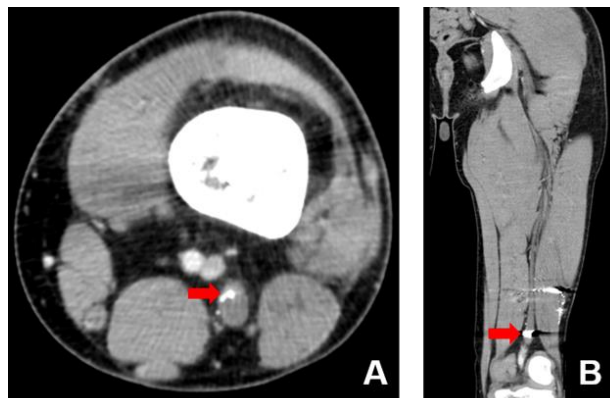


Figure 1

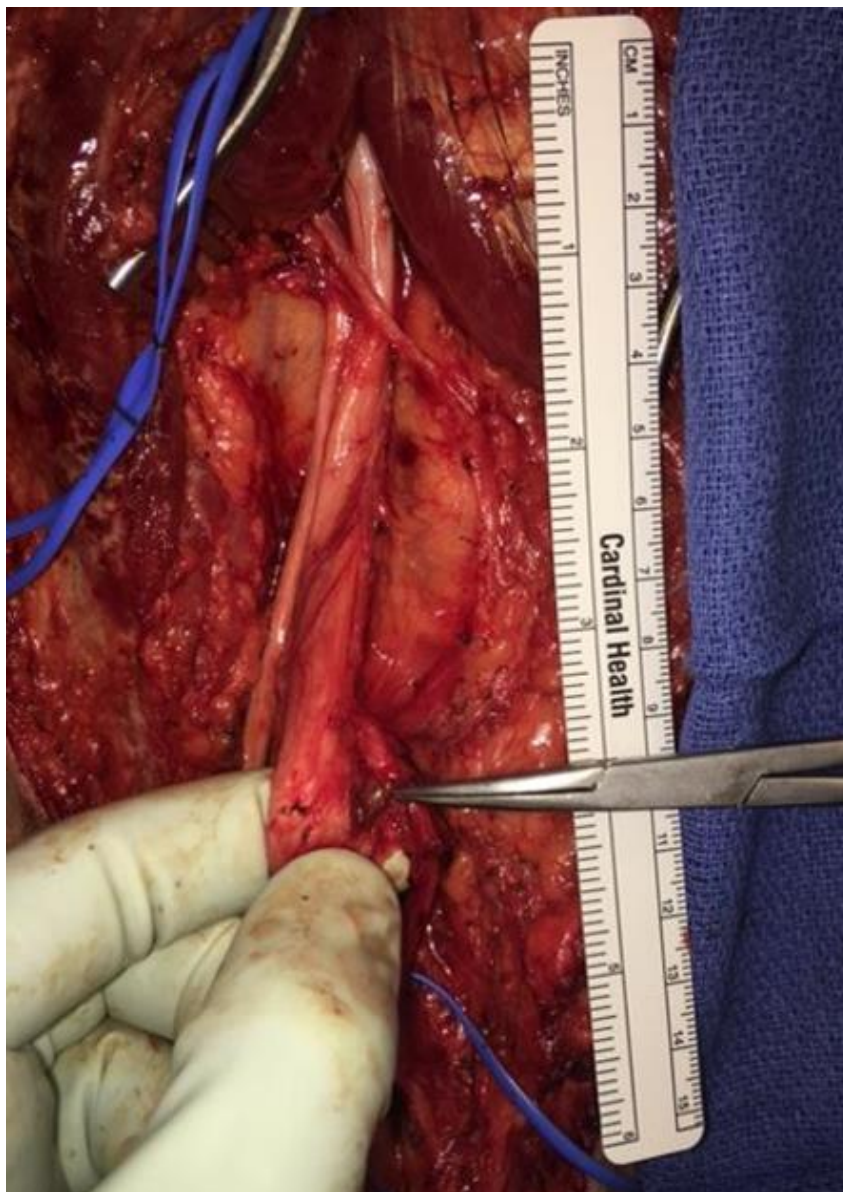


Figure 2

PN EP17 Peripheral Nerve Repair with Amnion-Muscle Combined Conduits

Stefania Raimondo, PhD¹; Andrea Marchesini, MD²; Nicola Zingaretti, MD³; Bruno Battiston, MD, PhD⁴; Stefano Geuna, MD⁵; Michele Riccio, MD²

¹University of Torino, Orbassano, Torino, Italy; ²A.O.U. Ospedali Riuniti di Ancona, Ancona, Italy; ³University of Udine, c/o Ospedale "S. Maria della Misericordia", Udine, Italy; ⁴UO di Microchirurgia Ricostruttiva, Hand Surg., Microsurg. Unit, Torino, Italy; ⁵Neuroscience Institute Cavalieri Ottolenghi (NICO), Orbassano, Torino, Italy

Introduction Peripheral nerve injury remains a significant clinical challenge in reconstructive microsurgery because it is a relatively common consequence of trauma, diseases, or tumor surgery. The amnion-muscle combined conduits allows to obtain good clinical results in peripheral nerves gap repair. It consists in the combination of the human amniotic membrane conduit filled with autologous skeletal muscle fibres harvested in the site of nerve lesion. These results seem to be due to the biological characteristics of human amniotic membrane that can be reassumed in: pluripotency of amnion-derived cells, anti-inflammatory and low immunogenic characteristics of amniotic membrane/amnion-derived cells, non-tumorigenicity and little ethical problems with usage. The purpose of this study is to evaluate the final outcome of nerve regeneration, both morphologically and functionally, across the amnion-muscle combined conduits in comparison with nerve autograft that it still is the gold standard of nerve gap reconstruction.

Materials and methods Fourteen male Wistar rats were divided into two groups: 1.5 cm length gap on median nerve reconstructed by means of i) a reverse nerve autograft; ii) amnion-muscle combined conduits. Functional results were evaluated at 30, 60 and 90 days post-operatively, performing grasping test. Morphological and stereological analysis were performed on the samples collect 90 days post-operatively using high resolution light microscopy examination and design-based stereology.

Results Our results showed that amnion-muscle combined conduits used for repairing a rat median nerve allowed nerve fibres regeneration and functional recovery. Functional recovery, evaluated using grasping test 30, 60 and 90 days after surgery, was observed in both groups, even if amnion-muscle combined conduits group showed significantly lower values that autograft group throughout the post-operative period. Moreover, the stereological analysis showed that, in amnion-muscle combined conduits group, regenerating median nerves have significantly more myelinated fibres with the same axon size, but significantly thinner myelin than autograft group. These values lead to have significantly smaller myelinated nerve fibres and a significantly higher g-ratio in the amnion-muscle combined conduits group.

Conclusions Though the autograft remains the gold standard treatment to restore wide nerve gap, the amnion-muscle combined conduit has proved to be effective in allowing nerve regeneration through a critical rat's nerve gap of 15mm, these findings support, with an experimental observation, the great clinical results obtained using AMCG conduit to restore traumatic nerve's gap wide from 3 to 6 cm of sensitive forearm nerves that we previously published² confirming the great regenerative value of amniotic membrane.

PN EP18 Descriptive Anatomy of the Brachial Plexus and Anatomical Variations by Dissection in Cadaveric Specimens.

Fentanes Vera Adriana, Fellow; Serrano Correa Luis Alberto, MD; Becerra Andrade Ricardo, MD; Alexander Cárdenas Mejía, MD

Hospital Dr. Manuel Gea Gonzalez, Mexico, Mexico

Introduction: The information we currently have about the brachial plexus comes from studies of anatomical dissection, including the normal description and its variations. **Objective:** To characterize the descriptive anatomy and anatomical variations of the brachial plexus in cadaveric patients. **Material and Methods:** Dissection of the posterior neck triangle was made in a total of 6 cadaveric specimens, a total of 10 plexus; 6 on the right side and 4 on the left side. **Results:** The plexus consisted of the roots of C5, C6, C7, C8 and T1 in all cases. The root of C5 and of T1 are smaller in diameter and C7 is the one that presents greater size. The roots C5 and C6 have a downward direction, C7 horizontal and C8 and T1 ascending. The upper trunk was formed by the union of C5 and C6, the middle trunk by C7 and the lower trunk by C8 and T1. The trunks upon entering the retroclavicular region present an anterior and posterior division, which later, upon joining, constitute the cords. The anterior division of the anterior trunk together with the anterior division of the middle trunk formed the lateral cord, this was found in 9 of 10 dissected cases, representing 90%, in the other case the anterior division of the middle trunk presented a double division, which provided a branch to conform the lateral fasciculus together with the anterior division of the upper trunk and another branch to form the medial fascicle together with the anterior division of the inferior trunk (figure). The medial fasciculus in 9 cases consisted solely of the anterior division of the inferior trunk. The posterior divisions of the three primary trunks formed the posterior fascicle. Finally, we observed the constant terminal branches in the 10 cases. **Discussion:** In neither case was a prefixed or postfixed plexus found, and a variant was found in the formation of the fascicles, noting that the middle trunk provided one branch for the formation of the medial fascicle and another branch for the lateral fasciculus, it differs from the traditional descriptions. **Conclusion:** This report is very valuable for the knowledge of the anatomy of the brachial plexus so our suggestion is to continue to perform dissections in order to compare the results with other published studies and to provide greater benefits to our patients.

PN EP19 Genital Sensibility in the Neophallus: Getting a Sense of the Current Literature

Shane D Morrison, MD¹; Rachel Bluebond-Langner, MD²; Jens U Berli, MD³; Jonathan Massie, MD⁴; A. Lee Dellon, MD, PhD⁵

¹*University of Washington, Seattle, WA*; ²*NYU Langone, New York, NY*; ³*Oregon Health and Science University, Portland, OR*; ⁴*Northwestern, Chicago, IL*; ⁵*Johns Hopkins University, Towson, MD*

Introduction

Phalloplasty surgery attempts to achieve a functional and aesthetic realistic phallus. Sensation is a key component of a functional phallus due the importance for sexual pleasure and protective function in case of implant insertion.. Little data is currently available on genital sensibility outcomes after phalloplasty, and there are no standardized approaches for assessment.

Methods

A literature search of PubMed, Google Scholar, and MEDLINE databases was conducted with medical subject heading terms related to genital sensibility after phalloplasty. Data on patient demographics, nerves used for coaptation, and measurements of genital sensibility were collected. Pooled event rates were determined for recovered glans sensibility and recovered erogenous sensation using a Freeman-Tukey Arcsine transformation.

Results

A total of 341 papers were identified of which 26 met the inclusion criteria for final analysis. The dorsal cutaneous branch of the pudendal nerve and ilioinguinal were the most common donor nerves. The lateral and medial antebrachial cutaneous and lateral femoral cutaneous were the most common recipient nerves. Pooled event rates suggest that recovered glans sensibility occurs in over 70% of cismale patients and in over 90% of transmale patients. Recovered erogenous sensation occurs in over 75% of cismale patients and over 95% of transmale patients. In cismale patients, outcomes of recovered glans sensibility and erogenous sensation may be better for upper extremity recipient nerves than lower extremity recipient nerves.

Conclusions

Based on the very limited data available in current literature on genital sensibility after phalloplasty, it is difficult to draw evidence-based conclusions. Yet data support improved outcomes with innervation during phalloplasty. Standardized collection and assessment protocols are needed

PN EP20 A New Clinical Observation Utilizing a Traditional Tendon Transfer to Improve Hand Function in Sunderland III Radial Nerve Injuries

Aaron L Morgan, MD; Lorna Kahn, PT, CHT; Susan Mackinnon, MD
Washington University School of Medicine, Saint Louis, MO


Title: A New Clinical Observation Utilizing a Traditional Tendon Transfer to Improve Hand Function in Sunderland III Injuries that Involve the Radial Nerve

Purpose: To highlight a subtle clinical exam finding in patients with a Sunderland grade III component to radial nerve injuries, where recovered digital extensors attempt to aid weak wrist extensors ultimately leading to dysfunctional grasp. To demonstrate improved functional grasp following a tendon transfer to restore grip kinematics by augmenting isolated wrist extension strength.

Methods: Two patients are described who recovered good digital metacarpophalangeal (MP) joint extensor (Extensor Digitorum Communis, EDC) with poor wrist extensor (Extensor Carpi Radialis Longus/Brevis) strength. The subsequent substitution pattern utilizing EDC (+/- thumb extensors) to stabilize the wrist during functional use had a negative impact on grip strength as simultaneous MP extension precluded MP flexion and thus grasp. Patients underwent a single wrist extension tendon transfer (pronator teres to ECRB) to augment wrist extension strength and reduce the substitution pattern. Outcome metrics include Disabilities of the Arm, Shoulder, and Hand (DASH) scores as well as pinch and grip strength.

Results: Both patients showed much-improved pinch and grip strength following their tendon transfers. The DASH score was only improved in one patient, owing to the complex plexopathy of the second patient.

Conclusions: Pronator teres to ECRB tendon transfer improves grasp in patients with EDC (digital MP extension) substitution patterns for wrist extension. Recovering plexopathies can result in subtle exam findings that require an astute clinical eye, often with the assistance of specially trained hand therapists, to prevent maladaptive substitutions from compromising functional outcomes.



PN EP21 Management of Chronic Pain Post Neurectomy: a Role for Dorsal Root Ganglion Stimulation

Line G Jacques, MD, MSc

UCSF, San Francisco, CA

Management of chronic pain post neurectomy: a role for Dorsal Root Ganglion Stimulation

Chronic neuropathic pain may be iatrogenic or post traumatic and can be a disabling and crippling in some individuals. Patients may have significant sleep disturbances, experience socio-psychological changes, along with significant physical limitations. A combination of pharmacological treatments along with physical therapy and local infiltrations may be useful. In certain cases, surgical approaches including selective neurectomy can be effective; others will remain chronic and intractable despite all interventional measures.

Neurostimulation techniques that can include: spinal cord stimulation, peripheral nerve stimulation and most recently dorsal root ganglion stimulation have shown promising results in the treatment of chronic neuropathic pain.

Method

Pre-operatively, patients were screened for suitability for dorsal root ganglion stimulation after triple neurectomy for groin pain, superficial peroneal nerve neurectomy for ankle and foot pain, saphenous neurectomy for knee pain.

Quality of life scores, VAS, and paresthesia mapping were recorded as baseline parameters as well as post operatively. Up to 4 percutaneous leads were placed epidurally at the dorsal root ganglion.

Results

Overall, pain and quality of life measures were reduced by greater than 50%.

Conclusions

Dorsal root ganglion stimulation is a viable option in the treatment of chronic neuropathic pain and should be considered as part of the pain treatment algorithm when treating this challenging patient population.

PN EP22 Anatomical Considerations for Breast Neurotization

Ivica Ducic, MD, PhD¹; Erick DeVinney, BS²

¹Washington Nerve Institute, McLean, VA; ²AxoGen Inc, Alachua, FL

Introduction: Autologous breast reconstruction following mastectomy restores the size, shape and symmetry of the breast. Over past few decades, with advancements in technical details, success and overall patient outcomes, microsurgical breast reconstruction became the standard and safe reconstructive choice to women with breast cancer. One remaining obstacle is related to breast sensitivity following autologous reconstruction, as reconstructed flap is denervated. Recent evidence based data suggest breast neurotization is justified and offers faster innervation and better quality, more-normal breast sensibility. Current literature lacks standardization of neurotization techniques, as the wide range of technical difficulties and approaches are reported.

Methods: Breast neurotization related literature and available technical approaches were reviewed. Cadaveric dissections were done to define optimal donor and recipient nerves for DIEP breast reconstruction.

Results: Current literature significantly favors the breast neurotization. Techniques reported various successes, include direct flap neurotization, conduit-assisted and autograft neurotizations. Common limitations reported include too large nerve gap to be bridged, and limited arc of rotation restricting proper aesthetic flap positioning. Evidence-based data suggest as low as 40% of nerve regeneration if defect is >1cm, posing as significant deficit to conduit neurotization, while human allograft data reported are comparable to autograft. Autograft neurotizations, in addition to limited available length, required extended abdominal wall fascia dissection, serving as an open invitation to post-operative hernias, thus both limiting autografting choices.

We performed cadaveric dissections to define ICN 11 and 12, where both donor nerves were easily and reproducibly identified as DIEP flap is harvested. Similarly, ICN 2 and 3 are expected to be routinely found along ribs inferior border, and crossing recipient vessels. After vascular anastomosis were completed, 1.5mmx70mm human allograft (*Avance*, AxoGen, FL) serving as the interposing graft between donor and recipient nerves allows tension free nerve reconstruction, eliminating gap length and arc of rotation limitations of other reported techniques.

Conclusion: Recently revisited breast neurotization is subject to a number of high quality studies, aiming to improve quality of life to post-mastectomy women with DIEP flap breast reconstruction. Although various technical suggestions are reported, we present reliable and reproducible anatomical preparation of single vs dual donor and recipient nerves. In addition, due to technological advancements, discussed applications of human nerve allograft is suggested to eliminate gap size, arch or rotation and potential hernia issues. While technical details will be shared, clinical studies are underway to objectively validate suggested technical improvements, and thereby help standardize discussed surgical advancements.

PN EP23 A Disposable Instrument to Optimize the Sharp Cut of Nerves

Antonio Merolli, MD, FBSE; Joseph Steele, PhD; Joachim Kohn, PhD, FBSE
Rutgers - The State University of New Jersey, Piscataway, NJ

Introduction. The plexiform structure and the different elastic properties of nerve components (nerve fibers; perineurium; vessels; epineurium) makes the nerve very resilient to any attempt to cut it sharply by blades or scissors. Accurate surgical technique may succeed in this task; however, we searched for a dedicated surgical instrument able to facilitate and standardize the cutting procedure. A sharp cut technique has been associated with a reduced rate of complications like neuroma and exuberant scar formation.

Materials and Methods. A probe with a double-profiled tip was designed to accommodate the nerve transverse section into a circular compartment which is open for about 1/3 of its circumference. A slit is present at right angle with this compartment and has been dimensioned to accommodate a surgical blade. The instrument has been 3D printed in several sizes. Polymeric materials have been tested for the printing procedure and our final choice was poly-Lactic Acid.

Results. The smooth tip allowed the accurate positioning of the instrument in the area where the nerve is located. Availability of different sizes allowed the precise matching of the diameter of the nerve with the circular compartment. The slit provided a path for the surgical blade to cross the nerve at right angle with the elongation of the fibers.

Conclusions. The instrument allowed a fast and accurate sharp-cut of the nerve. The manufacturing technique (3D printing) provided easily several different diameters available for surgery. The disposable character of the instrument eliminated the need for any problematic cleaning of the slit from biological materials (as it would be required for the re-use of more traditional non-disposable tools). The instrument may be useful to assist the trimming of cut-ends in gap-lesions. However, it is particularly suited for the sharp cut of an intact nerve as it is required in the harvesting of a donor autograft; in taking a whole nerve biopsy; in producing experimental gap-lesions (figure 1).

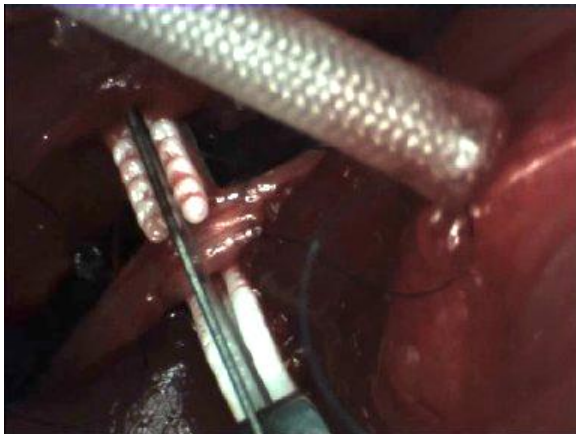


Figure 1. A blade is accommodated into the slit and a Rat sciatic nerve is placed inside the circular compartment. A braided nerve-guide can be seen, which is ready to be implanted.

PN EP24 Combined Hemihypoglossal and Masseteric Nerve Transfer for Facial Nerve Palsy

Wojciech Kukwa, MD, PhD; Ewa Migacz, MD; Antoni Krzeski, Professor
Medical University of Warsaw, Faculty of Medicine and Dentistry, Warsaw, Poland

PURPOSE OF STUDY

Various dynamic surgeries are available for facial nerve palsy. However, when used as isolated procedures, they often provide suboptimal results. Combined hemihypoglossal and masseteric nerve transfer (CHMNT) is a novel technique that may offer more optimal outcomes when compared to isolated hemihypoglossal or masseteric nerve transfer.

METHODOLOGY/DESIGN

56-year-old male with complete left facial nerve palsy following cerebellopontine angle tumor resection underwent CHMNT in 2015. The trunk of facial nerve was innervated with a split hypoglossal nerve, while the buccal branch of facial nerve was innervated by the masseteric branch of trigeminal nerve. The patient was evaluated with the House-Brackmann Classification (HBC) and Sunnybrook Facial Grading System (SFGS) pre- and postoperatively. Review of literature was performed in order to compare our results with other dynamic procedures.

RESULTS

Pre- and 18 months postoperative HBC grade was VI and III, while SFGS score was 0 and 51, respectively. Time to recovery was 11 months for facial tone and 6 months for smile. After 18 months of follow-up, smile symmetry and significant movement of oral commissure were present. No impairment of masticatory function, atrophy of tongue or speech difficulty were noticed. Results of different dynamic procedures vary in literature: from I to III for HBC and from 30 to 54 for SFGS.

CONCLUSIONS

Our new technique, which is a combination of two well-known procedures, provides optimal reinnervation of facial nerve. Hypoglossal nerve gives baseline tone to facial musculature and masseteric nerve valuable dynamic smile. The results in HBC and SFGS are similar to the other dynamic procedures, but the use of two different nerves produces less synkinesis.

American Society for Peripheral Nerve
ePosters

PN EP25 Facial Reanimation in Patients with Unilateral Facial Palsy Treated with Crossed Nervous Graft with and without Masseter Nerve Transfer Evaluated with the "eFACE" Scale.

Fentanes Vera Adriana, Fellow; Becerra Andrade Ricardo, MD; Alexander Cárdenas Mejía, MD
Hospital Dr. Manuel Gea Gonzalez, Mexico, Mexico

Introduction: "The eFACE" is a reliable, easy-to-use, objective and reproducible clinical grade electronic scale for facial function that generates a total face disfigurement score. **Objective:** The objective of this study was to determine the "eFACE" score obtained by patients with unilateral facial palsy treated with buccal - buccal branch nerve graft with and without transfer of the masseter nerve to a second buccal branch for the facial resuscitation. **Material and methods:** Complete preoperative and postoperative files and videotapes were used to evaluate patients with unilateral facial palsy who underwent facial resuscitation with crossed buccal nerve grafts of buccal branch with and without transfer of masseter nerve to a second buccal branch, In the peripheral nerve clinic and facial palsy of the plastic surgery service, between January 2010 and March 2016. **Results:** The eFACE score was determined in 20 patients with unilateral facial palsy. Sixty five percent of the patients were treated with buccal - buccal branch nerve grafts, adding a masseterine anastomosis to a second buccal branch (n = 13) and the remaining 35% were treated with a buccal - buccal branch nerve graft (n = 7). Patients had a mean age of 29.1 years and 75% of these were women (n = 15). Tumors predominated as a cause of facial palsy, 40% (n = 8), with denervation time between 6 months and 2 years, 10% (n = 50), incomplete palsy 70% (n = 14), and left hemiface affected, 65% (n = 13). All the interventions showed an increase in the postoperative evaluation score with the "the eFACE" scale; on average there was an increase of 18.85 points in the 20 patients evaluated. **Conclusion:** Being able to evaluate and describe the facial function and symmetry achieved with these surgical techniques, using the analogous visual scale, "the eFACE", will provide us with a valid support in recommending this type of interventions, improving functional and aesthetics in patients with facial palsy who are candidates for this type of treatment, significantly improving their quality of life and day-to-day functionality.

PN EP26 Complete Removal Of The Epitrochleoanconeus Muscles In Patients With Cubital Tunnel Syndrome: Results From A Small Prospective Case Series

Godard C.W. de Ruyter, MD, PhD¹; Sjoerd G van Duinen, MD, PhD²

¹*Haaglanden Medisch Centrum, The Hague, Netherlands;* ²*Leiden University Medical Center, Leiden, Netherlands*

Background

Sometimes during surgery for cubital syndrome an anomalous muscle called the anconeus epitrochlearis or epitrochleoanconeus is encountered. Different surgical strategies how to decompress the ulnar nerve in the presence of this muscle have been proposed, including transection of the muscle (myotomy), resection (myectomy), or subcutaneous transposition of the ulnar nerve. Because of the low incidence, there is no consensus on what type of surgical treatment can best be performed. In this study, we prospectively followed a small series of patients, in which the muscle was resected.

Material and methods

Five patients who presented to our clinic with cubital tunnel syndrome in the presence of an epitrochleoanconeus muscle were followed prospectively. Two patients had bilateral epitrochleoanconeus muscles, one patient had recurrent symptoms after previous myotomy. Clinical outcome after resection of the muscle was graded using the Likert scale. In addition, histopathologic analysis was performed on the resected muscles, including ATPase histochemistry.

Results

Six out of seven cases had complete relief of symptoms (Likert 1) 6 weeks after excision of the epitrochleoanconeus muscle, including the case with recurrent symptoms after previous myotomy. Histopathologic analysis of the muscles showed grouped muscle fiber atrophy and type grouping in all cases, both signs of denervation that confirm the compressive pathophysiology of cubital tunnel syndrome in these patients.

Discussion

The results of this small prospective case series show that excision of the epitrochleoanconeus muscle in patients with cubital tunnel syndrome frequently leads to complete recovery. Further support for this surgical strategy was found from histopathologic analysis of the resected muscles and the complete recovery in the case that previously underwent a myotomy procedure.

The consequence of applying the surgical strategy of complete resection of the epitrochleoanconeus muscle is that the procedure becomes more complex than in case of simple transection requiring careful preoperative work-up (with ultrasound and/or MRI) and performance of the surgery under general anesthesia.

PN EP27 Direct Ulnar Nerve Repair Versus AIN to Motor Branch of the Ulnar Nerve End to Side Transfer in High Ulnar Nerve Injuries

Gilberto Agustin Gonzalez Trevizo, MD

Texas Tech University Health Sciences Center, El Paso, TX

Introduction/Purpose: To evaluate clinical differences between standard ulnar nerve repair and standard ulnar nerve repair with AIN transfer in the setting of proximal ulnar nerve injuries.

Hypothesis: AIN to motor branch of the ulnar nerve transfer for proximal ulnar nerve injuries will lead to improved outcomes. Inclusion criteria: All patients treated at TTUHSC/UMC from 01/01/2015 to 12/31/2016 who sustained proximal ulnar nerve injuries treated with standard repair and those patients treated with standard repair and AIN to motor branch of the ulnar nerve transfer. Exclusion criteria: Patients with multiple nerve injuries in addition to ulnar nerve injury. Patients with chronic cases, >6wks, of ulnar nerve injury and late presentation. Patients with trauma requiring alteration (amputation, fusion, or tendon transfer) of any of the muscles innervated by the ulnar nerve responsible for bone and joint function distal to the site of injury.

Methods: A retrospective chart review of prospectively collected data of 30 patients in each group will be conducted, total 60 patients included. Variables to be studied include: demographics, standard surgical variables. Primary outcomes will be hand strength and function, number of patients to have recovery as well as time to recovery, and a functional outcome score. If data is unavailable through chart review patients will be contacted via telephone or a request for an office visit will be made. Results: We expect that AIN supercharge will be superior to standard repair in terms of hand function.

Discussion/Conclusion: The rate of recovery after nerve injury is 1mm per day. In proximal lesions recovery time may be prolonged. During this prolonged recovery time the muscles innervated by the damaged nerve are not receiving a stimulus to continue working and thus may atrophy or may permanently lose function. AIN supercharge is a reliable technique to sustain stimulation during nerve recovery.

PN EP28 A Mechanistic Classification for Axon Membrane fusion by Chemical Fusogens

Salma A Abdou, BA¹; Peter W Henderson, MD MBA²

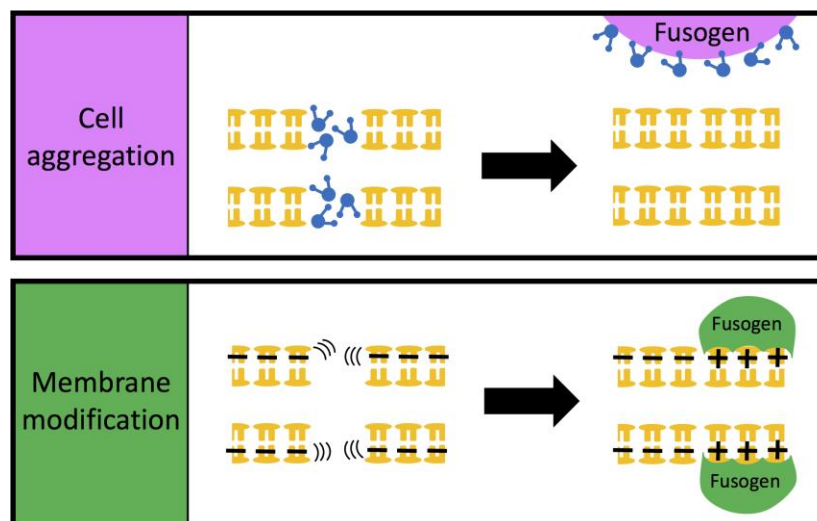
¹New York University School of Medicine, New York, NY; ²Icahn School of Medicine at Mount Sinai, New York, NY

Introduction Certain chemical agents, collectively known as fusogens, have been shown to induce membrane fusion, and this technology has recently been shown to be effective in axon membrane fusion after nerve injury when combined with epineurial repair. While the end result (phospholipid membrane fusion) is the same, each agent's structure and function is different. The goal of this project was to develop the first axon fusion mechanistic classification system for fusogens.

Materials & Methods A literature review was undertaken to identify the most commonly reported agents in the literature to achieve cell fusion in protoplast, animal, or human models. Seven such fusogens were identified: polyethylene glycol (PEG), chitosan, dextran sulfate, n-nonyl bromide, calcium, sodium nitrate and H-alpha-7. The chemical structure, mechanism, and clinical application to date for each one was analyzed and compared.

Results Adapted from an earlier description by Sowers in generalized cell fusion, fusogens can achieve axon membrane fusion by one of two general mechanisms: by bringing the two cut ends of each axon into extremely close apposition which allows the inherent fluidity of the phospholipid membrane to lead to rearrangement and ultimately fusion, or else by modifying the axon membrane surface charges in order to thereby diminish repellent forces. These mechanisms can be considered cell aggregation and membrane modification, respectively (Figure). Importantly, these two mechanisms are not mutually exclusive; in fact, the most extensively studied fusogen, PEG, is thought to function via both mechanisms.

Conclusions Fusogens can be rationally grouped into two mechanistic categories – cell aggregators and membrane modifiers. We adapted this classification system in the setting of axonal membrane fusion, and suggest that utilizing both mechanisms (either by a combination of two fusogens that function by different mechanisms, or by a single fusogen that functions by both mechanisms such as PEG) can contribute to even better outcomes in peripheral nerve repair, and warrants ongoing investigation.



PN EP29 Intra-operative Nerve Stimulation as a Novel Assessment of Rat Median Nerve Function

Matthew J Gluck, BS; Christina M Beck, PhD; Todd A Rubin, MD; Paul J Cagle, MD
Icahn School of Medicine- Mount Sinai, New York, NY

Introduction: Peripheral nerve injuries are difficult to treat and early intervention is of paramount importance. Intra-operative nerve stimulation provides a cost effective and reliable method to both localize and assess nerve function. This study aims to validate the use of nerve stimulation as a functional assessment of rat median nerve damage.

Materials and Methods: Seventeen Sprague-Dawley Rats were used in this study. Approximately 1.5cm of the median nerve was exposed and a Checkpoint surgical nerve stimulator (Checkpoint Surgical, Cleveland, Ohio) was used to assess baseline nerve function. The Checkpoint stimulator provides an adjustable current (0.5mA, 2mA, 20mA) and pulse width (50-200 μ S). Nerves were first probed at the lowest setting of stimulation, 0.5mA of current at a pulse width of 50 μ S slowly increasing first pulse width than current until the first twitch of movement (Twitch) and a full paw contraction (Contraction) could be observed. Right median nerves (HS) were then placed in a custom made stretch applicator, and a 20% stretch injury was induced and held over 5 minutes. Left median nerves (SC) were sham control, only being placed in the applicator for 5 minutes with no applied stretch.

Results: All intact values (both SC and HS) exhibited a Twitch of movement at the lowest setting of stimulation, 0.5mA of current with 50 μ S of pulse width. 14/17 specimens exhibited Contraction at 2mA with 100 μ S of pulse duration in both right and left nerves. The remaining 3 specimens exhibited intact Contraction values within the 0.5mA range. Following the application of the stretch injury, all HS nerves (17/17) required an increase in stimulation to induce both a Twitch and Contraction. All HS nerves required an increase to 2.0mA to induce a Twitch, though pulse duration varied within this range. 13/17 HS nerves exhibited an increase in pulse width to exhibit Contraction, while 4/17 HS nerves failed to exhibit Contraction in the 2.0mA range. In the sham control (SC) nerves, 14/17 required no change in stimulation to induce a Twitch. 3/17 required an increase to 100 μ S of pulse width with no increase in current. No SC nerves exhibited an increase in stimulation required for Contraction.

Conclusion: Intra-operative nerve stimulation provides an accurate baseline value to determine median nerve integrity in a rat model. Furthermore, nerve stimulation can reliably detect an acute stretch injury in rat median nerves. Intra-operative nerve stimulation is a useful tool for surgeons to localize nerves and assess their functionality.

PN EP30 Amyloid Neuropathy: Five Year Retrospective Case Review at a Tertiary Center.
Priya Devi Shanmugarajah, MBChB; Sajitha Chanaka Weerasinghe, MBBS; Agam Jung, MD
Leeds Teaching Hospitals NHS Trust, Leeds, United Kingdom

Introduction Amyloidosis is a rare life-threatening multisystem disorder characterised by tissue deposition of insoluble fibril proteins with an incidence of 47:100000 in Europe. We describe two distinct cases of amyloid neuropathy from a five year retrospective case review.

Materials & Methods Thirty-two sural nerve biopsies were performed from 2011 to 2016 on patients with peripheral neuropathy and we describe two cases with biopsy proven amyloidosis.

Case 1 65-year-old man with lambda monoclonal gammopathy of undetermined significance (MGUS) presented with progressive sensory loss and lower limb weakness. He had multiple falls, urinary and faecal incontinence. Examination revealed postural hypotension, impaired pain sensation up to his knees, absent ankle jerks and bilateral foot drop.

Case 2 67-year-old man with bilateral carpal tunnel syndrome presented with weight loss, dysphagia, constipation, bilateral foot drop and numbness up to his waist. He constantly feels cold even in warm weather. There was no family history. Examination revealed postural hypotension, weak distal more than proximal lower limb muscle with symmetrical loss of pain sensation and globally attenuated reflexes.

Results In both cases, neurophysiology showed axonal sensory-motor polyneuropathy and sural nerve biopsy confirmed amyloid deposit on Congo red stain. SAP-scintigraphy revealed amyloid deposit in spleen and kidneys in case 1. He was diagnosed with systemic light-chain (AL) amyloidosis using immunofixation electrophoresis. He declined cyclophosphamide and stem cell transplant and was symptomatically managed. Case 2 had significant cardiac involvement of amyloidosis. Genetic testing confirmed transthyretin-T60A-variant mutation confirming Transthyretin (TTR)-related amyloidosis (ATTR). Symptom onset to diagnosis was five years for case 1 and eight years for case 2. Both patients died within ten years of symptom onset with multi-organ failure.

Conclusion Case 1 describes acquired primary AL amyloidosis caused by accumulation of immunoglobulin light chains in the setting of plasma cell dyscrasia in MGUS. Case 2 depicts autosomal dominant hereditary familial amyloid polyneuropathy (FAP). Met30TTR mutation is the most common of the 100 point mutations identified, with 52-77% of cases being sporadic. National Amyloidosis Centre reports cardiac involvement in nearly 100% of T60A-FAP patients with neuropathy. A study in a Mayo Clinic demonstrated a median time to diagnosis of 24 months (IQR, 3-384 months). Prompt treatment aims to delay disease progression by preventing amyloidogenesis. Chemotherapy and hematopoietic cell transplantation for AL amyloidosis and liver transplant for Met30TTR-FAP. High index of suspicion of amyloidosis is crucial when peripheral neuropathy and autonomic dysfunction is encountered, for early diagnosis and pertinent treatment.

PN EP31 A Rare Cause of Unilateral Hypoglossal Nerve Palsy: Intraneural Ganglion Cyst of the Hypoglossal Nerve.

Jeremie Oliver, BS, BA; Vijay Agarwal, MD; Robert Spinner, MD; Jamie Van Gompel, MD
Mayo Clinic, Rochester, MN

Introduction: Ganglion cysts causing hypoglossal compression are significantly rare. They are typically found in peripheral nerves near tendon sheaths, often near the carpal tunnel, or in the lower limb region near the fibular head. Cranial nerves are rarely affected by intraneural ganglion cysts. These cysts can become clinically remarkable by causing compression of the adjacent nerve fascicles, resulting in pain, paresthesia, weakness, muscle denervation, and atrophy. Significant clinical findings to be expected from an intraneural ganglion cyst of the hypoglossal nerve include unilateral tongue deviation and atrophy on the affected side, as well as potentially slurred speech. Symptoms of hypoglossal nerve ganglion cysts can also include relevant structures affected in glossopharyngeal nerve or spinal accessory nerve palsies, as these cranial nerves travel alongside the hypoglossal nerve and could potentially become impinged as a result of the ganglion cyst arising on the adjacent hypoglossal nerve. The present literature suggests this to be a significantly rare finding affecting the hypoglossal nerve, with only three previously documented cases being reported.

Materials and Methods: Patient medical record data collection. Review of literature performed using an electronic search using Ovid Medline and PubMed in April 2017 without timeframe limitations. Only English-language citations were considered. The following were used as either keywords or Medical Subject Headings (MeSH) in all combinations in the search strategy: “hypoglossal cyst”, “hypoglossal tumor”, “intraneural ganglion cyst”. The compiled reference lists were compared and reviewed for potential relevance and assessed using the inclusion and exclusion criteria.

Discussion: We report, to our knowledge, the fourth documented case of a patient with a hypoglossal cystic tumor. Our aim in this report is to compare our findings with previous reported cases of unilateral hypoglossal nerve palsy, and to highlight the importance of an intraneural ganglion cyst, and the differential diagnosis of such.

PN EP32 High Resolution Ultrasound (HRUS) as a Diagnostic and Planning Tool in Surgical Management of Rare Chronic Neurogenous Pain Syndromes

Veith Moser, MD

Trauma Hospital, Vienna, Austria

High resolution ultrasound (HRUS) as a diagnostic and planning tool in surgical management of rare chronic neurogenous pain syndromes

Introduction: Chronic pain syndromes due to nerve injury, neuroma, compression or scar-related nerve traction may occur all over the body. Surgical methods, e.g. reconstruction, neuroma resection and relocation, decompression or neurolysis are often helpful, yet treatment may be missed or fail due to lack of adequate diagnostic imaging.

Objective: This paper demonstrates the use of high-resolution nerve ultrasound imaging combined with diagnostic nerve blocks to diagnose rare nerve-related pain syndromes and shows up, how helpful this high resolution ultrasound is in diagnosing and planning the operative treatment.

Sonography with a 23 MHz head was utilized.

Results: Clinical case reports include US findings with correlating surgical findings on patients with damage to peripheral nerves are shown.

Conclusions: HRUS is a readily available, inexpensive, quick and highly versatile tool to diagnose rare causes of nerve pain. It allows an precise visualization, localization, investigation with test blocks and ink or wire marking of nerve branches with a minimal diameter of about 1 mm. Therefore, HRUS offers many significant advantages for the treating surgeon or interventional radiologist caring for neurogenous pain syndromes.

PN EP33 Nerve Recovery on Volar Forearm Lacerations from Single Major Nerve Injury vs. Double Major Nerve Injury

Gilberto Agustin Gonzalez Trevizo, MD

Texas Tech University Health Sciences Center, El Paso, TX

Introduction/Purpose: To evaluate clinical differences between Nerve Recovery on Volar Forearm Lacerations from single major Nerve Injury vs. double major Nerve Injury

Hypothesis: Is Nerve Recovery on Volar Forearm Lacerations from single major Nerve Injury faster than when double major Nerve Injury is present

Inclusion criteria: All patients treated at TTUHSC/UMC from 01/01/2015 to 12/31/2016 who sustained complex Volar forearm lacerations, more often known as “Spaghetti Wrist”, including structures like Tendons, Arteries and single major nerve vs double major nerve repair (ulnar or median nerve involvement vs. ulnar and median nerve involvement)

Exclusion criteria: Patients that when nerve repair was performed it required more than a tension free cooptation like a cable graft.

Methods: A retrospective chart review of prospectively collected data of 20 patients in each group will be conducted, total 40 patients included. Variables to be studied include: demographics and standard surgical variables. Primary outcomes will be hand strength and function, number of patients to have recovery as well as time to recovery, and a functional outcome score. If data is unavailable through chart review patients will be contacted via telephone or a request for an office visit will be made.

Results: We expect that patients with one major nerve injury recover faster than when there are two major nerves injured

Discussion/Conclusion: The rate of recovery after nerve injury is 1mm per day. In proximal lesions recovery time may be prolonged. During this prolonged recovery time the muscles innervated by the damaged nerve are not receiving a stimulus to continue working and thus may atrophy or may permanently lose function. Brain plasticity plays an important role when recovering from a nerve transection that requires surgical repair, also the antagonism on the different rehab protocols influences on the patient final outcome.

PN EP34 Cost-effectiveness of Diagnostic Ultrasound in Focal Neuropathies

Arvin Raj Wali, BA¹; Charlie Park, BS¹; Dina Hingorani, PhD¹; Milli Desai, BS¹; Justin M. Brown, MD¹; Michael Cartwright, MD²; Ross Mandeville, MD¹

¹*University of California, San Diego, San Diego, CA*, ²*Wakeforest, Salem, NJ*

Introduction

Recently, a prospective trial (Cartwright et al., 2015) evaluating the use of ultrasound in addition to electrophysiology for the assessment of focal neuropathy detected improvement in the SF-36 when ultrasound was used. The original study randomized 120 patients with focal neuropathies to either have their ultrasound reports sent or not sent to their management teams. Previously, we extracted SF-6D scores, a preference-based health related quality of life (HR-QOL) index, from the original SF-36 scores and found a significant ($p < 0.012$) and clinically meaningful improvement in SF-6D score between baseline and 6-month follow-up when ultrasound was used but not when only electrophysiology was relied upon ($p < 0.689$). Using this information, this study goes further and evaluates the cost-effectiveness of diagnostic ultrasound in focal neuropathy.

Methods

Using TreeAge Pro, a Markov model was constructed to assess the cost-effectiveness of ultrasound for a 54 year old patient seeking treatment for focal neuropathy. Cost of ultrasound was derived from Medicare CPT codes and quality adjusted life years (QALYs) were derived from the SF-6D scores reported by Cartwright et al. All dollars were reported in \$2016 values. A willingness to pay threshold of \$50,000/QALY gained was used to assess cost-efficacy.

Results

Ultrasound was highly inexpensive associated with a one-time cost of \$36. However, across a lifetime, patients that underwent ultrasound had a 0.5 lifetime gain in QALY compared to patients that did not have ultrasound performed. Our model demonstrated an incremental cost-effectiveness ratio of \$72/QALY gained indicating that ultrasound used in the diagnosis and treatment of focal neuropathy is an extremely cost-effective modality.

Conclusion

In addition to prior evidence that diagnostic ultrasound is valid, reliable, and accurate in the diagnosis of focal neuropathy, this study goes further and finds that the use of diagnostic ultrasound is highly cost-effective and should be considered in the evaluation and management of focal neuropathies.

PN EP35 Breast Reinnervation following Mastectomy: Demonstration of Proof of Principle

Gloria R Sue, MD; Dung H Nguyen, MD, PharmD

Stanford University, Stanford, CA

Introduction

Preservation of nipple and mastectomy skin sensation following mastectomy is associated with improved patient quality of life. We propose that the intercostal nerves to the breast can be used as a donor nerve for neurotization of the nipple, mastectomy skin, and/or of a reconstructed flap to the breast.

Materials and Methods

Patients undergoing mastectomy who desired nipple or skin reinnervation were included in this study. The donor nerves used for neurotization were the medial or lateral 3-5th intercostal nerves. The donor nerves were dissected out to length and neurorrhaphy was performed to the base of the nipple, mastectomy skin, or the reconstructed flap to the breast. Sensation was assessed post-operatively using Semmes-Weinstein monofilament testing.

Results

A total of 5 patients underwent mastectomy and subsequent reinnervation. Three patients underwent mastectomy for gender dysphoria and the neurotization of the base of the nipple. One patient underwent mastectomy with autologous reconstruction and neurotization of the flap, with the abdominal intercostal nerve as the recipient nerve. One patient underwent mastectomy with implant-based reconstruction and neurotization of the overlying mastectomy skin. Patients were followed up out to 6 months post-operatively and were all noted to have progressive improvement of sensation from baseline immediately following surgery.

Conclusions

Breast reinnervation provides a significant increase in sensory recovery for patients undergoing mastectomy. This may in turn lead to an increase in quality of life. Challenges in breast reinnervation include a potentially tedious dissection and a limited length of the donor nerve which may preclude reinnervation in patients undergoing immediate reconstruction following mastectomy. Future studies include assessment of nerve grafts or scaffolds in facilitating reinnervation of post-mastectomy breasts.

PN EP36 Analyzing Cost-Effectiveness of Oberlin Nerve Transfer to Regain Forearm Flexion

Arvin Raj Wali, BA; Charlie C Park, BS; Justin M. Brown, MD; Ross Mandeville, MD
University of California, San Diego, San Diego, CA

Object:

Peripheral nerve transfers to regain elbow flexion via the ulnar and median nerve or variations of the “Oberlin nerve transfer” are surgical options that benefit patients. Prior studies have assessed the comparative effectiveness of the ulnar and median nerve transfers for upper trunk brachial plexus injury; yet no study has examined the cost-effectiveness of this surgery to improve quality of age-adjusted life years (QALY). We present a cost-effectiveness model of the Oberlin nerve transfer to restore elbow flexion for an adult population with upper brachial plexus injury.

Methods:

Using a Markov model, we simulated ulnar and median nerve transfer and conservative measures in terms of neurologic recovery and improvements in quality of life (QOL) for patients with upper brachial plexus injury. Transition probabilities were collected from prior studies assessing the surgical efficacy of ulnar and median nerve transfers, complication rates associated with comparable surgical interventions, and the natural history of conservative measures. Incremental cost-effectiveness ratios (ICER), defined as cost in dollars per QALY, were calculated. Incremental cost-effectiveness ratios less than \$50,000/QALY were considered cost-effective. One-way and two-way sensitivity analyses were utilized to assess parameter uncertainty. Probabilistic sampling was utilized to assess ranges of outcomes across 100,000 trials.

Results:

Our base-case model demonstrated that Oberlin nerve transfer, with an estimated cost of \$5066.19, improved effectiveness by 0.79 QALY over a lifetime compared with conservative management. Without modeling the indirect cost due to loss of income over lifetime associated with elbow function loss, surgical treatment strategy had an ICER of \$6,453.41/QALY gained. Factoring in the loss of income as indirect cost, surgical treatment had an ICER of -\$96,755.42/QALY gained, demonstrating an overall lifetime cost saving due to increased probability of returning to work. One-way sensitivity analysis demonstrated that the model was most sensitive to assumptions about cost of surgery, probability of good surgical outcome, and spontaneous recovery of neurologic function with conservative treatment. Two-way sensitivity analysis demonstrated that surgical intervention was cost-effective with an ICER of \$18,828.06/QALY even with our most conservative parameters with surgical costs at \$50,000 and probability of success of 50% when considering the potential income recovered through returning to work. Probabilistic sampling demonstrated that surgical intervention was cost-effective in 76% of cases at a willingness to pay threshold of \$50,000/QALY gained.

Conclusion:

Our model demonstrates that Oberlin nerve transfer for upper brachial plexus injury improves QALY in a cost-effective manner.

PN EP37 An Optimized Animal Model to Promote Nerve Repair Utilizing Endogenous Autonomic Nervous Discharge

Jing Rui, MD, PhD; Jie Lao, MD, PhD

Huashan Hospital, Shanghai, China

Background: Peripheral nerve degeneration is a complex clinical issue making regeneration of peripheral nerves challenging. Exogenous electrical stimulation has been previously demonstrated to effectively improve axon growth. We hypothesized that endogenous autonomic nervous discharge of the phrenic intercostal nerves may promote nerve regeneration.

Methods: Action potential discharge patterns were examined in diaphragm, external intercostal and latissimus dorsi muscles in rats. Musculocutaneous nerve regeneration recovery was examined after injury by side-to-side transfer of either phrenic, intercostal or thoracic dorsal nerves, with nerve autograft to the anastomosis site.

Results: We found that the phrenic and intercostal nerves showed rhythmic clusters of discharge, consistent with breathing frequency. From the first to the third intercostal nerves, spontaneous discharge amplitude gradually increased. Phrenic and intercostal nerves correlated with receptor nerve at the early stage, a negative correlation in the middle stage and no difference at the later stage.

Conclusion: Our results suggest that the rhythmic clusters of discharge in the phrenic and intercostal nerves showed significant correlation with nerve regeneration at the early stage, which may provide the potential target for nerve regeneration in future preclinical investigations.

PN EP38 The Effectiveness of Splinting for Sleep Disturbance in Carpal Tunnel Syndrome

Guy Rubin, MD; Hagay Orbach, MD; Micha Rinott, MD; Nimrod Rozen, MD, PhD

Emek Medical Center, Afula, Israel

Objectives

A controlled prospective objective and subjective study which evaluated the effectiveness of night splinting compared to non-splinting and surgery for insomnia severity in patients with carpal tunnel syndrome (CTS).

Patients and Methods

Sleep characteristics were monitored for several days without a brace, with a brace and after surgery. The sleep measurements included actigraph worn on the wrist during night, a "sleep log" that conveyed subjective impressions as to how they had slept and a short insomnia instrument, the Insomnia Severity Index (ISI).

Results

The ISI scores demonstrated that a night splint improved significantly insomnia symptoms compared to no splinting, but surgery significantly improved insomnia symptoms compared to splinting. The "sleep log" scores demonstrated that the differences between the sleep log quality and the number of waking's without a splint were significant compared to the scores with the splint and to the scores after surgery. The "sleep log" scores did not demonstrate a significant difference in quality or number of waking's between splint and surgery. The actigraph failed to demonstrate significant differences between each of the treatment methods.

Conclusions

Night splinting reduce the number of wakings and improves sleep quality when measured using ISI score and a "sleep log".

PN EP39 Epigenetic Regulation of Neural Development and its Use in Peripheral Nerve Regeneration

Leon J Nesti, MD, PhD¹; Christopher Daniels, MD²; Youngmi Ji, PhD¹; Stephen Fericola, MD²; Edmund C Nesti, PhD³

¹Uniformed Services University, Bethesda, MD, ²Walter Reed, Bethesda, MD, ³Alcamena Stem Cell Therapeutics, Spencerville, MD

BACKGROUND: Improving peripheral nerve regeneration and functional recovery after peripheral nerve injury remains a challenging clinical problem. We have previously found trauma-induced mesenchymal progenitor cells (MPCs) at these injury sites, and demonstrated their ability to secrete neurotrophic factors.

The repressor element-1 silencing transcription factor (REST) acts as a master regulator of neurogenesis by repressing terminal neuronal differentiation. Previous reports have found that REST was decreased following central nervous system insult, but the role that REST plays in peripheral nerve injury and the associated pathways are not well described.

C-terminal domain small phosphatase-1 (CTDSP-1) phosphorylates and stabilizes REST at a specific regulatory site. Using a novel peptidomimetic decoy to bind CTDSP-1 at this binding site limits its phosphorylation ability. Without the CTDSP-1 blockade on REST, neurogenic gene expression and increased neurotrophic factor expression can facilitate neuron axonal growth after nerve injury. It is not known if this peptidomimetic is able to access CTDSP-1 at its site of action, the nucleus.

HYPOTHESIS: We believe that the CTDSP-1 binding peptidomimetic will accumulate in the nucleus and modulate neurotrophic factor expression.

METHODS: MPCs were seeded onto coverslips on a 24-well plate. The next day, the cells were treated with the CTDSP-1-binding peptidomimetic, containing a FLAG-tag. Cells were harvested at 1 day after treatment, and fixed for immunocytochemistry with FLAG antibody for the peptidomimetic and Hoechst 33342 for the nucleus. Secondary antibodies 488 anti-mouse (as FLAG antibody) and 594 phalloidin (for cell morphology) were used for fluorescent visualization. Images were taken using confocal laser scanning microscopy. REST expression after peptide treatment was analyzed by Western blot, using a wild-type / mutant construct.

RESULTS: The fluorescent tag for the CTDSP-1-binding peptidomimetic was collocated with fluorescent stain that binds DNA. That is, the peptidomimetic gained access to the nucleus in trauma-induced mesenchymal progenitor cells. In Figure 1, panel B demonstrates the FLAG antibody, associated with the peptide. Panel C shows the Hoechst staining of the nucleus, and panel D demonstrates the colocalization. Western blot analysis demonstrated decreased fluctuation of REST expression after peptide treatment in the mutant-REST cells compared to a 7.8% decrease seen for the wild-type.

SUMMARY:

- REST is a regulator of neural differentiation, and it is controlled by CTDSP-1.
- The peptidomimetic, with affinity for CTDSP-1, can translocate to the nucleus, which strengthens the feasibility of modulating the epigenetic control of REST.

PN EP40 WITHDRAWN

PN EP41 Early Neurotization of the Zygomatic Muscles in the Möebius Syndrome Using Sural Nerve Grafts and End-To-Side Neurorrhaphies

Fausto Viterbo, PhD; Alan Fagotti Moreira, MD

Unesp, Botucatu, Brazil

Introduction All the treatments currently described for Möebius syndrome treatment includes temporal muscle flap or free muscles flaps. The Möebius Syndrome is characterized by the absence of almost all of the facial nerve branches and facial muscles are preserved at birth. As time passes, the muscles becomes hypotrophied or atrophied due to denervation. Thinking about preserving the main smile muscle, the zygomatic major, we introduced the early neurotization of these muscles, using nerve grafts and end-to-side- coaptations.

Materials & Methods Between April of 2014 and May of 2017, eight patients with Möebius syndrome were operated. The age of four patients was two and four three years old at the surgery, four boys and four girls. The facial palsy was bilateral in six and unilateral in two cases.

All patients were submitted to neurotization of the major zygomatic muscle by introducing two sural nerve grafts into each muscle. The nerve graft extremity was submitted to some small cuts with microsissors in his lateral aspects in the portion that was introduced inside the muscles to increase the number of axons sproutings. The donor nerve was the masseter in all cases except one that was the marginal mandibular branch. The union of the nerve grafts to the donor nerves was end-to-side coaptation. No removal of the epineurium and perineurium was done. No sutures were used in the donor nerves to prevent any harming from the needle due the small diameter of them. The extremity of the nerve graft was fixed to the donor using the embracing sutures in two cases. In the other six cases were used two simple stiches taking the epineurium and perineurium of the nerve grafts to the underlying tissue, in both sides of the donor nerve. Both kinds of sutures determine pressure of the nerve graft against the donor nerve.

Results

Two patients after three years presented no result.

One unilateral patient after one year presented full result.

One bilateral patient after two years presented good result.

The other four patients were operated less than 18 months and are still in observation.

Conclusions

The new procedure of early zygomatic muscle neurotization should be considered to Moebius and congenital facial palsy.

PN EP42 Intraoral Approach for Facial Reanimation

Sinikka Suominen, MD, PhD; Tuija Ylä-Kotola, MD, PhD

Helsinki University Hospital, Helsinki, Finland

Background: If the facial muscles can be reinnervated in time before atrophy and permanent damage, the patients may regain some if not all of their facial movements. The problem with cross-face grafting is time, it often takes the nerve too long to grow to reach the affected site, and babysitter procedures have been proposed. Inspired by Dr Koshimas experience, we started to use an intraoral approach to cross face grafting to shorten the distance between the donor and recipient nerves to have a more rapid recovery.

Methods: In our series of 7 patients, 4 had sural nerve grafting from a buccal branch to a buccal branch, 3 had the same using a vascularized nerve graft from the anterior thigh and 4 of the 7 had a combination of both end-to side masseter nerve transposition and buccal-to buccal grafting. No facial wounds are created, only intraoral in the sulcus on both sides.

Results: Sural grafting alone produced less or no results, and the combined approach was the most effective, EMNG at 1 years revealed a working connection to the healthy facial nerve providing natural facial movements.

Conclusions: A complete facial palsy is a surgical challenge. If the facial muscles can be reinnervated the result is three dimensional and superior to free muscle transfer. This new approach seems to shorten the recovery time with no facial scars.

PN EP43 WITHDRAWN

PN EP44 The Relationship between Electrodiagnostic Findings and Sleep Disturbance in Carpal Tunnel Syndrome

Guy Rubin, MD; Hagay Orbach, MD; Micha Rinott, MD; Nimrod Rozen, MD, PhD
Emek Medical Center, Afula, Israel

Abstract

Introduction

A controlled objective and subjective study which evaluated the correlation between insomnia severity and electrodiagnostic measures in patients with carpal tunnel syndrome (CTS).

Methods

Sleep characteristics were monitored objectively throughout 4-9 nights by means of an actigraph. The following morning, participants filled out a “sleep log” that conveyed their subjective impressions as to how they had slept. All patients also completed a short insomnia instrument, the Insomnia Severity Index (ISI). These findings were correlated to the patients’ motor latency and sensory latency.

Results

The ISI demonstrated that most of the patients had trouble with fragmentary sleep but had no problem with falling asleep or early waking. Most of the patients mentioned interference with daily functioning. We found no correlation between sensory or motor latency and all sleep measures.

Conclusions

Electrodiagnostic findings and patient CTS sleep severity appear to be independent measures.

PN EP45 Limb Length Discrepancy in Surgically Treated Obstetric Brachial Plexus

Mohamed Mostafa Kotb, MD

Assiut University Hospital, Assiut, Egypt

Introduction and aim of work; The purpose of this investigation was to determine limb length discrepancy between affected and unaffected upper extremities in patients with obstetric brachial plexus palsy (OBPP).

Patients and methods; Fifty patients with OBPP underwent measurements of the bilateral upper extremities. Mean age at surgery was 12.6 months (4-84months). Active motion was assessed using the Toronto Test Score.

Results; The total limb length averaged 93.3% of the normal side; the humeral length averaged 94.96%, while the forearm length averaged 91.76%.

Conclusion; No statistically significant correlation between age and limb length discrepancy was noted. Furthermore, there were no correlations between upper limb discrepancies and measures of active motion, type of lesion and surgical procedure in individual patients

PN EP46 Saved by Martin-Gruber: Anastomosis Restores Full Function after Complete Ulnar Nerve Injury

Madhawi Mitwalli, MD¹; Arvin Raj Wali, BA²; Justin Brown, MD²; Ross Mandeville, MD²

¹*University of Alabama at Birmingham, Birmingham, AL*, ²*University of California, San Diego, La Jolla, CA*

Introduction:

Communication can occur between median and ulnar nerves resulting in distal muscles receiving mixed innervation comprising some axons that left the brachial plexus via the median nerve and some via the ulnar nerve. This anastomosis most frequently occurs in the forearm, approximately 20% of the population, receiving the eponym Martin-Gruber anastomosis (MGA). Axons destined for the ordinarily ulnar-innervated thenar, hypothenar, and dorsal interosseous muscles are involved, travelling most of their course in the median nerve instead. The most common muscle to receive anastomotic fibers is the first dorsal interosseous (FDI), and of the numerous variations of MGA, the most common originate from the anterior interosseous nerve to communicate with the ulnar nerve in the forearm.

Case Report:

A 36-year-old male sustained a gunshot to his left arm. The entry point was the medial arm, exiting posterior medial, 2 inches proximal to the medial epicondyle. Initial trauma exam not only demonstrated no ulnar-innervated activation, but also significant weakness in median-innervated muscles including MRC 3 flexor pollicis longus, MRC 4 flexor digitorum superficialis and wrist flexion, and no thenar muscle activation. Sensation was reduced predominantly in an ulnar distribution. Six months post-injury, exam showed MRC 4 in all ulnar-innervated muscles and full strength elsewhere. Electromyography at that time showed borderline compound motor action potential amplitudes in the adductor digiti minimi and FDI, with their entire innervation coming from an MGA. Nine months' post-injury, he had essentially full strength in all hand and forearm muscles with no wasting. Decreased sensation remained in the ulnar distribution, about 20% of his unaffected contralateral hand. There was a positive Tinel's sign along the ulnar nerve in the proximal forearm.

Discussion:

In this interesting and fortunate patient, the MGA acted as a natural median to ulnar nerve transfer, and enough anastomotic axons were present to restore completely normal strength and function after collateral reinnervation, and without need for functional rehabilitation as no axons were repurposed. Further points of interest include: if ulnar grafting were pursued, the fate of regrown native ulnar axons on finding their muscle fibers occupied by collateral sprouts is unclear but could be evaluated through motor unit number estimate or size index quantitative neurophysiologic techniques. These techniques could also be used to inform on the critical number of anastomotic axons required to restore adequate function and thereby the possibility for early intervention and improved outcomes.

PN EP47 Progressive Weakness due to an Anterior Arachnoid Cyst: An Indication for Nerve Transfer Surgery

Madhawi Mitwalli, MD¹; Arvin Raj Wali, BA²; Justin Brown, MD²; Ross Mandeville, MD²

¹*University of Alabama at Birmingham, Birmingham, AL*, ²*University of California, San Diego, La Jolla, CA*

Introduction:

Anterior Arachnoid Cyst is an uncommon cause of spinal cord compression that may result in severe disability. Most are located in the thoracic region, followed by lumbar then cervical regions. Clinical presentations are varied but predominantly include neck pain, variable degrees of weakness, and paresthesias. Laminectomy followed by cyst excision and cystoperitoneal or cystopleural shunting are accepted interventions aimed at cord decompression. Neurological recovery after surgery depends on duration and severity of compression. The presentation can be a major challenge for the neurologist and neurosurgeon, especially when imaging does not clearly delineate the cyst.

Case report:

A 31-year-old female presented with 10 years of progressive left hand and 1 year of progressive right arm weakness. Exam revealed atrophy and near complete weakness in the left hand intrinsic muscles (MRC 1), as well as significant right shoulder abduction, external rotation, and elbow flexion weakness (MRC 3). There was mild weakness in the right elbow extension, supination and pronation (MRC 4). No upper motor neuron, bowel/bladder, cerebellar, or sensory abnormalities were detected. Electromyography suggested severe chronic left C8-T1, and moderate-severe right C5-6, myotomal involvement with ongoing denervation in C5-6 myotomes. There were mild-moderate stable chronic neurogenic changes in the right C7-8 myotomes. MRI C-spine without contrast (pregnant) was repeatedly read as normal. However, given confidence in clinical localization, repeat imaging and reads revealed subtle enhancement within the cord, mild atrophy, and subtle signal abnormality anterior to the cervical and thoracic cord. Laminectomy and cysto-peritoneal shunt placement was successfully undertaken.

Discussion:

Initial differential included a neurodegenerative disorder or Hirayama disease until later imaging detected the likely culprit. This case emphasizes the limits of imaging and importance of clinical localization in determining how far to pursue workup. Given relative preservation of right median nerve axons and presumption of no further progression, a nerve transfer utilizing a single median nerve fascicle to biceps is planned to augment elbow flexion strength, which was predominantly lost over the last year and thus likely receptive to reinnervation. This would be the first case we know of where nerve transfer is applied to restore function lost from spinal cord compression by arachnoid cyst. Nerve transfer is becoming a lead surgical intervention to restore function in patients with weakness from numerous central and peripheral etiologies but awareness remains low; delay can result in missing the window of opportunity and poor outcomes.

PN EP48 Plexiform Neurofibroma as a Cause of Carpal Tunnel Syndrome in a Radial Deficiency Patient

Kejia HU, MD¹; Ziv Williams, MD²; Wendong Xu, MD, PhD³

¹*Huashan Hospital, Shanghai, China;* ²*MGH, Boston, MA;* ³*Fudan University, Shanghai, China*

A 31-year-old female presented with a 5-year history of an enlarged mass in her right wrist with predominant nocturnal numbness in the right hand, including the palmar surface of the thumb, second, third, and lateral half of the fourth finger and over the thenar eminence. She also had a history of type IV deficiency of the thumb, suggesting a floating thumb. Physical examination revealed diffuse swelling of the wrist with positive Tinel's sign over the median nerve and a negative Phalen's test. X-rays revealed a right first metacarpus deficiency. MRI scans showed a nodule following the median nerve trajectory that was isointense to the muscle on T1-weighted images and hyperintense on T2-weighted images. Electrodiagnostic tests confirmed an impairment of the sensory conduction velocity of the median nerve of the wrist. Intra-operatively, the right flexor carpi radialis and palmaris longus tendons were absent. The median nerve had expanded spindle-shaped (2 cm [length] × 1 cm [width] × 1 cm [depth]) at the carpal tunnel, with transverse carpal ligament thickening. The nerve tracts were stiff, thickened, and circuitous. We released the compression with an incision in the distal part of the transverse carpal ligament and performed interfascicular neurolysis. The floating thumb was also removed, as the patient's request. The pathologic diagnosis was plexiform neurofibroma. At one-year follow-up there was no evidence of local recurrence. Our case sheds light on anatomy and possible etiological association which may help clinical management.

PN EP49 Sutureless Approach Using Vein Grafts In Peripheral Nerve Repair: Functional and Immunohistological Results

Ali Eren, MD¹; Sacit Turanlı, MD¹; Cemile Merve Seymen, PhD¹; Ferda Alpaslan Pınarlı, MD, PhD²; Gülnur Take Kaplanoğlu, PhD¹

¹*Gazi University, Ankara, Turkey,* ²*Dıskapı Yıldırım Beyazıt Research Hospital, Ankara, Turkey*

Purpose: The aim of this study was to define a sutureless peripheral nerve repair technique using a vein graft and compare it to epineural repair. The vein grafts were also used as a reservoir for bone marrow-derived stem cells (BMSC) and stem cell effects on primary nerve repair were investigated.

Methods: Thirty Wistar Albino rats were randomly divided into five groups. The sciatic nerve was transected. In the first group (K), epineural repair was performed. In the second group (SV), epineural repair was wrapped with a vein graft. In the third group (MSV), epineural repair was wrapped with a vein graft and BMSCs were injected into the vein. In the fourth group (V), sutureless repair using vein graft was performed. (Fig 1) In the fifth group (MV), sutureless repair using vein graft was performed and BMSCs were injected. Functional recovery was evaluated with pinprick, toe spread tests and sciatic nerve index (SFI). Nerve regeneration was also assessed by gastrocnemius index and immunohistochemical analysis.

Results: There was no difference in pinprick and toe spread tests between the groups. SFI revealed no difference at 4th and 8th weeks, however, at the 12th week, all other groups showed better improvement compared to epineural repair where the MSV revealed the best ($p < 0.05$). (K: -76.5 ± 3.7 , SV: -65.2 ± 11.7 , MSV: -46.2 ± 19.4 , V: -68.8 ± 9.8 , MV: -56 ± 8.8) (Fig 2) There was no difference in gastrocnemius index between the groups. Better immunoreaction in GAP-43 and NF-H staining, which were the indicators of nerve regeneration, was observed in MSV, MV, SV, V groups respectively, that MSV showed the best ($p < 0.05$). (Fig 3) SV and MSV groups showed less fibrosis area (K: 221.5 ± 25.9 , SV: 101.6 ± 7.1 , MSV: 121.3 ± 18.8 , V: 150.3 ± 12.1 , MV: $152.4 \pm 11.8 \mu\text{m}^2$, $p < 0.05$) and MSV group had better alignment compared to other groups.

Conclusions: Although sutureless repair with a vein graft reveals better functional results compared to epineural repair, epineural suture repair before vein wrapping improves the functional and immunohistochemical results and decreases fibrosis. BMSCs also improves regeneration in primary peripheral nerve repair.

Key words: Sutureless nerve repair, peripheral nerve injury, vein graft, mesenchymal stem cell



Figure 1: Sutureless repair technique with vein graft. Sutures (Black arrows) have been taken away from the regeneration site.

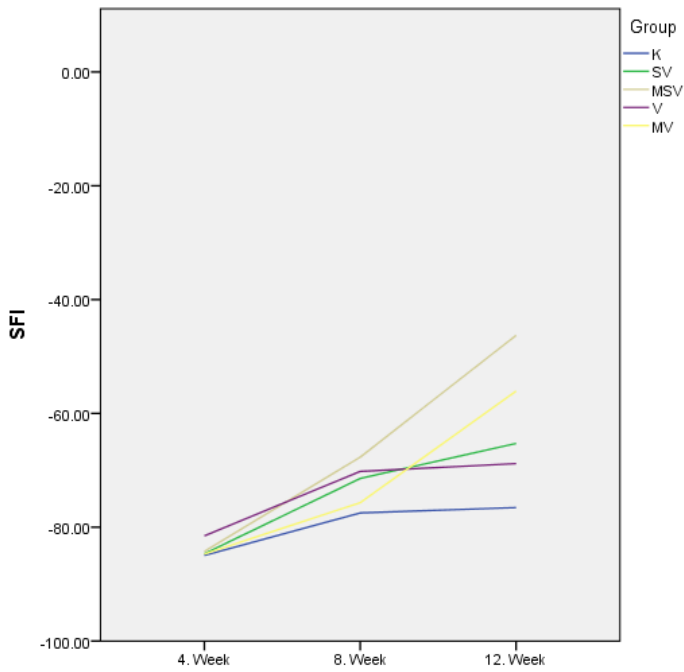


Figure 2: Sciatic functional index (SFI) results of the groups

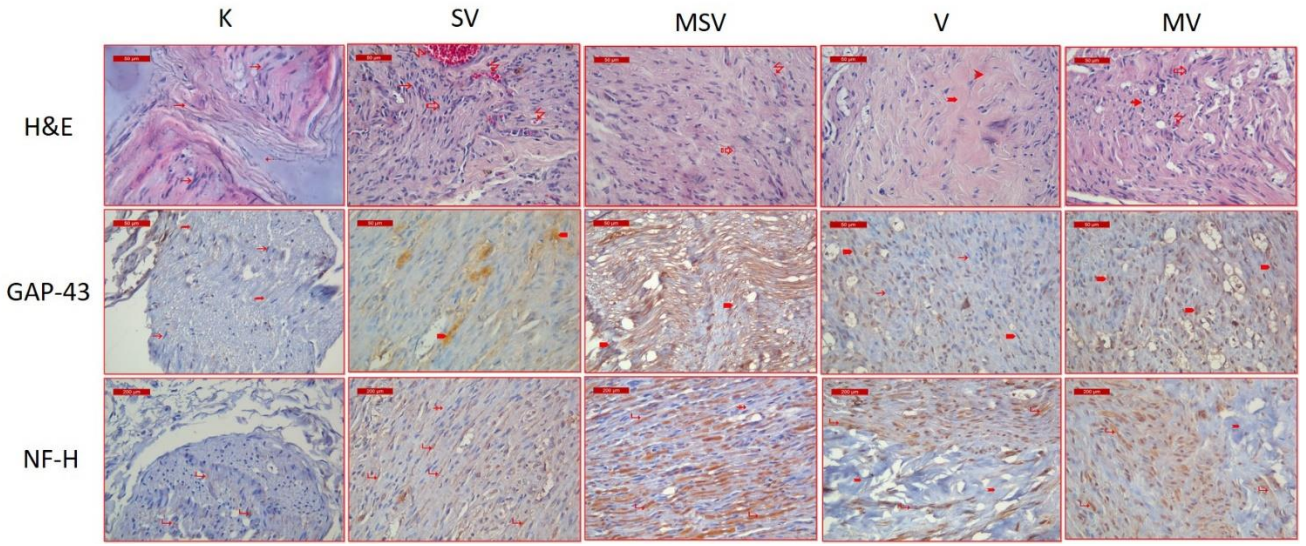


Figure 3: Hematoxylin&eosin (H&E), GAP-43, NF-H staining results of the groups.

PN EP50 A High-Throughput Mouse Platform for Nerve Conduit Assessment

Suresh Mohan, MD¹; Wenjin Wang MD, PhD¹; Ivan Coto Hernández, PhD¹; Kaiyang Yin, MS²; Cathryn Sundback, ScD¹; Ulrike G.K. Wegst, PhD²; Nate Jowett, MD¹

¹*Harvard Medical School, Boston, MA, USA*; ²*Dartmouth College, Hanover, NH, USA*

INTRODUCTION

Conventional histologic processing of nerve in rat models is resource intensive. Herein, we describe use of transgenic reporter mice combined with modern microscopy techniques for high-throughput assessment of neural regeneration across bioengineered conduits.

METHODS

A rapid, non-toxic, and stain-free frozen section protocol suitable for assessment of neural regeneration by widefield and confocal laser scanning fluorescent microscopy was employed. Interposition repair of a sciatic nerve defect in Thy1.2 YFP-16 mice was performed using various types of bioengineered neural conduits, and regeneration assessed at six weeks.

RESULTS

Axon counts were achieved within hours of sample harvest. Confocal fluorescent microscopy images revealed excellent morphology of regenerating axons, with rapid visualization of permissive versus repulsive conduit environments.

CONCLUSIONS

A rapid and cost-efficient platform for neural regeneration assessment suitable for high-volume testing of various neural conduit designs has been described.

PN EP51 Corneal Neurotization by Ipsilateral Great Auricular Nerve Transfer and Circumferential Corneal Scleral Tunnel Incisions for Neurotrophic Keratopathy

Nate Jowett, MD; Roberto Pineda II, MD

Harvard Medical School, Boston, MA

INTRODUCTION

Combined ipsilateral facial palsy and corneal anesthesia may lead to rapid corneal blindness. Corneal neurotization by transfer of contralateral supraorbital or supratrochlear nerves has proven effective for management of neurotrophic keratopathy. Herein, a novel approach to corneal neurotization by ipsilateral great auricular nerve transfer is described with initial clinical outcomes.

METHODS

The degree of mobilization of great auricular nerve branches towards the inferior eyelid was assessed in cadavers. Two patients with combined unilateral Vth and VIIth cranial nerve deficits underwent ipsilateral great auricular nerve transfer to the insensate cornea using a sural nerve interposition graft. Fascicles were positioned within the peripheral cornea using circumferential corneal scleral tunnel incisions. Outcomes comprised visual acuity, corneal sensation and synesthesia, donor deficit, and degree of neurotization as assessed by corneal confocal microscopy.

RESULTS

At three months, improvements in visual acuity were noted, together with referred cold sensation with eye drop use and referred foreign body sensation that resolved with corneal irrigation. Donor deficit comprised loss of earlobe sensation alone. Confocal microscopy indicated improved corneal nerve density.

CONCLUSIONS

The ipsilateral great auricular nerve is a suitable option for corneal neurotization. Circumferential corneal scleral tunnel incisions permit for rapid neurotization of the neurotrophic cornea.

PN EP52 Dually Innervated Free Gracilis Transfer in Smile Reanimation

Joseph R Dusseldorp MS, MBBS, FRACS^{1,2}; Nate Jowett, MD¹; Tessa A Hadlock, MD¹
¹Harvard Medical School, Boston, USA; ²Royal Australasian College of Surgeons and
University of Sydney, Sydney, Australia

Background

When two populations of motor axons are directed at a recovering muscle this technique is known as “supercharging”. There are relatively few clinical studies that have assessed the outcomes of this technique or determined the relative inputs of each donor nerve. In facial palsy, selection of donor nerves to re-innervate the free gracilis muscle transfer remains controversial. The cross facial nerve graft (CFNG) provides an ideal source of motor axons from the healthy contralateral side but can lead to unfavourable outcomes especially in older patients. The nerve to masseter (NTM) has several advantages, providing a strong source of axons without the need for an interposition graft. Its downsides are that the patient must learn to smile by activating their masseter muscle and it does not activate spontaneously in the majority of cases. An option is to utilize both the CFNG and NTM in a dually innervated fashion. The purpose of this study was to determine the effectiveness of the dual innervation technique using novel computer vision outcome assessment tool.

Methods

Patients undergoing free gracilis transfer by dual innervation were identified and demographic, operative, and outcomes data was collected prospectively. Standardised clinical photography and videography was reviewed as well as clinician-graded and patient related outcome scales (eFACE and FaCE instrument). Spontaneous smile was assessed using validated humorous videos. Synchronicity was assessed using blinded facial movement detection of healthy side and affected side by two independent observers. A novel computer vision algorithm was employed to detect expression of joy during both voluntary and spontaneous smiling. Comparisons were made between NTM, CFNG and dually innervated gracilis cases.

Results

Dually innervated free gracilis transfer was performed in 26 patients between 2004 and 2016. Mean time of follow-up was 12 months. eFACE and FaCE scale improvements were statistically significant. Results of both voluntary and spontaneous expression of joy in CFNG, NTM and dually innervated gracilis flaps will be presented.

Discussion

Harnessing two sources of motor axons may enable us to optimise the recovery of a denervated muscle. Each motor nerve may be able to control certain segments of muscle or trigger contraction of the whole muscle. The precise interplay between the two populations of motor neurones has yet to be elucidated in animal or clinical models. This large group of dually innervated free muscle transfers gives an insight into this important question

PN EP53 Evaluation of the Scratch Collapse Test for Carpal and Cubital Tunnel Syndrome – A Prospective, Blinded Study

Kate Montgomery, MD; Gerald Wolff, MD, FRCPC; Kirsty U. Boyd, MD, FRCSC;
University of Ottawa, Ottawa, ON, Canada

Introduction: The scratch collapse test is a novel physical exam maneuver for compression neuropathy. In the 2008 paper by Cheng, the test out-performed other common physical exam maneuvers for carpal and cubital tunnel syndrome. Subsequent studies have not reproduced these findings. We sought to prospectively evaluate the sensitivity, specificity, and inter-rater reliability of the scratch collapse test for carpal and cubital tunnel syndrome using blinded observers.

Materials and Methods: Subjects were recruited from all patients referred for upper extremity nerve conduction studies for presumed mononeuropathy. The scratch collapse test was performed twice on each patient, once by the resident and once by one of the nerve conduction technicians. Both observers were blinded to all aspects of the patient's presentation. The sensitivity and specificity for the scratch collapse test were calculated twice, once using electrodiagnostic testing results as the reference standard and a second time using a validated clinical tool (The Carpal Tunnel Syndrome 6) as the reference standard. The inter-rater reliability was also determined.

Results: Using electrodiagnostic criteria as a reference standard, the scratch collapse test as performed by the resident had a sensitivity of 7% and a specificity of 78% for carpal tunnel syndrome (tech 1 had a sensitivity of 7% and a specificity of 94%). Using clinical criteria as a reference standard for carpal tunnel syndrome, the test as performed by the resident had a sensitivity of 15% and a specificity of 87%. For cubital tunnel syndrome, the sensitivity was 10% and the specificity was 90% (for tech 1, the sensitivity was 0% and the specificity was 99%). Kappa was -0.025 (worse than chance alone) for the resident/tech 1 and 0.211 (fair strength of agreement) for the resident/tech 2.

Conclusions: The sensitivity of the scratch collapse test for carpal and cubital tunnel syndrome was lower than that found in other studies, regardless of whether a clinical or an electrodiagnostic reference standard was used. Kappa ranged from worse than chance to fair, highlighting the operator-dependent nature of the maneuver. The strength of agreement overall was lower than previously reported. These results call into question the diagnostic utility of the scratch collapse test for entrapment mononeuropathies of the upper extremity.