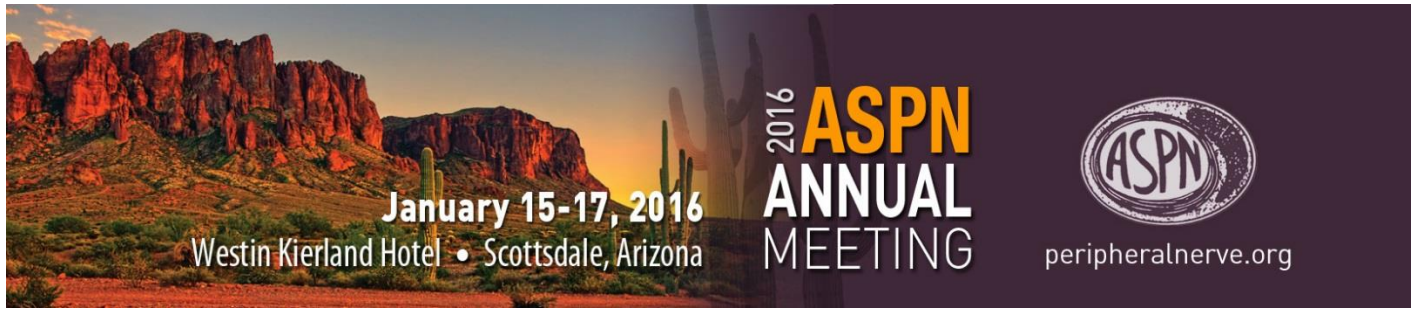



Oral Presentation Abstracts

Scientific Paper Session I

1. Accelerating Mammalian Nerve Regeneration with Electrical Stimulation

Michael P. Willand, PhD¹; Margaret Fahnstock, PhD²; Gregory H. Borschel, MD¹; Tessa Gordon, PhD¹

¹The Hospital for Sick Children, Toronto, ON, Canada; ²McMaster University, Hamilton, ON, Canada

Introduction: Direct electrical stimulation (ES) of denervated muscle can counteract atrophy, but the question remains as to whether ES promotes or hinders reinnervation. Moreover, the question whether daily ES of regenerating nerves is or is not contraindicated remains unanswered. We ask here whether daily ES of 1) regenerating nerves is counterproductive for muscle reinnervation and 2) denervated muscle affects nerve regeneration and functional recovery.

Methods: To address the first question, the cat medial gastrocnemius (MG) nerve was transected and coapted under intraperitoneal Nembutal anesthesia and sterile conditions. A cuff electrode was placed on the nerve proximal to the repair site and connected to a portable stimulator for daily ES at 20 Hz (5 sec on, 5 sec off for 24 hr/day for up to 300 days). The cats were anesthetized with halothane at ~10 day intervals to elicit and record MG muscle contractile twitch and tetanic forces by coupling the foot to a special 'boot' attached to a force transducer. To assess the impact of ES on denervated muscle, the tibial nerve was transected and coapted in the hindlimbs of Sprague Dawley rats, and intramuscular stimulating electrodes were implanted into the gastrocnemius muscle, again under sterile conditions and under isoflurane anesthesia. The muscle was then stimulated 1 hour/day, 5 days/week at 100 Hz for 0.5-3 months. Skilled locomotion was assessed weekly using a tapered beam test. Terminal muscle and motor unit EMG recordings were made in response to stimulation of the tibial nerve proximal to the coaptation site.

Results: Nerve ES did *not* impair nerve regeneration and muscle reinnervation. Rather, reinnervation was accelerated, in confirmation of findings of Nix and Hoft (1983 Brain Res 272:21-25), and was explained by accelerated axon outgrowth across the coaptation site (Brushart et al 2002 JNS 22: 6631-38). Muscle ES also *accelerated* muscle reinnervation concurrent with enhanced expression of muscle brain- and glial cell line- derived neurotrophic factors, assessed by qRT-PCR at two weeks. Importantly, muscle ES resulted in complete functional recovery of skilled locomotion.

Conclusions: Both nerve and muscle ES accelerate and enhance peripheral nerve regeneration, muscle reinnervation, and functional recovery. One possible explanation for the effect of the muscle ES is that the upregulated muscle BDNF and GDNF are bound by p75 and GFR α respectively, on Schwann cells in the distal stump where their presentation to trkB and Ret receptors may be the basis for enhanced nerve regeneration.

2. Digestion of Glial Scar Following Chronic Nerve Compression Injury Can Improve Functional Outcomes

Michele Luu, BS; Minal Tapadia, JD, MD, MA; James Jung, MD; Diana Zhu, BS; Jared Su, BS; Tahseen Mozaffar, MD; Ranjan Gupta, MD

University of California, Irvine, Irvine, CA

Introduction: Chronic nerve compression (CNC) injuries, such as carpal and cubital tunnel syndromes, often persist despite optimal surgical and medical management. Without treatment, CNC injuries progress with increasing sensory dysfunction and eventually developing muscle atrophy. Spinal cord injury (SCI) models have demonstrated that formation of a glial scar rich in chondroitin sulfate proteoglycans (CSPGs) limits SCI outcomes and that CSPG degradation via chondroitinase ABC (ChABC) treatment can improve functional recovery. We hypothesized that a persistent glial scar composed of CSPGs and extracellular matrix (ECM) molecules may limit CNC injury recovery and a ChABC treatment may improve functional outcomes late in the injury progression.

Materials & Methods: An established CNC injury model was created in C57BL/6 mice and Sprague Dawley rats by placing biologically inert tubing around the right sciatic nerve, while maintaining the left sciatic nerve as an internal control. After confirmation of a CNC injury with electrophysiology, nerve specimens were harvested at the species' appropriate early and late time points, i.e. 2-weeks and 6-weeks for mice and 4-months and 6-months for rats. Western blot, PCR, and immunohistochemistry were performed to quantify levels of CSPGs (decorin, aggrecan, brevican, and versican) and ECM molecules (collagen-IV, fibronectin, and laminin-a2). A subset of CNC injured mice were treated with either surgical decompression alone, or decompression with an intraneural injection of chondroitinase ABC (AMS Biosciences, 0.2 µg/uL) at 6-weeks.

Results: Aggrecan showed the greatest change in mRNA levels following rat CNC injury with marked bimodal increases of nearly 25-fold at 1 month and 18-fold at 5-months. Immunohistochemistry analysis for mouse collagen IV, laminin α 2, and fibronectin showed perineurial scarring at 2-weeks. This correlated with western blot data in mice at 2-weeks that showed 6-fold upregulation of fibronectin, 1.4-fold upregulation of laminin-a2, and 2-fold upregulation of collagen-IV. IHC and western blot for mouse decorin demonstrated minimal changes to expression in compressed nerves at 2-weeks but marked upregulation of expression by 6-weeks in epineurium and perineurium. Decompression with intraneural injection of chondroitinase ABC at 6-weeks resulted in marked attenuation of decorin expression.

Conclusion: These data demonstrate that the progressive development of a glial scar largely composed of ECM molecules and CSPGs contributes to the pathogenesis of CNC injury. Degradation of this glial scar is possible by targeting CSPGs with a ChABC treatment and may be an exciting potential therapeutic for late stage CNC injury patients.

3. A Bronze Standard: Nerve Autografts and Schwann Cell Senescence

Gwendolyn Hoben, MD, PhD; Xueping Ee, MD, MS; Lauren Schellhardt, BA; Ying Yan, MD, PhD; Daniel Hunter, RA; Moore Amy, MD; Snyder-Warwick Alison, MD; Sheila Stewart, PhD; Susan E. Mackinnon, MD *Washington University School of Medicine, Saint Louis, MO*

Introduction: Nerve grafting with autograft has long been considered the gold standard. However, the functional outcomes of nerve autografting are often considered merely adequate to poor, especially as graft length increases. Many factors may contribute, but we hypothesize that the graft itself creates a microenvironment that limits regeneration. It has been shown that senescent Schwann cells reduce axonal regeneration and we hypothesize that senescent cells accumulate in isografts (equivalent to autograft in syngeneic animals) and with increasing graft length, senescence increases and regeneration is reduced.

Materials and Methods: A rat sciatic nerve transection model was used to compare a short (2cm) and a long (6cm) isograft with normal nerve as a control. Grafts were analyzed for the presence of senescent cells (positive senescence-associated β -galactosidase, SA β gal) and gene expression changes for cell cycle regulators and secretory factors at 4 and 8 weeks. The number of regenerated axons were assessed at different lengths along the graft after 8 weeks *in vivo*.

Results: After 4 weeks, the long isografts had significantly greater SA β gal staining: 56% of the graft area, compared to only 26% of the short graft. Both grafts had increased gene expression for senescence-associated markers (significantly greater than normal nerve) at 4wks. After 8wks, two markers, p21 and p16, were significantly higher in the long grafts. Expression of GDNF and IL-6 was more upregulated in the long graft at both time points. At a length of 1cm from the proximal coaptation, the short graft had significantly more regenerated fibers compared to the long graft: 20,502 \pm 4,081 versus 11,878 \pm 2,400 and the same pattern was observed at a length of 2cm (Figure 1) Fiber widths in the short graft were greater than those in the long graft indicating greater maturity.

Conclusions: This study shows that in longer isografts there is an increased accumulation of senescent cells, reduced regeneration, and more immature fibers compared to a shorter graft at similar regenerative distances within the grafts. These issues arise despite greater pro-regenerative GDNF expression in the longer graft. As length increases in an iso/autograft, regenerative capacity decreases while senescent glial cells increase, which may contribute to the poor outcomes observed with nerve autografting.

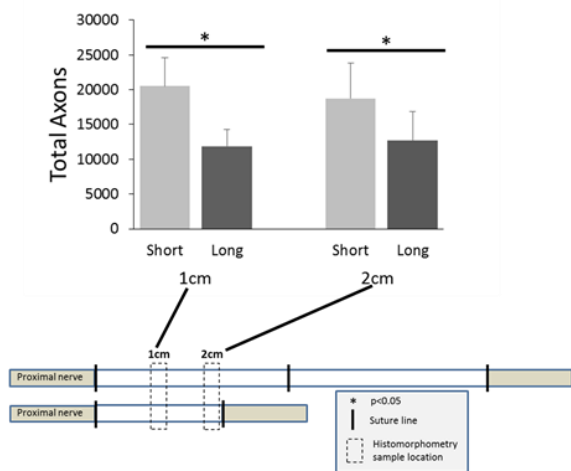


Figure 1

4. Functional Outcome after Reconstruction of a Long Nerve Gap in Rabbits Using Optimized Decellularized Nerve Allografts

Liselotte F. Bulstra, MD¹; Caroline A. Hundepool, MD¹; Patricia F. Friedrich, MD¹; Allen T. Bishop, MD¹; Steven E.R. Hovius, MD²; Alexander Y. Shin, MD¹

¹Mayo Clinic, Rochester, MN; ²Erasmus University Medical Center, Rotterdam, Netherlands

Introduction: Processed nerve allografts provide a promising alternative to nerve autografts with the advantages of a readily available unlimited supply, no donor site morbidity and without the need for immunosuppression. The nerve allografts currently available for clinical use do not provide satisfactory results. The processing technique was optimized to reduce the allografts immunogenicity and cellular debris while maintaining the ultrastructural properties. The aim of this study was to evaluate the functional recovery after reconstruction of a long nerve gap using the optimized nerve allograft in a rabbit model. To study the influence of storage techniques on functional recovery, processed nerve allografts were either cold or frozen stored. The nerve allografts were challenged to the gold standard, the autograft.

Materials & Methods: Nerve allografts were decellularized and stored at either 4 or -80°C. In 36 New Zealand White rabbits, a 3-cm peroneal nerve gap was repaired with either a cold or frozen stored processed nerve allograft or a nerve autograft (control).

Nerve recovery was longitudinally evaluated with ultrasound measurements performed prior to surgery and at 10, 16 and 24 weeks. Functional motor recovery was determined 24 weeks post-operatively using electrophysiology (CMAP), isometric tetanic force (ITF) and wet muscle weight (MW).

Results: The longitudinal ultrasound measurements showed that the cold stored nerve allograft provides faster and earlier regeneration than the frozen stored nerve allograft. At 24 weeks, the cold stored allograft showed significantly similar results with the autograft based on ultrasound measurements. Ultrasound furthermore showed significantly impaired recovery in the frozen stored allograft group compared to both the cold stored allograft and autograft ($P < 0.05$).

The functional outcome measurements muscle weight (MW) and ITF both showed that the cold stored allograft proved to have a similar result compared to the autograft ($p > 0.05$ for both MW and ITF respectively). The frozen stored allograft, on the other hand, had a significantly inferior result to the autograft ($p < 0.05$ for both MW and ITF). The CMAP results showed no significant differences between all three groups.

Conclusions: Nerve reconstruction with the cold stored optimized nerve allograft results in successful recovery of a long motor nerve defect in a rabbit model, statistically equivalent to the gold standard nerve autograft. Freeze storage of the processed allograft impairs the functional outcome.

5. Sirtuins Protect the NMJ from Age-Related Morphological Changes

Alison Snyder-Warwick, MD; Albina Jablonka-Shariff, PhD
Washington University School of Medicine, Saint Louis, MO

Introduction: The neuromuscular junction (NMJ) is the interface between nerve and muscle composed of the terminal nerve, synapse, motor endplates, and glial cells called terminal Schwann cells (tSCs). We have shown that characteristic morphologic changes occur to all components of the NMJ with age. Caloric restriction and exercise may help to reverse the effects of aging on the NMJ, but the mechanism controlling these changes is unknown. Sirtuins are NAD-deacetylase-dependent proteins that counteract metabolic and age-related diseases and demonstrate neuroprotective effects in acute and chronic neurological diseases. We hypothesized that systemic sirtuin overexpression would protect the NMJ from morphological changes associated with aging.

Materials & Methods: The sternomastoid (SM) muscles were harvested from *S100-GFP* mice, which express GFP fluorescence in Schwann cells, and BRASTO mice, which overexpress *Sirtuin 1 (SIRT1)* in the hypothalamus. Immunostaining was performed with α -bungarotoxin (to stain acetylcholine receptors on motor endplates), S100 (to stain tSCs), neurofilament 200 (to stain axons), and DAPI (for nuclear labeling). Quantitative systematic NMJ analysis was performed on confocal images at multiple ages in mature mice.

Results: BRASTO mice had fewer NMJ morphologic abnormalities compared to age-matched controls. The percentage of normal motor endplates in BRASTO mice was approximately double that of controls at 25 months (42% and 22%, respectively) and 33 months (29% vs 12%). In BRASTO mice, 32% of NMJs were innervated compared to 17% in controls at 25 months of age. At 33 months, 7% of NMJs were innervated in BRASTO mice compared to 4% in controls. BRASTO mice had 50% more tSC occupancy at the NMJ compared to control mice at 25 and 33 months of age.

Conclusions: Mice with systemic overexpression of *Sirtuin 1* had improved NMJ morphology compared to wild type controls at 25 and 33 months of age. Specifically, normal motor endplates, NMJ innervation, and tSC occupancy were all increased in the NMJs of the BRASTO mice. These data suggest a metabolic pathway for protection of the NMJ which could have functional implications for patients with neuromuscular pathology.

6. Sensory Supercharge Fails to Improve Muscle Recovery After Injury

Louis H. Poppler, MD, MSCI; Lauren Schellhardt, BA; Ying Yan, MD, PhD; Dan A. Hunter, RA; Susan E. Mackinnon, MD; Matthew D. Wood, PhD; Amy M. Moore, MD

Washington University School of Medicine, Saint Louis, MO

Introduction: Sensory protection with a traditional end-to-end sensory nerve transfer preserves muscle mass and improves muscle force recovery, but requires a second operation to remove the sensory nerve and repair the recipient nerve. Sensory protection with a supercharge end-to-side nerve transfer of a sensory nerve into a motor nerve (SSETS) potentially remedies this dilemma, allowing motor axons to regenerate without the need for a second operation. The purpose of this study was to determine if an SSETS improves muscle force recovery after various periods of muscle denervation.

Methods: Gastrocnemius muscle force and mass was quantified 2 months after sciatic nerve repair in rats exposed to 1, 3, or 5 months of denervation with (experimental group) or without (negative control group) the addition of a saphenous nerve S-SETS of the tibial nerve [n=8/group]. The S-SETS was removed at the time of motor repair. An additional group (3 months denervation + SSETS) did not have the supercharge coaptation taken down to determine the impact of the continued presence of the sensory axons on muscle force. In order to evaluate axon regeneration in the presence of a SSETS coaptation, motoneurons projecting axons into the distal tibial nerve were counted using retrograde labeling 2 months after sciatic transection and repair with (experimental group) or without (control group) a SSETS of the tibial nerve [n=8/group]. The SSETS coaptation site was examined for scar formation using nerve morphometry and transmission electron microscopy.

Results: The number of motoneurons projecting axons distal to the repaired tibial nerve was not different between the SSETS and No SSETS groups (Figure 1a). Muscle mass was significantly greater in the SSETS group with muscle denervated for 3 months, but not at any other time point. There were no differences in muscle force with or without the SSETS unless the SSETS remained intact at the time of motor nerve repair. Leaving the SSETS intact resulted in significantly less muscle force recovery than either removal of the SSETS or No SSETS (Figure 1b-c).

Conclusions: Sensory supercharge does not improve, and may inhibit, muscle force recovery in settings of acute and chronic denervation.

7. Suitable Application of End-to-Side Neurorrhaphy as Schwann Cells Provider to Acellular Nerve Graft

Hidekazu Yoshizawa, MD; Ayato Hayashi, MD; Daiki Senda, MD; Hiroshi Mizuno, MD

Juntendo University of School of Medicine, Tokyo, Japan

Introduction: Previous studies regarding acellular nerve grafts (ANGs) have suggested that axons can regenerate within a limited distance into the ANGs. Axonal elongation into ANGs required proliferating Schwann cells (SCs) from the host and neurotrophic factors from those SCs was believed to be essential for axonal elongation into ANGs. Therefore, applying additional neurotrophic factors or cells such as cultured SCs or induced pluripotent stem cells into ANGs have been conducted and some of them have successfully promoted axonal regeneration into ANGs. In this study, we investigated whether end-to-side (ETS) neurorrhaphy, which is used as an axonal provider, could be useful as an SC provider to support axonal elongation in ANGs.

Methods: We used nestin-green fluorescent protein (GFP) transgenic mice in which only the proliferating SCs developed GFP. We transplanted a 1-cm non-fluorescent ANG to the sciatic nerve via four types of ETS neurorrhaphy (I: control group, II: intact ETS group, III: partial neurectomy ETS unilateral group, and IV: partial neurectomy ETS bilateral group). In vivo imaging of migrated GFP-labeled SCs was performed at the time of surgery and every 7 days. At 4 weeks post-operatively, we evaluated SCs migration in the grafts using histomorphometry. and we also evaluated the SC migration related marker(S100, NRG1, ErbB2) using reverse transcription polymerase chain reactions (RT-PCR).

Results: In vivo imaging, the SCs could migrate partial neurectomy group (group III and IV) than intact group (group II) farther. And the difference of the migration velocity was not apparent between group III and group IV at 2 weeks post-operatively. The average migration distance of the SCs was the longest in group IV($7111\pm351\mu\text{m}$) followed by group III($5451\pm351\mu\text{m}$) and group II($2130\pm337\mu\text{m}$), while group I showed a distance of $0\mu\text{m}$, as measured using whole mount imaging. Abundant regenerated axons were colocalized with constitutively GFP-expressing SCs and anti-neurofilament antibody in group IV. RT-PCR demonstrated that SC migration-related markers (NRG1, ErbB2, and S100) in the graft were the most up-regulated in group IV and the least up-regulated in group I.

Conclusions: Collectively, these findings suggested that ETS neurorrhaphy functioned as an SC provider in ANGs. The process was most significant when an epineurium window and partial neurectomy was performed, and even more remarkable when applied bilaterally. Our results suggest that this approach could be considered as a potential treatment to make ANGs more effective.

8. End-to-Side Neurorrhaphy as Schwann Cells Provider To Acellular Nerve Graft and its Effect

Ayato Hayashi, MD; Hidekazu Yoshizawa, MD; Daiki Senda, MD; Hiroshi Mizuno, MD

Juntendo University of School of Medicine, Tokyo, Japan

Introduction: Acellular nerve grafts (ANGs) are a viable option for reconstructing extensive peripheral nerve injuries based on numerous studies. However, lack of SCs, critical to peripheral nerve reconstruction, limits regeneration in ANGs and makes them inferior to autografts. Numerous studies have reported that neurotrophic factors, cultured SCs, and induced pluripotent stem cells promote nerve regeneration in ANGs. However, using these factors in clinical setting is not easy in the current situation.

In this study, we investigated whether end-to-side (ETS) neurorrhaphy, used as an axonal provider, could be useful as an SC provider in ANGs. We evaluated its effect and availability by grafting ANGs containing migrated SCs via ETS neurorrhaphy into a nerve gap.

Methods: We used Thy-1 yellow fluorescent protein (YFP) 16 mice, in which all axons expressed YFP fluorescence. We transplanted 1-cm cold preserved ANGs to the sciatic nerve via three different ETS procedures: control (group I); ETS with partial neurectomy at unilateral edge of the graft (group II); and ETS with partial neurectomy at bilateral edge of the graft (group III). After 4 weeks, we harvested the graft and transplanted it to the 1-cm sciatic nerve gaps in Thy-1 YFP mice. In vivo imaging of regenerated YFP-labeled axons was conducted at the time of surgery and every 7 days after surgery. At 4 weeks post-engraftment, we evaluated axonal regeneration in the middle of the graft and distal to the graft using histomorphometry. Total myelinated fiber count, g-ratio, myelin sheath thickness, and axon diameter were evaluated under light microscopy and electron microscopy. At 6 weeks post-engraftment, we evaluated motor reinnervation at the muscle endplate under fluorescent dissecting microscopy.

Results: Our results of live imaging show that the average axonal elongation velocity 1 week after grafting was highest in group III (6.86 ± 1.45 mm) followed by group II (3.29 ± 0.29 mm) and group I (0 mm). The total number of myelinated (or regenerating) fibers in the midgraft and distal sections in group III was significantly higher than that in the other groups.

Conclusion: These findings suggest that abundant matured regenerated axons are present in ANGs, wherein SCs migrate via bilateral ETS neurorrhaphy at both graft edges. This could potentially represent a new use of ETS neurorrhaphy and easily apply to a clinical setting. This concept may lead to the development of hybrid/artificial nerves with combined autologous SCs and make ANGs more practical in clinical use.

9. Evaluation of Unmyelinated Axon Regeneration Following Peripheral Nerve Injury: An Alternative to Electron Microscopy

J. Mike Hendry, MD¹; M. Cecilia Alvarez-Veronesi²; Cameron Chiang¹; Tessa Gordon, PhD²; Gregory Borschel, MD²

¹University of Toronto, Toronto, ON; ²The Hospital for Sick Children, Toronto, ON, Canada

Introduction: Advancing peripheral nerve research depends on reliable metrics for evaluating the extent of regeneration. Histomorphometry is a reliable technique to measure myelinated fiber regeneration. However, characterizing unmyelinated fiber regeneration requires the use of electron microscopy that is expensive, time consuming and based on extrapolations from sampling within a section. This study describes a method in which immunohistochemical techniques are used in conjunction with histomorphometry to generate estimates of regenerating unmyelinated axons regeneration in a more timely and resource efficient way.

Materials and Methods: The common peroneal nerve of 12 Sprague-Dawley rats were transected and repaired immediately. Four weeks after repair, a 2 mm segment of common peroneal nerve 10 mm distal to the repair site was harvested, divided in half and each half fixed in 10% formalin or 2% gluteraldehyde, respectively. Specimens in formalin were processed for immunohistochemistry and stained for neurofilament whereas specimens in gluteraldehyde were processed for histomorphometry. A comparison was made between histomorphometry estimates of regenerated myelinated fiber number and total regenerated fiber number estimates (myelinated and unmyelinated axons) derived from non-specific neurofilament staining. Composite tiled electron microscopy images of uninjured rat laryngeal nerve branches were also examined to determine the normal proportions of myelinated and unmyelinated fibers within mixed nerve.

Results: After 4 weeks of regeneration, the mean number of myelinated axons counted from histomorphometry sections was 2071 ± 220 compared with the 4552 ± 217 axons counted in neurofilament stained section. The difference represents unmyelinated fibers, and in this population is approximately 54.5% of the total number of regenerated axons. This estimate is similar to the 55.4% derived from counting each myelinated and unmyelinated fiber directly on electron microscopy from laryngeal nerve branches.

Conclusions: This study describes a more resource efficient technique to generate estimates of unmyelinated fiber numbers in regenerating peripheral nerves, a measurement previously limited to electron microscopy. This data also highlights the significant proportion of unmyelinated axons that are present within injured and uninjured peripheral nerves. Application of this technique may facilitate more research into unmyelinated axon regeneration and an improved understanding of this aspect of peripheral nerve regeneration.

10. Intravital Confocal Spectral Microscopy With Solvatochromic Dyes for the Detection Of Subtle Changes in Schwann Cell Myelin Lipid Composition: Implications for the Study of Remyelination

Joey Grochmal, MD; Wulin Teo, MD; Raveena Dhaliwal, MD; Hardeep Ghambir, PhD; Jo Stratton, MD; Ranjan Kumar, MD; Jan van Minnen, MD; Peter K. Stys, MD; Rajiv Midha, MD, MSc, FRCS(C)

University of Calgary, Calgary, AB, Canada

Introduction: Myelin is an essential component of the peripheral and central nervous system, enabling fast axonal conduction and supporting axonal integrity; diseases of myelin are thereby devastating and are the focus of critically important research. Unfortunately, the detailed study of myelin health, as evidenced by lipid composition and phase state, is currently limited to analysis of dead tissue while using techniques that often involve intense tissue processing and thereby derangement. We suggest that the photophysical properties of myelin-incorporated solvatochromic dyes can be exploited to probe the biochemical composition of living myelin at high resolution.

Methods: Using spectral confocal microscopy, we first analyzed several potential dye candidates for their efficacy and consistency in dead tissue (sciatic nerve fixed with 10% formalin). We found a significant shift in myelin spectra over early post- natal development, and also in altered myelin from genetically deficient mutant mice (Shiverer, SCAP) (Figure 1). We then studied the myelin spectra of nerve derived Schwann cells and Skin derived precursor Schwann cells, as transplanted into a focally demyelinated tibial nerve (Figure 2). We also studied the spectra of exogenous Schwann cells and SKP-SCs as they progressively myelinate in DRG explant co-cultures (Figure 3). Finally, we developed a novel technique for spectral imaging of the living peripheral nervous system, probing the myelin chemistry of Schwann cell transplants in live anesthetized rats (Figure 4,5,6,7).

Results: We demonstrate a consistent bi-phasic evolution of myelin spectra during early remyelination, both in-vitro and in-vivo. Using our novel intravital imaging platform, we again found that there was a bi-phasic evolution of myelin spectra during regeneration in transplanted nerve derived Schwann cells, and also in Skin derived precursor Schwann cells (2way ANOVA, Tukey's post-hoc test, $\alpha 0.05$) (Figure 7). Interestingly, myelin derived from SKP-SCs and myelin derived from Schwann cells have similar spectral profiles during this period of remyelination, as evidenced in all three paradigms (2way ANOVA, Tukey's post-hoc test, $\alpha 0.05$)

Conclusions: Taken together, our findings demonstrate a reliable shift in myelin spectra correlating with regenerative myelin biochemistry (Figure 8). We also find SKP-SC and SC myelin behave in a similar fashion, reinforcing the known ability of SKP-SCs to behave as Schwann cells for the injured nervous system. Such findings take us one step closer for realizing the potential of real-time live imaging and monitoring of myelin chemistry in the clinic.

11. A Glial Cell Line Derived Neurotrophic Factor Delivery System Enhances Nerve Regeneration Across Acellular Nerve Allografts

Kasra Tajdaran, MASc¹; Matthew D. Wood, PhD²; Molly Shoichet, PhD¹; Tessa Gordon, PhD³; Gregory H. Borschel, MD³
¹University of Toronto, Toronto, ON, Canada; ²Washington University School of Medicine, Saint Louis, MO; ³The Hospital for Sick Children, Toronto, ON, Canada

Purpose: Recently, surgeons have been using acellular nerve allografts to bridge nerve gaps but these grafts lack therapeutic levels of neurotrophic factors and therefore, do not support nerve regeneration to the same extent as autografts do. Here we investigated a local delivery system for glial cell line derived neurotrophic factor (GDNF) controlled release to the implanted acellular nerve allografts using drug-loaded poly(lactic-co-glycolic acid) (PLGA) microspheres (MSs) embedded in a fibrin gel. The hydrogel composite served to localize MSs around the nerve allografts and allows sustained GDNF release.

Methods: In a nerve gap model, a 10 mm acellular nerve allograft was used to bridge a 5 mm common peritoneal (CP) nerve gap. In negative control groups, Sprague Dawley rats received no treatment or received fibrin gels with empty MSs at both suture sites of the nerve allograft. Fibrin gels loaded with MSs encasing GDNF with two or four weeks release periods, served as the primary experimental groups. Rats receiving nerve isografts served as the positive control group. Eight weeks after repair, nerve regeneration was assessed using retrograde labeling and collecting nerve samples 10 mm distal to the graft for histomorphometric analysis.

Results: Regeneration of both motor and sensory neurons in all the rat groups with GDNF MS treatment and isograft treatment were indistinguishable and significantly higher compared to the negative control groups. Qualitative and quantitative analysis of the regenerated nerve samples obtained at 10 mm distal from the nerve grafts revealed that groups receiving GDNF MSs had similar nerve morphology to the isograft receiving group, with significantly higher numbers of myelinated axons present in the nerve cross-sections compared with the negative control groups. Fiber frequency analysis indicated enhanced nerve maturity for the GDNF MS and isograft treated groups as the number of fibers with larger diameter (4-6 μm) was higher compared to the negative control groups with more smaller diameter fibers (2-4 μm).

Conclusion: Local administration of GDNF using a biodegradable and biocompatible drug delivery system makes the acellular nerve allografts as effective as the isografts in supporting nerve regeneration. The biomaterial developed in this study has the potential to provide an “off the shelf” alternative in the current management of severe nerve injuries.

Scientific Paper Session II

12. Effects of Selective Nerve Transfers on the Mammalian Motor Unit

Konstantin D. Bergmeister, MD; Martin Aman, MD; Krisztina Manzano-Szalai, PhD; Otto Riedl, MD; Stefan Salminger, MD; Oskar C. Aszmann, MD

Medical University of Vienna, Vienna, Austria

Introduction: Selective nerve transfers (SNTs) have been used for the past decade to treat slow nerve regeneration, neuroma pain and improve prosthetic control. SNTs change the motor unit by connecting motor neurons to new functional targets. Good outcomes have been reported but little is known of the structural and functional effects. This experimental study investigates the effects of SNTs, using a high capacity donor nerve, on the different motor unit levels.

Methods: In rats (male Sprague Dawley 6-8 weeks) the ulnar nerve (UN) was transferred to the long head of the biceps (CLBB) after neurotomy of the biceps motor branch. After 3, 6 or 12 weeks (each N=15), muscle force and motor unit number estimation (MUNE) were analyzed and biceps harvested. The contralateral biceps was not operated and served as control. In additional rats, motor neurons of the CLBB were labeled with Fluoro-Ruby after SNT (N=9) or sham surgery (N=6). In Thy1-GFP rats (male, 6-8 weeks, N=15), the same nerve transfer was conducted to analyze formation of neuromuscular junctions.

Results: All SNTs were functional at harvest and no dropouts occurred. Visual inspection and Bertelli tests revealed no functional elbow deficit at 3, 6 or 12 weeks. Muscle force, muscle weight and MUNE increased progressively from 3 to 6 to 12 weeks. At 12 weeks muscle force was 88%, muscle weight 97.5% and MUNE 116.8%, all compared to contralateral control (figure 1).

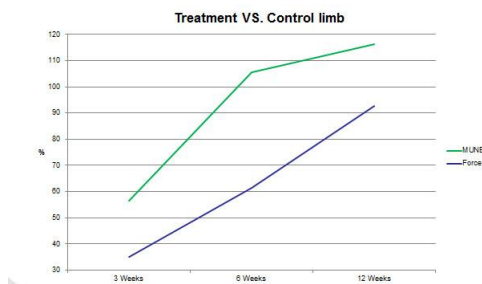


Figure 1 - Retrograde labeling showed 172.3% motor neurons compared to control ($p=0.006$; two-sided t-test). Only 18.75% of the UN's motor neurons innervated the muscle after 12 week. Formation of neuromuscular junctions was present at 3, 6 and 12 weeks. Muscle fiber types changed from predominantly fast (red) to intermediate (green), similar to muscles innervated by the UN (Figure 2).

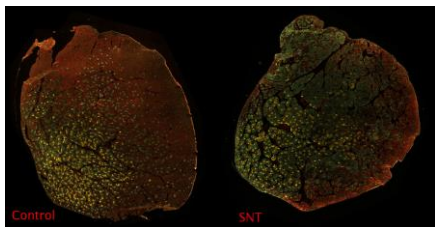


Figure 2

Conclusion: This study shows the course of reinnervation and good functional outcome after a SNT using a high capacity donor nerve. The SNT led to impressive changes on all levels, most interestingly to functional and structural hyperinnervation of the muscle by the ulnar nerve.

13. Use of Electrodiagnostic Testing Prior to Nerve Transfer Surgery in the Setting of Cervical Spinal Cord Injury

Emily M. Krauss, MD¹; Craig M. Zaidman, MD¹; Gerald K. Wolff, MD, FRCPC²; Christine B. Novak, PT, PhD³; Neringa Juknis, MD¹; Rimma Ruvinskaya, MD¹; Susan E. Mackinnon, MD¹; Ida K. Fox, MD¹

¹Washington University School of Medicine, Saint Louis, MO; ²University of Ottawa, Ottawa, ON, Canada; ³University of Toronto, Toronto, ON, Canada

Introduction: Patients with cervical spinal cord injury (SCI) may be candidates for restorative surgery even years after initial injury. While tendon transfer and tenodesis surgery have traditionally been offered, more recently nerve transfers have been used to restore various functions by restoring volitional control of neuromuscular units that may remain intact below the level of the SCI. We hypothesize that electrodiagnostic studies may be used to successfully evaluate the integrity of the motor units for nerve transfers in this patient population.

Materials and Methods: Following human studies review board approval, a comprehensive retrospective chart review was performed. All patients who had undergone previous nerve transfer surgery and who consented to participate in this study were included for review. The protocol for preoperative testing included electrodiagnostic testing done at the discretion of the evaluating neurologist. These previously completed results including electromyography and nerve conduction studies were reviewed and results categorized. Results of intraoperative stimulation of the corresponding nerve fascicles were obtained from the operative notes.

Results: Electrodiagnostic test results accurately predicted the intraoperative nerve stimulation findings. These included putative donor muscle testing using electromyography. While nerve conduction studies of the exact recipient nerves was not always technically possible, the use of surrogate nerves that derive nerve fibers from the same cervical level as the potential donors provided useful quantitative data. For the brachialis to anterior interosseous nerve transfer (to restore finger flexion), the median compound muscle action potential (CMAP) measured to the thenar muscles provided important information about the integrity of the C8/T1 neuromuscular unit. For the supinator to posterior interosseous nerve transfer (to restore finger extension), CMAPS to the extensor indicis proprius were measured and correlation to intraoperative stimulation was more variable.

Conclusion: Electrodiagnostic testing in the preoperative evaluation of SCI patients for suitability for delayed (>1 year post-injury) nerve transfer is challenging. While we believe that this testing has successfully eliminated some patients who were found unsuitable for the nerve transfer surgery, this testing deserves further review and refinement. These tests provide adjunctive information that can contribute to the clinical decision-making process in conjunction with many other complicated factors.

14. Histomorphometric Analysis of Recipient Nerve Tissue in the Setting of Late Nerve Transfer after Cervical Spinal Cord Injury

Gwendolyn Hoben, MD, PhD¹; Dan A. Hunter, RA¹; Christine B. Novak, PT, PhD²; Kristen Davidge, MD, MSc²; Neringa Juknis, MD¹; Rimma Ruvinskaya, MD¹; Susan E. Mackinnon, MD¹; Ida K. Fox, MD¹

¹Washington University School of Medicine, Saint Louis, MO; ²University of Toronto, Toronto, ON, Canada

Introduction: The unique pathophysiology of spinal cord injury (SCI) may allow for the preservation of intact lower motor neurons (LMN) below the level of injury. Patients with mid-level cervical SCI will present with varying degrees of upper extremity function depending on the level of injury. In many cases, shoulder, elbow and wrist function may be intact while hand function is absent. A peripheral nerve transfer procedure may be used to restore volitional control to absent function by coaptation of an expendable donor, which is under volitional control, to a non-functioning recipient that comes off below the level of the SCI. We hypothesize that histomorphometric analysis of recipient nerve tissue will corroborate this assumption in patients who had successful gain-in-function after nerve transfer performed even years after SCI.

Materials and Methods: Following human studies board approval, patients signed an informed consent to participate in this study. Nerve tissue collected at the operative procedure was prepared and fixed in the standard fashion for histomorphometric analysis. Tissue was analyzed by a blinded expert for nerve fiber counts and information regarding the quality of the nerve tissue (fiber density, percent debris, etc.). Patient outcomes were assessed at a minimum of one year post-surgery. Multidisciplinary group consensus regarding the success or failure of the nerve transfer procedure was obtained.

Results: Patients undergoing successful nerve transfer surgery >1 year post SCI, had intact recipient LMN's as indicated by the presence of viable and near-normal appearing nerve fibers. One patient with a suboptimal result did have near normal appearing nerve tissue but other factors (including a profound supination contracture) likely affected the clinical outcome. For patients undergoing nerve transfer <1 year post-injury, results were much more variable. No specific correlation between donor and recipient nerve fiber counts and successful clinical outcome was seen.

Conclusions: Nerve transfers can be successfully employed to restore meaningful function, even many years post-SCI. While previous work suggests at least 20% of total nerve fibers are required to restore meaningful function, this work did not provide clear evidence of a minimum ratio of donor to recipient nerve fibers. Results in the acute nerve transfer patient population were highly unpredictable suggesting that further analysis of these 'rescue' transfers (to both restore volitional control and reinnervate denervated muscles) is required.

15. Evaluation of Infraspinus Reinnervation and Function Following Spinal Accessory Nerve to Suprascapular Nerve Transfer in Adult Traumatic Brachial Plexus Injuries

Heather L. Baltzer, MD; Eric Wagner, MD; Michelle, F. Kircher, RN; Robert J. Spinner, MD; Allen T. Bishop, MD; Alexander Y. Shin, MD

Mayo Clinic, Rochester, MN

Purpose: External rotation (ER) at the glenohumeral joint is the second reconstructive priority after elbow flexion in adult traumatic brachial plexus injuries (TBPI). The spinal accessory nerve (SAN) to suprascapular nerve (SSN) transfer is routinely used to restore ER; however, outcomes of this nerve transfer usually focus on abduction. Our objective was to review our experience with this transfer including prevalence and quality of restored ER, clinical and EMG evidence of infraspinus reinnervation and patient and injury factors that may influence the success of this transfer in restoring ER.

Methods: Fifty-one adult TBPI patients that underwent SAN to SSN transfer with injury-surgery interval <1 year and a post-operative follow up >1 year were retrospectively reviewed between 2000-2013 for demographic and clinical factors. The primary outcome was improvement of ER, with clinically useful ER defined as $\geq 35^\circ$. Secondary outcomes included MRC grade and AROM of ER and EMG reinnervation of infraspinus. Uni- and multivariate analyses were performed to identify predictors of ER restoration.

Results: External rotation was improved in 41% (21/51) of this patient population at an average of 28 months followup; despite 85% of patients demonstrating EMG evidence of reinnervation at an average of 9 months post-operatively. Only 31% (17/51) had clinically useful ER. The average ER AROM=12° past neutral (sd 41; range -60° - 90°) and MRC = 2.2 (median 2; range 2-4). The level of TBPI, specifically isolated upper trunk injury, was the only predictor of ER improvement after SAN to SSN transfer identified on uni- and multivariate regression analyses. ER was clinically evident in 76%, 37% and 26% of upper trunk (UT), UT + C7 and panplexus injuries, respectively ($p < 0.03$). Abduction was not examined due to the variability introduced by secondary deltoid reinnervation procedures. Leechavengvong transfers were performed in 35% of patients but did not include the teres minor branch.

Conclusions: The SAN to SSN transfer demonstrates reinnervation of the infraspinus the majority (85%) of the time; however, this does not translate into any recovery of external rotation among many (59%) patients with only 31% of patients reaching clinically useful ER. These data provide important considerations for patient selection for this procedure. Specifically, the findings of this study demonstrate that likely this technique should be used only in isolated UT injuries, in order to reduce the morbidity of trapezius denervation and potentially spare this muscle for secondary tendon transfers in patients with more extensive TBPI.

16. A Dermal-Based Interface for Providing Sensory Feedback through Residual Peripheral Nerves of Amputees

Alixandra L. VanBelkum, BA¹; Ian C. Sando, MD¹; Gregory R. Gerling, PhD²; Daniel C. Ursu, MS¹; Yaxi Hu, MD³; Elizabeth A. Mays, BSE¹; Paul S. Cederna, MD¹; Melanie G. Urbanek, PhD¹

¹University of Michigan, Ann Arbor, MI; ²University of Virginia, Charlottesville, VA, ³University Medical Center Groningen, Groningen, Netherlands

Introduction: We developed a Dermal Sensory Interface (DSI) with the ultimate goal of providing amputees with meaningful sensory feedback. DSIs are constructed within the residual limb by securing a de-epithelialized skin graft to enclose the end of a residual sensory nerve fascicle. Conceptually, electrical stimuli delivered through electrodes implanted on the DSI activate sensory fibers within the skin graft to provide feedback that is perceived as coming from the missing hand. Our purpose is to validate that: 1) electrical stimulation applied to the DSI evokes afferent nerve action potentials; and 2) nerve fibers are visible throughout the DSI.

Materials and Methods: Forty rat hind limbs were divided into four groups: 1) control full-thickness skin (n=10), 2) control de-epithelialized skin (n=10), 3) control sural nerve (n=10), and 4) DSI (n=10). Groups 1 and 2 were evaluated acutely. Groups 3 and 4 were evaluated 2 months after recovery surgery. During recovery surgery, the sural nerve was transected in the lower limb and either not repaired (Group 3), or the proximal end was secured in a de-epithelialized skin graft pocket (Group 4). For each group, patterned electrical stimuli were applied using surface electrodes and evoked responses were recorded at the proximal sural nerve. Groups 2 and 4 were processed for standard and three-dimensional imaging to visualize nerve fibers.

Results: Electrical stimulation reliably elicited compound sensory nerve action potentials (CSNAPs) in all DSIs. Over 96% of pulses delivered to DSIs at 100 mA above absolute current threshold elicited CSNAPs at frequencies less than or equal to 100Hz. For each group, incremental increases in stimulation current above threshold evoked CSNAPs of increased waveform amplitude (Table 1). All 10 DSIs showed robust revascularization and absence of neuroma. Light microscopy showed nerves sprouting through DSI. Imaging of transparent, three-dimensional DSIs are in process for revealing innervated tissue as seen in control dermal tissue (Fig. 1).

Conclusions: Our findings confirmed: Electrical stimulation of DSIs evoked highly reproducible, graded sensory nerve signals; and, DSIs implanted subcutaneously were healthy by histological examination. DSIs have much potential as peripheral nerve interfaces for sensory feedback.

Table 1: Summary data by experimental group for compound sensory nerve action potential peak-to-peak voltage

	Stimulation Current Amplitude Normalized to Threshold				
	Threshold (T)	T+50 μ A	T+100 μ A	T+150 μ A	T+200 μ A
Control full-thickness skin	13.3 \pm 10.5	26.7 \pm 21.2	33.2 \pm 29.5	39.1 \pm 25.9	59.6 \pm 46.7
Control de-epithelialized skin	15.1 \pm 10.4	27.4 \pm 12.5	44.3 \pm 28.4	51.4 \pm 35.6	64.9 \pm 31.4
Control nerve	17.9 \pm 22.1	104.8 \pm 74.2	145.4 \pm 71.4	167.3 \pm 81.5	182.5 \pm 86.0
Dermal Sensory Interface	11.4 \pm 11.0	23.6 \pm 16.0	34.9 \pm 25.4	43.1 \pm 23.9	51.9 \pm 31.9

CSNAP peak-to-peak voltage recorded from sural nerve during stimulus delivery at increasing current amplitudes.

Stimulation current was normalized to absolute threshold (T) and incremented at 50 μ A.

Abbreviations: μ V, microvolts. Values are mean CSNAP peak-to-peak amplitude (μ V) \pm SD.

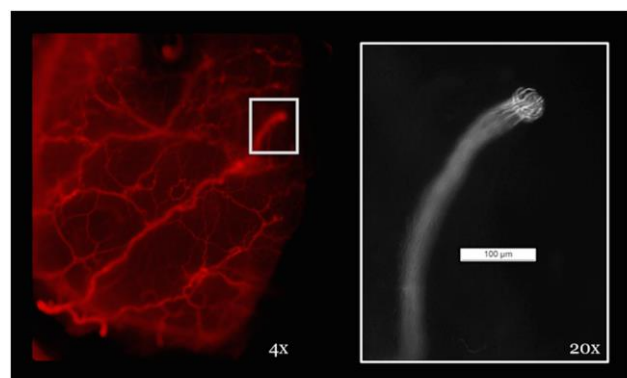


Figure 1: Fluorescent labeling of neurofilament-M in control de-epithelialized skin validates use of IDISCO for visualizing peripheral nerves in dermal tissue. (Below, left) Robust innervation of tissue by nerves of varying size, 4x. (Below, right) Visualization of individual axons within whole, transected nerve, 20x. Modified abstract will include images of DSI constructs, but IDISCO experiments are currently in progress.

17. Efficient Imaging: Examining the Value of Ultrasound in the Diagnosis of Traumatic Adult Brachial Plexus Injuries, A Systematic Review

Maleka Ramji, BSc, MD; Brian Chin, BHSc; James R. Bain, MD, MSc, FRCSC

McMaster University, Hamilton, ON, Canada

Introduction: Traumatic brachial plexus injuries (BP) can result in debilitating injury. Presently, therapeutic decisions are based on mechanism of injury, serial physical examinations, nerve conduction and electromyography, as well as imaging studies. Magnetic resonance imaging (MRI) remains the modality of choice for BP assessment. It is effective in identifying preganglionic lesions but of limited use for postganglionic lesions. Further, it is expensive, time-consuming and not available at the bedside. Ultrasound is a promising newcomer in the diagnostic armamentarium to evaluate BP pathologies. The current literature in this area, although supportive, remains limited. The purpose of this systematic review is to evaluate the feasibility of ultrasound as a diagnostic tool in assessment of adult BP injuries.

Methods: An electronic literature search was completed in MEDLINE, EMBASE, CINAHL and Cochrane databases (up to April 2015). Two independent reviewers completed the screening and data extraction process. Papers were excluded for non-English language, pediatric studies and non-traumatic BP lesions. Case reports, case series, letters, conference proceedings and abstracts were excluded. Methodological quality of studies was evaluated utilizing the STROBE checklist for cohort studies.

Results: Seven studies were included, six prospective cohort and one retrospective studies. Mean age of patients was 39 ± 14 years, with male to female ratio of 2:1. When specified, the most common mechanism of injury was motor vehicle collision, followed by fall and sports-related injuries. Average time between injury to diagnostic ultrasound was 2.9 months ± 9.2 . Expert radiologists interpreted all ultrasound scans. A wide range of ultrasound equipment was used and linear transducer frequency ranged from 5 to 17 MHz. There was a high degree of methodological heterogeneity and only three studies presented data evaluating the accuracy of ultrasound to diagnose traumatic BP lesions. In all, surgical exploration was used as a reference standard. Although the results of the studies are not directly comparable for a meta-analysis, detection rate of BP lesions was generally greater in the upper than the lower roots. One study reported a sensitivity of 97% and specificity of 100% for detection of BP root lesions. Another found ultrasound detection of pre-ganglionic and post-ganglionic lesions to be 95% and 100% respectively.

Conclusion: Individual studies demonstrate ultrasound as an effective diagnostic tool for adult traumatic BP injuries. Current literature however is scarce and poor in methodological quality. Further standardized studies should be performed to confirm the value and feasibility of ultrasound in diagnosis of adult BP injuries.

18. Magnetic Resonance Imaging of Peripheral Nerve: Recent Technical Advances

Justin M. Brown, MD¹; Mark A. Mahan, MD²; Graeme M. Bydder, MB¹; Paolo Felisaz, MD¹; Nikolaus Szeverenyi, MD¹; Robert Nikolov, MD¹; Jiang Du, MD¹

¹University of California, San Diego, San Diego, CA; ²University of Utah, Salt Lake City, UT

Object: The objective of this paper was to describe several recent technical advances in magnetic resonance (MR) imaging of peripheral nerves.

Methods: MR examinations were performed on fresh median, tibial and sciatic nerve samples at 3T and 11.7T using microscopy techniques, as well as on human volunteers at 3T using a clinical system.

Results: Use of ultrashort echo time (UTE) and zero echo time (ZTE) pulse sequences produced high signal from short T2 tissue components in nerve. The epineurium, perineurium and endoneurium/ neural complex were easily recognized. Off-resonance saturation including magnetization transfer produced obvious signal changes. Magic angle effects in different nerve tissue components were demonstrated. Susceptibility differences between the perineurium and surrounding tissues were evident even with ZTE sequences. Obvious diffusion contrast attributable to anisotropic restriction in collagen was seen in the perineurium. Lesser changes were apparent in the epineurium and endoneurium/ neural complex. Tractography showed directional differences within the tissue components of nerves. Contrast enhancement was seen in each of the three constituent tissues of the median nerve and increased over time.

Conclusions: Although this work is still at a proof of principle stage, application of MR techniques used elsewhere in the body, and the use of microscopy is likely to improve the understanding of MR images of peripheral nerves, and lead to improvement in clinical techniques.

19. Long Term Outcome after Treatment of Pediatric Lipofibromatous Hamartoma of the Median Nerve at the Wrist

Megan Anne Conti Mica, MD; Steven L. Moran, MD

Mayo Clinic, Rochester, MN

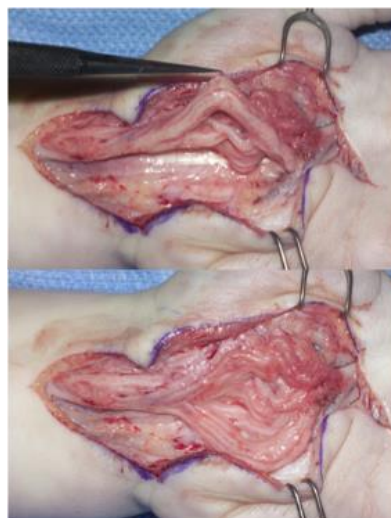
Introduction: Lipofibromatous hamartoma is a benign neoplasm that has a predilection for the peripheral nerves in the pediatric population including the median nerve. While there is no defined treatment of pediatric lipofibromatous hamartoma, management has focused on carpal tunnel release with possible intrafascicular debulking. Unfortunately long-term comparative studies are not available to determine the effectiveness of carpal tunnel release alone or in conjunction with additional surgical procedures. The purpose of this study is to evaluate the long-term outcomes of pediatric patients who suffered from lipofibromatous hamartoma of the median nerve at the wrist who underwent surgical interventions to help facilitate the best surgical treatment.

Material and Methods: A review of our institution's surgical patient database from 1970 to 2006 was conducted using keywords "lipofibromatous hamartoma", "macroductyly", and "tumors of nerve". Patients that were diagnosed with lipofibromatous hamartoma affecting the median nerve at the level of the wrist and were 18 years or younger at the time of the first surgical intervention were included. Medical records were analyzed for patient demographics, presence or absence of macroductyly, physical exam details before and after operative intervention, surgery (or surgeries) performed, complications, pathology reports, and overall outcome.

Results: Eight patients, 4 males and 4 females, were identified through the patient database. Six patients had involvement of the right hand, and 2 had involvement of the left. The average age at first surgery was 6 years (range 1-16). Three patients had associated macroductyly. Seven of eight patients' pathology were conclusive for LFH and one was equivocal. Follow-up was a mean of 122 months (range 5-326). Surgical interventions are delineated in Table 1. 4 out of the 8 had documented sensation, 1 improved, 1 had no change in sensation and two had decreased sensation post operatively. Six patients had no changes in strength while 3 had increase in strength after surgery (two had revision carpal tunnel release with internal neurolysis). Only complication was one patient developed CPRS.

Conclusion: Our study showed mixed results, which is consistent with current literature however those with median nerve release in conjunction with internal neurolysis showed more of a positive outcome with increased strength and sensation. The use of a microscope versus loupe magnification is up for conjecture however due to the results of this study we recommend median nerve release with internal neurolysis along with long term follow up.

Primary Surgery (8 patients)	4 Carpal Tunnel Release alone 1 Carpal Tunnel Release + external neurolysis 1 Carpal Tunnel Release + Tumor Debulking 1 Biopsy (no further surgery) 1 Tumor debulking
Secondary Surgery (6 patients)	2 Carpal Tunnel Revision + internal neurolysis 1 Carpal Tunnel Revision + external neurolysis 1 Carpal Tunnel Revision + epineurolysis 1 Carpal Tunnel Revision + macroductyly debulking Opponensplasty with Median Nerve Resection
Tertiary Surgery (2 patients)	Index ray resection, Median Nerve external neurolysis + opponensplasty Median nerve debulking + external neurolysis



20. Anatomic Characteristics of Supraorbital and Supratrochlear Nerves Relevant to their Use in Corneal Neurotization

Leahthan F. Domeshek, MD; Daniel Hunter, RA; Alison K. Snyder-Warwick, MD
Washington University School of Medicine, St Louis, MO

Introduction: Corneal denervation impairs corneal healing after injury, leading to opacification and blindness. Traditional therapies for corneal anesthesia often fail to preserve vision and generally temporize sequelae, rather than preventing them. Surgical corneal neurotization, a newer treatment approach, directly targets the underlying pathophysiology to prevent corneal destruction and improve healing potential following insult.

Previously, neurotization involved direct transfer of distal contralateral supraorbital (SO) or supratrochlear (ST) nerves to the limbus of the affected eye. A modified technique employs end-to-side nerve grafts from the proximal contralateral SO nerve to the limbus of the affected eye. Both techniques can restore corneal sensation, but the modification avoids extensive bicoronal dissection required in the original technique, preserves contralateral forehead sensation, and enhances versatility of the procedure. We hypothesized that, proximally, SO and ST nerves contain greater axon counts, providing more robust innervation sources for neurotization, despite use of a nerve graft, compared to the distal nerve ends used in direct transfer.

Materials and Methods: For each of nine adult cadaver heads, bilateral SO and ST nerves were dissected from the supraorbital rim to the anterior hairline. For each specimen, the following data were recorded for all four nerves: the presence of notches versus foramina; horizontal distance from midline at the supraorbital rim; distance from the exit of each nerve to its first branching point. Histo-morphometric analyses, including myelinated axon counts, were performed on samples of each specimen's left SO and ST nerves obtained at the level of the supraorbital rim and at points 3cm and 6cm distally.

Results: One specimen had no identifiable ST nerve on the right. Four SO foramina, 14 SO notches, 2 ST foramina, and 5 ST notches were identified. Myelinated axon counts, distance from midline, and distance to first branch data are shown in Table 1. SO and ST nerves contain more axons at the orbital rim than they do distally and, on average, SO myelinated axon counts are greater than ST counts at all distances from the rim.

Conclusions: The proximal SO nerve is the most robust innervation source for corneal neurotization, with 2-3-fold greater fiber counts than at distal locations, and greater counts than ST nerves throughout their lengths. This more robust innervation source may potentiate improved functional outcomes following neurotization.

Table 1: Average Distances and Myelinated Axon Counts for Supraorbital (SO) and Supratrochlear (ST) Nerves

	SO	ST
Distance from midline at level of supraorbital rim	26.5 ± 2.7mm	21±4.0mm
Distance to first branch	2.4±3.5mm	7.29±3.12mm
Myelinated axon count:		
At rim	6017.7±4194.9	2534.0±1666.7
3 cm distally	2558.2±1273.7	1062.4±681.0
6 cm distally	1620.5±1045.7	1112.1±1382.0

Concurrent AAHS/ASPN Scientific Abstract Sessions

91. Nerveregeneration after Reconstruction with Processed Human, Decellularized Allografts – First German Experiences in the Use of the Avance® Nerve Graft

Kristian Weissenberg, MD¹; Eirini Liodaki, MD²; Catharina Elisabeth Strauss, MD¹; Felix Stang, MD²; Peter Mailänder, MD, PhD²; Frank Siemers, MD, PhD¹

¹Bergmannstrost Trauma Center, Halle (Saale), Germany; ²Universityhospital of Schleswig-Holstein, Luebeck, Germany

Introduction: Peripheral nerve injuries occur very often in traumatic injury. In cases in which direct, tension-free repair is not possible, processed human allografts promise good results in nerveregeneration. The morbidities in the donor side such as sensory loss, neuroma formation or prolonged operation time while using an autograft are not seen. Since November 2013 nerve allografts have been available in Germany.

Materials & Methods: In two German hand surgery departments 15 reconstructions of peripheral nerves were performed with Avance® nerve graft (Axo Gen, Inc., FL) by four experienced handsurgeons for different indications until June 2015. In two cases the median nerve was reconstructed up to a defect length of 7 cm. 13 digital nerves were repaired with an allograft. The static and moving 2PD, Semmes-Weinstein Monofilament Testing and in two cases nerve conduction velocity were measured. The follow-ups were performed 6-12 months after surgery depending on the expected axon regeneration time.

Results: During this conference the first German experiences in the use of the Avance® Nerve Graft will be presented. Overall meaningful recovery for all repairs was reported in over 85%. All patients with defect length up to 5 cm reported sensory improvement. No signs of rejection or infection were reported.

Conclusions: The processed nerve allografts seem to be safe and effective in sensory improvement up to a defect length of 5 cm. A sufficient sample size to perform a comparative analysis is still lacking. The outcomes so far represent actual results from literature. More clinical data need to be collected

92. The Effects of Carpal Tunnel Syndrome and its Release on Sleep

Chad M. Turner, MD; Thomas J. Fischer, MD

The Indiana Hand to Shoulder Center, Indianapolis, IN

Introduction: Carpal Tunnel Syndrome (CTS) is the most common compressive neuropathy of the upper extremity. Many patients with CTS complain of nocturnal symptoms, primarily waking with numbness and pain, which affects their sleep quality. Surgeons have recognized that patients' sleep complaints resolve after carpal tunnel release. The rate of nocturnal symptom resolution along with subjective and objective sleep quality outcomes have not been scrutinously evaluated.

Materials & Methods: A prospective study was conducted including 100 patients undergoing carpal tunnel release. The Pittsburg Sleep Quality Index (PSQI) and a carpal tunnel survey were administered preoperatively, 2 weeks postoperatively, and 6 months postoperatively to evaluate time to resolution of nocturnal symptoms and improvement of sleep quality.

Results: Nocturnal symptoms were present in 87% of patients and 50% of patients sought care because of these symptoms. Preoperative PSQI scores averaged 8, (>5 indicates poor sleep quality) with 80% of patients with a PSQI >5. The two week average PSQI had improved to a mean of 5, with 53% of patients with a PSQI score >5. Subjectively 60% of patients reported immediate resolution of their nocturnal symptoms and at two weeks postoperatively 93% reported complete resolution. At 6 months, only 1 patient complained of persistent numbness, however he reported improved sleep quality postoperatively.

Conclusions: Sleep quality is negatively affected by CTS. Most patients can expect resolution of their nocturnal symptoms in the immediate postoperative period, with 60% obtaining immediate resolution, and 93% obtaining resolution by two weeks postoperatively.

93. When Are Static/Moving Two Point Discrimination and Semmes-Weinstein Monofilament Tests Reliable in Children?

Timothy Patrick Lancaster, BS, Karan Dua, MD; Joshua M. Abzug, MD
University of Maryland School of Medicine, Baltimore, MD

Introduction: Objective sensory testing is a critical component of the physical examination, especially when lacerations occur. This is especially true in children as they may be unable to communicate that numbness is present. The purpose of this study was to determine at what age objective sensory tests can be reliably performed.

Materials and Methods: Normal, uninjured patients aged 2-17 years were enrolled in the study. Monofilament and static/moving two-point discrimination tests were performed bilaterally assessing the median, ulnar, and radial nerves. Three trials were performed for each test in each nerve distribution and the child was considered to be able to perform the test if they answered correctly all three times. Statistical analysis was performed utilizing univariable linear regression, Welch's t-test, and one-way ANOVA.

Results: 139 hands were tested utilizing monofilaments and 127 hands utilizing the two-point discrimination tests. The ulnar and median nerve distributions are more sensitive than the radial nerve during monofilament testing ($p < 0.0001$). For both static and moving two-point discrimination, children display the best discrimination ability in the median nerve distribution, followed by the ulnar nerve, and then the radial nerve ($p < 0.000001$). For all nerve distributions, children can better discriminate moving points compared to static points ($p < 0.0001$). Hand dominance generally does not affect monofilament or two-point discrimination scores, except for monofilament testing on the radial nerve, which indicates better sensitivity on the dominant hand ($p = 0.04$). All children 5 and older in our cohort were capable of performing the monofilament test in comparison to children ages 3 and 4 years (33% and 50%, respectively). The percentage of 5 year olds capable of testing is significantly greater than the percentage of 3 and 4 year olds combined ($p = 0.006$). All children 7 and older were capable of performing the two-point discrimination tests, which is a significantly greater percentage than for 6 year olds, of whom only 73% were capable ($p = 0.04$).

Conclusion: Objective testing of sensation can be reliably performed in children. Threshold testing utilizing a monofilament can be performed uniformly in children as young as 5 years, and sometimes as young as 3-4 years. Density testing utilizing two-point discrimination can be performed uniformly in children as young as 7 years with decreasing reliability in younger children.

94. Interhemispheric Plasticity in Response to Peripheral Nerve Injury

Thomas Hansson, MD, PhD; Lotta Fornander, MD; Torbjörn Nyman, MD

Linköping University, Linköping, Sweden

Objective: Recovery from peripheral nerve injury in adults results in profound abnormalities in sensory perception despite improved microsurgical technique. It is of great importance to increase the understanding of cortical changes in response to peripheral nerve injury to improve the rehabilitation of these patients. We have previously described a transient increase in the contralateral primary somatosensory cortical activation area (fMRI) following nerve damage and repair (Hansson, Brismar 2003). In addition, there is growing evidence of interhemispheric plasticity. Studies of rats with a denervated paw show a transfer of activity from the contralateral to the ipsilateral hemisphere. Our objective was to study the ipsilateral cortical activation pattern in patients with median nerve injury.

Methods: Eleven healthy volunteers (mean age 24) and four patients (mean age 39) with median nerve injury at the wrist, repaired with epineural suture at least two years prior to the examination, were included in the study. 3T Functional MRI (fMRI) was used to measure brain activity while the median- and ulnar nerve innervated fingers of both hands respectively were given tactile stimulation by an air-driven brush. The static two point discrimination (2pd) test was used to evaluate sensory function. Data analysis was performed using SPM12 and the laterality index (LI) was calculated to evaluate redistribution of hemispheric dominance.

Results: All patients showed abnormal 2pd in the injured median nerve innervation area (2pd 8->15mm). The patients had normal 2pd (2pd <5mm) in the healthy hand and in the ulnar fingers of the injured hand. All healthy volunteers had normal 2pd. fMRI showed a higher degree of ipsilateral activity in the parietal lobe of the patients than in the group of healthy volunteers and there was a significant difference in LI between the two groups (mean patients 0.21, mean healthy volunteers 0.60, $p < 0.05$).

Conclusions: Our study showed that patients with median nerve injury have a lower LI, meaning a more bilateral activation pattern in the somatosensory cortex compared to a group of healthy individuals. Healthy individuals display a greater degree of contralateral dominance to unilateral median nerve stimulation. The relative increase in the ipsilateral contribution may compensate for the disorganised contralateral somatosensory cortex i.e. it may be a part of the interhemispheric plasticity in response to peripheral nerve injury.

95. Validity of the DASH Questionnaire in Upper Extremity Nerve Injury

Christine B. Novak, PT, PhD

University of Toronto, Toronto, ON, Canada

Introduction: Self-report questionnaires such as the Disabilities of the Arm, Shoulder and Hand (DASH) are used to assess upper extremity disability as a single construct score. The purpose of this study was to evaluate the validity of the factor structure and individual item completion of the DASH questionnaire in patients with upper extremity nerve injury.

Materials & Methods: Data from a previous cross-sectional study which evaluated patients with an upper extremity nerve injury were used. Institutional Research Ethics Board approval was obtained for secondary analyses of these data. Descriptive and factor analyses were performed.

Results: Patients (n = 242; 170 men, 72 women) with upper extremity nerve injury who completed the DASH were included in this study; diagnoses included distal nerve injury (n = 131) and brachial plexus or single proximal nerve injury (n = 111). Most patients (n = 227, 94%) completed all questionnaire items with a mean DASH score 47.3 ± 22 and mean QuickDASH score 50.4 ± 22 . Using mean item scores for replacement of missing items, the mean DASH score was 46.9 ± 22 . The highest scored item (indicating increased difficulty) was related to recreational activities and the lowest scored item was related to transportation needs.

The internal consistency was high for the DASH ($\alpha = 0.96$) and QuickDASH ($\alpha = 0.90$). For the DASH, a 3-factor structure had the highest variance (60.7%) and no overlap between factors. The 3-factor structure revealed domains related to: 1) light effort tasks; 2) greater effort tasks and; 3) limitations in social/work activities and pain. For the QuickDASH, a 2-factor structure had the highest variance (62%) and the item regarding limitation in activity was the only item with overlap between factors.

Conclusions: The DASH completion rate and internal consistency of all questionnaire items was high. In this sample of patients with nerve injury, the confirmatory factor analysis of the DASH and QuickDASH indicated a multi-factor construct. These multi-factor domains should be considered when utilizing the DASH as a single construct score of upper extremity disability.

96. Level I Evidence: How Much Volume of Local and How Long Should You Wait for an Effective Median Nerve Block?

Lyndsay M. Lovely, BSc, MSc(OT)¹; Donald H. Lalonde, BSc, MSc, MD²

¹Dalhousie Medicine New Brunswick, Saint John, NB, Canada; ²Dalhousie University, Saint John, NB, Canada

Introduction: There is little high level evidence to guide us to the ideal volume of local anesthesia we should inject to perform the ideal median nerve block at the wrist. There is a similar lack of high evidence for how long we should wait after injection before we operate. This study provides level I evidence in the comparison of 5cc vs. 10 cc of buffered lidocaine with epinephrine for the efficacy of median nerve blocks. It also provides a surprising answer to the question of how long does it take after injection for the nerve to reach peak anesthesia.

Materials & Methods: This was a prospective double-blinded randomized control trial in which each participant acted as his/her own control. All 14 volunteers underwent blinded randomized bilateral median nerve blocks of 5cc on one side and 10cc of 1% lidocaine HCl with 1:100,000 epinephrine and 1cc 8.4% bicarbonate in the other wrist. One surgeon performed all 28 blocks over 1 minute at 5mm proximal to the wrist crease and 5mm ulnar to the median nerve. He wrapped all wrists with bandages to blind injectees and data collectors. After injections, the blinded data collectors asked participants in 5-minute intervals whether the level of anesthesia had increased in the last 5 minutes. When the level had not increased for 15 consecutive minutes (3 consecutive negative responses), we determined the last increase to be the time to peak anesthesia. After each reported negative response, the data collectors poked the fingertips with a sterile 30-gauge needle to determine where pain sensation remained intact.

Results: Following the median nerve blocks, 7 participants in the 5cc group and 1 participants in the 10cc group failed to reach complete numbness to pin prick in the median nerve distribution. On average, participants reached maximal numbness at 117.86 minutes with 5 cc and required less time to reach maximal numbness with 10 cc (106.07 minutes). A statistically significant difference was demonstrated between the survival curves for 5 cc and 10 cc, $\chi^2(1) = 4.04$, $p < .05$.

Conclusions: We recommend using a minimum of 10 cc of 1% lidocaine HCl with 1:100,000 epinephrine and 1cc 8.4% bicarbonate for non-ultrasound guided wrist blocks. We also recommend waiting a minimum of 40-45 minutes after injecting the median block to allow nerve penetration by the local anesthetic before making an incision in that nerve distribution.

97. Demographics and Outcomes of Radial Tunnel Syndrome Release: A Single Surgeon's Experience of 97 Cases

Ryan W. Schmucker, MD; Shaun D. Mendenhall, MD; Timothy H. Daugherty, MD; James N. Winters, MD; Jordan J. Myhre, BS, BA; Michael W. Neumeister, MD
Southern Illinois University School of Medicine, Springfield, IL

Introduction: Compression of the radial nerve in the proximal forearm can cause two distinct syndromes, termed radial tunnel syndrome (RTS) and posterior interosseous nerve (PIN) syndrome. While patients with PIN syndrome have distinct motor symptoms, radial tunnel syndrome is a clinical diagnosis of pain over the radial tunnel in the dorsal forearm. Radial tunnel syndrome can be a repetitive use injury or can occur idiopathically. Patients often have multiple medical comorbidities and concomitant upper extremity compression neuropathies. The treatment of RTS is surgical release of the radial nerve.

Materials and Methods: After IRB approval, a retrospective chart review was conducted of all patients undergoing radial tunnel release (RTR) between 2008-2014. Charts were analyzed for patient demographics, comorbidities, concomitant compression neuropathies, preoperative symptoms, nerve conduction study findings, anatomic sites of release, as well as surgical outcomes and complications.

Results: In total 81 patients (66 female, 15 male) who underwent 97 radial tunnel releases were included in the study. Overall 86% of patients undergoing RTR also underwent a concomitant nerve decompression surgery. Medical comorbidities occurring most often in RTS patients included depression/anxiety (60%), obesity (48%) and diabetes (17%). 53% of patients were smokers. Preoperatively 98% of patients had pain with palpation over the radial tunnel while only 15% had muscle weakness and 7% had numbness. Preoperative nerve conduction studies were positive for RTS in 22% of patients. The most common anatomic site of compression was the arcade of Frohse which required release in 96% of patients, while secondary sites of compression included the extensor carpi radialis brevis (68%) and the vascular leash of Henry (67%). We experienced a 12% complication rate, which included patients with persistent pain, dysethesias, and weakness. Our recurrence rate was 3% and 98% of patients went on to recover fully.

Conclusions: Careful physical examination is required to diagnose radial tunnel syndrome as patients often present with multiple compression neuropathies. The most reliable diagnostic sign is pain with palpation of the dorsal forearm overlying the radial tunnel. While the most conspicuous site of compression is the arcade of Frohse, it is necessary to release all sites of compression including the vascular leash of Henry, the ECRB, and the distal supinator. To our knowledge this is the largest reported single surgeon series in the literature demonstrating that radial tunnel release is a safe, effective procedure that can provide dramatic relief of symptoms for affected patients.

98. Tendon Transfers for Radial Nerve Palsy in Brachial Plexus Injuries

Ali Izadpanah, MD; Allen Bishop, MD; Robert Spinner, MD; Michelle, F. Kircher, RN; Alexander Y. Shin, MD
Mayo Clinic, Rochester, MN

Introduction: Every year more than 1 million people suffer from peripheral nerve injuries. In this study, we sought to determine the outcome of tendon transfers in our patient population with brachial plexus injury undergoing radial nerve palsy tendon transfers and to further compare the results with patients undergoing similar transfer for non-brachial plexus type injuries.

Methods: A retrospective chart review analysis of patients undergoing tendon transfers to address radial nerve deficits treated at our institution from September 2001 to October 2014 with minimum of six months follow up was performed. DASH scores were recorded in patients with brachial plexus injuries and compared with the postoperative values. A paired t-test analysis was performed between the preoperative DASH scores and postoperative values.

Results: A total of 71 patients underwent tendon transfers for radial nerve palsy. Forty two patients (59.2%) were due to brachial plexus injuries and 29 patients (40.8%) were secondary to isolated radial nerve palsies. Twenty seven patients had the traditional Starr transfers. Out of these 27 patients, 15 (55.6%) had palsy secondary to plexus injuries and the remaining 12 (44.4%) had palsies secondary to isolated radial nerve palsies. There were no complications in perioperative period. The DASH score for patients with brachial plexus injury improved from 51.5 ± 24.09 to 27.98 ± 10.95 ($p=0.0026$). All patients in group 1 achieved full finger extension, wrist extension of $42.5^\circ \pm 8.4^\circ$ from $-26.5^\circ \pm 6.8^\circ$, and a postoperative wrist flexion of $20.9^\circ \pm 6.9^\circ$. Patients in group 2 all achieved full finger extension other than two patients. The average postoperative wrist extension in this group was $42.5^\circ \pm 6.89^\circ$ and $50^\circ \pm 11.18^\circ$ of wrist flexion. All patients other than the two with suboptimal outcomes had British Medical Research Council System (BMRC) score of 5. The two patients in group 2 with weak extension had preoperative BMRC scores of 4. Not considering the two patients with BMRC scores of less than 5, there was no difference between the two groups in postoperative wrist extension ($p=0.80$), finger extension ($p=0.90$). However the wrist flexion at final follow up was significantly better in group 2 ($50^\circ \pm 11.18^\circ$) compared to group 1 ($20.9^\circ \pm 6.9^\circ$) ($p>0.05$).

Conclusion: Starr transfer is an effective method in patients with both isolated radial nerve and combined radial nerve palsies in brachial plexus patients. Both groups of patients achieved similar improvements provided they had similar muscle strength preoperatively. Only a subgroup of patients with BMRC of less than 5 had less than optimal range of motion after these transfers.

99. The Nerve of Henle: An Anatomic and Sympathetic Study of the Ulnar Innervation

Eduardo Pablo Zancolli, MD¹; Diego Piazza, MD²; Carlos Lozano, MD³; Christina Kaufman, PhD³; Jim Kleinert, MD³; Luis Schecker³; Eduardo Zancolli, MD⁴

¹Kleinert Kutz, Louisville, KY; ²Fundacion Favaloro, Buenos Aires, Argentina; ³Christine M. Kleinert Institute, Louisville, KY; ⁴Hospital Naval Pedro Mallo, Buenos Aires, Argentina

Introduction: Initially described by Bourguery, the Nerve of Henle(NH) is described as a branch of the ulnar nerve(UN) in the forearm. Studies on the NH are few. Balogh et al, reported the presence sympathetic nerve fibers, but only found the NH in less than 60% of cases. This study will present data on the presence of the nerve and frequency of sympathetic fibers in relation to the ulnar nerve and its branches in the forearm. The data will be analyzed to determine if the absence of the NH influences the number of the sympathetic fibers of the posterior interosseous nerve (PIN).

Materials and Methods: The UN was dissected in 15 fresh cadaveric forearms from the medial epicondyle to the pisiform under 3.5X magnification. The origin of the nerve of the NH was measured from the medial epicondyle and the pisiform. The NH was identified and dissected in its course with the ulnar artery(UA) through out the forearm. The ulnar innervation was divided in 3 segments. 2 cm nerve samples where obtained from each segment. An additional PIN sample was obtained in each specimen. The nerve samples were fixed in 10% formalin and paraffin embedded. The tissue was stained for sympathetic fibers using Tyrosine hydroxylase antibody (ABCAM catalog #ab62111) and anti-rabbit Ig-HRP (Life Technologies, cat# 65-6120). The number of sympathetic fibers per fascicle where quantified using Motic images Plus (www.motic.com).

Results: The NH was present in 100% of the cases. In 80% had a *typical* presentation (McCabe and Kleinert). In the *typical* presentation the NH divided from the UN on average 10.51 cm distal to the medial epicondyle and 15.88 proximal to the pisiform. In the *atypical* presentation the NH's origin was 17.6 cm distal to the medial epicondyle and 8.8 cm proximal to the pisiform. The dorsal sensory branch divided from the UN on average 7.78 cm proximal to the pisiform. Sympathetic nerve fibers were found in all nerve samples. However the NH had a higher number of sympathetic fibers per mm² of fascicle area, compared to the UN and Dorsal Sensory Nerve.

Conclusion: Data collected to date on freshly embalmed specimens revealed the presence of the Nerve of Henle in all forearms. A higher concentration of sympathetic nerve fibers and migration of the nerve into the ulnar artery suggests the NH may be a good target in the treatment of vasospastic disorders in the hand.

100. Predictors of Return to Work After Carpal Tunnel Release in a Workers' Compensation Population

Jennifer Y. Kho, MD; Michael Gaspar, MD; Patrick Kane, MD; Sidney M. Jacoby, MD; Eon K. Shin, MD
Thomas Jefferson University, Philadelphia Hand Center, Philadelphia, PA

Purpose: Workers' compensation (WC) patients take longer to return to work after surgery than non-compensated patients for a variety of reasons. We hypothesized that psychosocial factors could be a predominant factor of time to return to work (RTW) in the WC population.

Methods: This retrospective review examined all WC patients who underwent open carpal tunnel release surgery over a five-year period by one of three fellowship-trained hand surgeons at a single institution. One-hundred and sixty wrists in 115 patients (70 unilateral, 45 bilateral) satisfied inclusion criteria. Demographic, medical and surgical data were obtained from patient records. Univariate and multivariate analyses were performed to assess predictors of RTW.

Results: Average age at the time of surgery was 49.5 +/- 8.7 years. Females comprised 61% of the patients. Eighty-nine percent of all patients returned back to full duty. Average return to work in all wrists was 12.53 weeks (SD +/- 11.29), compared to 3 weeks in historical controls. There was no significant difference in RTW between unilateral and bilateral surgery ($p=0.60$). Predictors of delayed RTW in multivariate analyses were depression with or without anxiety ($p<0.001$), chronic pain and/or fibromyalgia ($p=0.003$), history of opioid use ($p=0.001$), and pre-operative work status (full-duty versus not full-duty) ($p<0.001$). In a multivariate regression model, these factors accounted for 68% of the variance in RTW in the WC population. Neither pre-operative motor nerve conduction velocity nor job type was predictive of RTW.

Conclusions: In this study, patients with a WC claim took longer to return to work after carpal tunnel release surgery than patients without such a claim. A psychiatric diagnosis of depression and anxiety was the most predictive factor of RTW, followed by opioid use, chronic pain conditions, and pre-operative work status. These factors explained nearly 70% of the variation in RTW. Disease severity and job type did not necessarily delay RTW. The aforementioned factors can help prognosticate which WC patients will have a protracted post-operative recovery and perhaps target additional therapeutic intervention to facilitate a more rapid return to work and finally, to inform employers of which patients could be expected to return to work in delayed fashion.

101. Comparison of Ulnar Intrinsic Function following Supercharged End-to-Side AIN Transfer to Ulnar Motor Nerve: A Matched Cohort of Study High Ulnar Nerve Injury Patients

Heather L. Baltzer, MD; Alice Woo, MD; Christine Oh, MD; Steven L. Moran, MD

Mayo Clinic, Rochester, MN

Purpose: To review our experience with high ulnar nerve injury patients that underwent a supercharged end-to-side anterior interosseous to ulnar motor nerve (SETS) transfer along with conventional surgical treatment. These patients were compared with a matched cohort of patients that did not have a SETS transfer to assess return of intrinsic function

Methods: A retrospective matched-cohort study identified all patients that underwent the SETS transfer between 2000-2014 and a second cohort of ulnar nerve injury patients that did not have the transfer, matched based on age, level and mechanism of injury (transection, compressive). The primary outcome was ulnar intrinsic function improvement, which included evidence of reinnervation on clinical examination and/or EMG. Dichotomous and continuous variables were compared with Fisher's exact and Student T-tests, respectively.

Results: Thirteen SETS patients with appropriate follow-up were identified. The average age at surgery for SETS patients and the matched cohort was 35 (+/- 14) and 35 (+/- 16) years, respectively. Transection of the ulnar nerve at or above the proximal third of the forearm represented 50% of patients, the remainder of injuries were compressive in nature. All patients presented with clinical or electrodiagnostic evidence of ulnar intrinsic denervation. Eleven SETS transfer patients (84%) had clinical evidence of recovery of intrinsic function compared with five (38%) of patients that did not have the SETS transfer ($p < 0.05$). Following ulnar nerve transection, greater intrinsic function return was demonstrated following the SETS transfer (85% vs. 14%, $p = 0.03$), while compressive injuries had comparable intrinsic function return between groups (67%). Where documented, the average time to first evidence of recovery was 2.9 months (+/-1.4) and 3.8 months (+/- 4.5) with and without the SETS transfer, respectively ($p > 0.05$). Nerve transection repairs augmented with a SETS transfer demonstrated ulnar intrinsic recovery on average at 3.4 months (+/-1.7), while recovery occurred closer to a year or not at all with repair alone.

Conclusions: This matched cohort study demonstrates that the SETS transfer results in increased ulnar intrinsic reinnervation following high ulnar nerve injury. From both a frequency and timing of recovery standpoint, this finding appears to be most relevant among patients with transection compared to compressive type injuries.

102. Virally Mediated Brachial Plexus Neuritis: A Case Series and Surgical Algorithm

Anthony Thanh Vu, MD; Emily Louden, MPH; Melissa Miller, RN, BSN; Ann Schwentker, MD; Kevin Yakuboff, MD
Cincinnati Children's Medical Center, Cincinnati, OH

Introduction: Virally mediated brachial plexus neuritis can cause acute flaccid paralysis of the upper extremity. It involves the proximal musculature with no sensory deficits. Recently, there has been an outbreak in our region with several patients referred to our center for treatment. Review of the literature and CDC reports suggest that late recovery is not expected. While there have been proposed surgical strategies, there is currently no established surgical algorithm. Following our early experience with the contralateral-C7 (cC7) transfer for brachial plexus birth palsy, we have developed a treatment algorithm for this patient population.

Materials & Methods: We retrospectively reviewed our database for all children diagnosed with suspected virally mediated brachial plexus neuritis over the past 12 months. Demographics, clinical course, Mallet scores, magnetic resonance imaging (MRIs), and electromyography (EMG) results were reviewed. A surgical algorithm was created based on our experience.

Results: We had a total of four patients in our series, all with a preceding viral-like upper respiratory illness. Average age at diagnosis was 4.5 years. All patients presented with a flaccid shoulder and elbow with shoulder subluxation and some useful hand and wrist function. A viral work-up was performed on three patients but no causative species was identified. Three patients had abnormal findings on cervical spine MRI. Because of poor recovery, all patients have been scheduled for surgery within 9 months of presentation. Our algorithm is based on early intervention in cases where there is no clinical improvement seen within 6-9 months from onset of paralysis. Nerve transfers for shoulder function include spinal accessory to suprascapular nerve. Radial to axillary nerve transfer is generally not available because of poor or absent triceps function. Nerve transfers for elbow function include intercostals to the musculocutaneous nerve or the cC7 to the upper trunk. Although our patients had some recovery of hand function, this was incomplete in all children, thus an Oberlin or double fascicular transfer is not recommended. In the case of severe hand deficit, we only recommend using cC7 to the lower trunk if the patient is under 2 years old.

Conclusions: Brachial neuritis must be considered in the differential of an acute, painless, flaccid extremity. Work up includes EMG, MRI, and viral serologies. Our proposed algorithm is based on early intervention after determining that adequate recovery is not likely, usually within 6-9 months post-injury.

103. Risk Factors for Revision After In-Situ Ulnar Nerve Decompression with or without Medial Epicondylectomy in Patients with Idiopathic Cubital Tunnel Syndrome

Michael P. Gaspar, MD; Patrick M. Kane, MD; Dechporn Putthiwara, MD; Sidney M. Jacoby, MD; A. Lee Osterman, MD
Thomas Jefferson University, Philadelphia Hand Center, Philadelphia, PA

Purpose: To compare revision rates after ulnar nerve in-situ decompression alone or with medial epicondylectomy (ME) for idiopathic cubital tunnel syndrome (CuTS) and identify patient risk factors for revision.

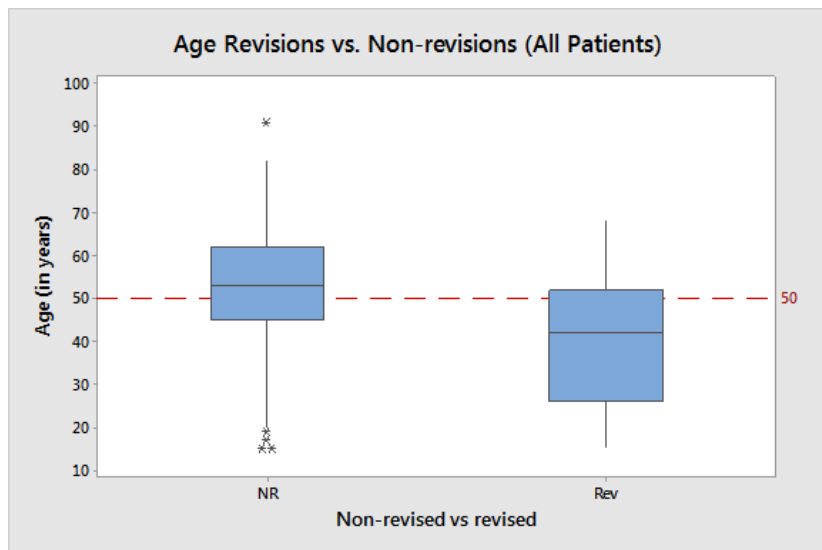
Methods: We conducted a retrospective chart review of all patients treated at one institution with an open in-situ ulnar nerve decompression with or without ME for idiopathic CuTS from 2001 through 2010. Revision rates were determined by identifying patients who underwent additional surgeries for recurrent or persistent ulnar nerve symptoms. Bivariate analysis was performed to determine which variables had a significant influence on the need for revision surgery and used to develop a binary logical regression model.

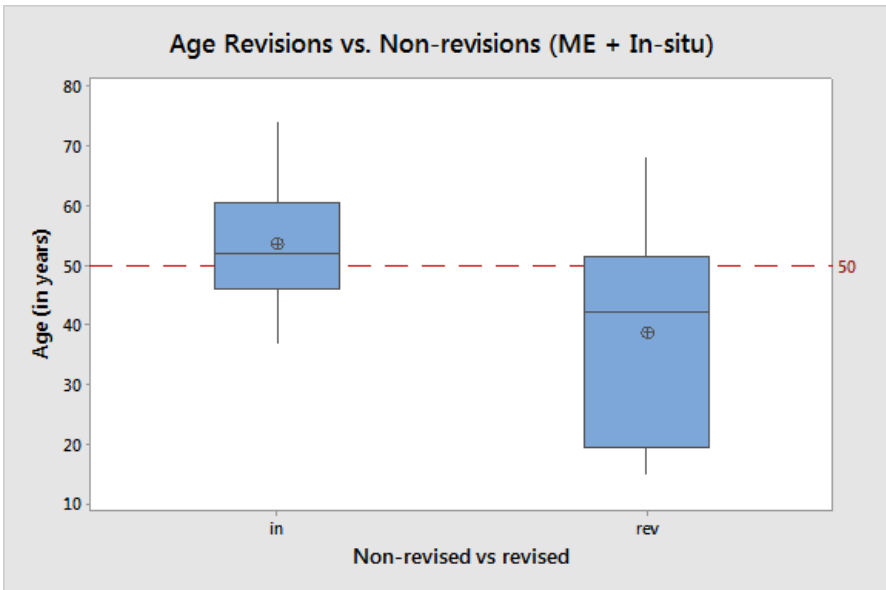
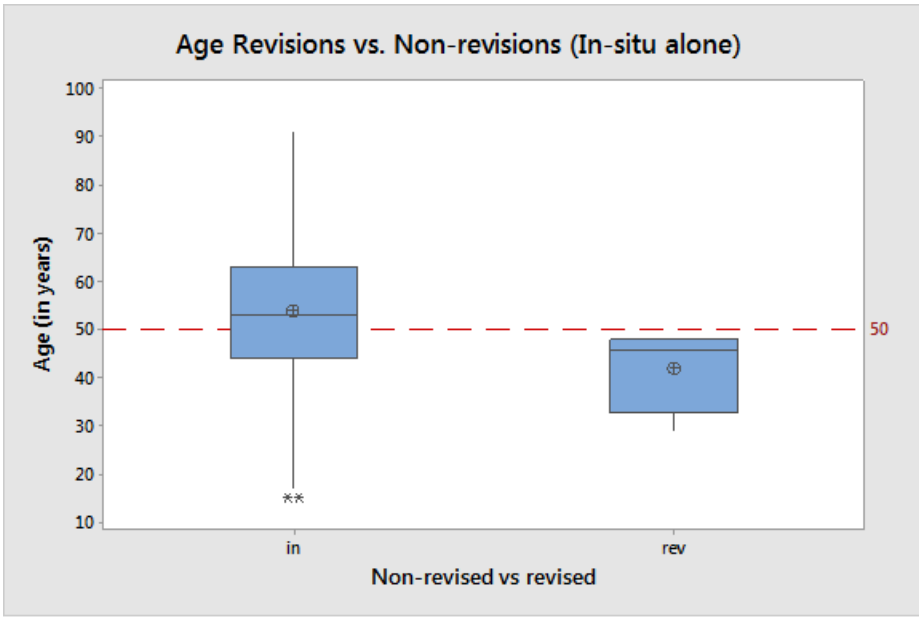
Results: Revision surgery was required in 4.4% (13 of 293) of all surgeries, with a significantly higher rate performed following in-situ ulnar nerve decompression with ME (15.5%) versus decompression alone (1.7%; $p < 0.0001$). Predictors of revision surgery included initial age of less than 50 years (Relative Risk = 4.72; see Figures 1-3) and an associated Workers' Compensation claim (RR 2.51).

Conclusions: For patients with idiopathic cubital tunnel syndrome, the risk of revision surgery was significantly greater following in-situ decompression with ME versus decompression alone. Patients younger than 50 years of age are at a higher risk for needing revision, as are patients with associated Workers' Compensation claims. Patient specific factors, including gender, medical and smoking history, symptom(s) and McGowan staging do not appear to have any significant impact on the likelihood of revision cubital tunnel surgery.

Level of Evidence: Prognostic Level III

Figure 1: Age distribution of cases (patients requiring revision surgery) versus controls. Note the proportion of patients in both groups relative to the age of 50 years.





104. Recovering Extension Function Using a Modified Contralateral C7 Neurotization in BPAI Patients

Su Jiang, MD

Huashan Hospital, Fudan University, Shanghai, China

Backgrounds: In brachial plexus injuries with nerve root avulsions, the options for nerve reconstruction are limited. More and more emphasis has been put on the extension function of the paralyzed limb. Contralateral C7(CC7)transfer has gained international acceptance in treating brachial plexus avulsion injuries, however the results has not been satisfactory when neurotizing median nerve for flexion function recovery, mainly because of a long nerve regeneration process and irreversible muscle atrophy. It is of interest to know how it works when transferring to recover extension function, this report presents our results of extension function recovery using a new procedure involving contralateral C7 nerve transfer directly to the injured middle trunk in patients with BPAI.

Methods: Five male patients were treated from December 2012 to March 2014. Their ages ranged from 22 to 35 years (average, 28 yr). The interval between trauma and surgery ranged from 2 to 6 months(mean, 4 mo). All patients had total brachial plexus avulsion, which were confirmed during the operation. The contralateral C7 nerve root was sacrificed totally and its distal end was transferred to the proximal end of the middle trunk supraclavicularly behind the musclic sternocleidomastoideus, with the sural nerve grafting. One month aRecovery of elbow, wrist and finger extension was evaluated with use of the modified British Medical Research Council muscle grading system. Electromyography studies were also included.

Results: The length of the harvested contralateral C7 nerve root was 4.5 ± 0.5 cm. The nerve graft was 9.5 ± 2.5 cm long. Transient contralateral sensory symptoms were reported in all patients, weakness of elbow extension were also monitored in 2 patients, which recovered within 3 months postsurgery. The mean follow-up period (and standard deviation) was 24 ± 5 months (range, nineteen to twenty-nine months). Compound muscle action potentials(CMAP) could be recorded 9 ± 2 months postsurgery on the triceps long head, and 15 ± 4 months postsurgery on the ECRL. Motor function with a grade of M3+ or greater was attained in all the patients for elbow extension, 80% of the patients for wrist extension, 60% of the patients for finger and thumb extension.

Conclusion: This modified procedure of transferring contralateral C7 nerve root directly to the injured middle trunk favors successful nerve regeneration and functional recovery extension, which might provide new option for treatment of total BPAI.

105. Functional Outcomes of Nerve Grafting and Triple Nerve Transfers For Upper Trunk Obstetrical Brachial Plexus Injuries

Kathleen O'Grady, MD¹; Hollie Power, MD²; Jaret Olson, MD²; Michael Morhart, MD, FRCSC²; Rob Harrop³; Joe Watt²; K. Ming Chan, MD, FRCPC²

¹Glenrose Rehabilitation Hospital, Edmonton, AB, Canada; ²University of Alberta, Edmonton, AB, Canada; ³University of Calgary, Calgary, AB, Canada

Purpose: Upper trunk obstetrical brachial plexus injury (OBPI) can cause profound shoulder and elbow dysfunction. Neuroma excision with interpositional sural nerve grafting is the current gold standard surgical treatment. However, distal nerve transfers have potential advantages including reduced distance to reinnervation, motor-to-motor coaptation, and shorter recovery time. The goal of this study was to compare the clinical outcomes and healthcare costs between nerve grafting and distal nerve transfers in children with upper trunk OBPI.

Methods: In this prospective cohort study, children who received the triple nerve transfer procedure (spinal accessory to suprascapular nerve, radial to axillary nerve and ulnar to musculocutaneous nerve) were evaluated with the Active movement scale (AMS) at regular intervals for a minimum of 2 years. Their outcomes were compared to children who underwent nerve graft reconstruction. To evaluate healthcare utilization, a direct cost analysis was also performed.

Results: Twelve patients who underwent nerve grafting were compared to 14 patients who underwent triple nerve transfers. Both groups had similar baseline characteristics and showed improved shoulder and elbow function following surgery, with the nerve transfer group displaying significantly better shoulder external rotation (AMS 2 years post-op= 4.3+0.5 (mean+SD) for transfers vs. 2.9+0.6 for graft, $p<0.05$), elbow flexion (6.1+0.5 for transfers vs. 5.5+0.2 for graft, $p<0.05$) and forearm supination (5.6+1.0 for transfers vs. 4.4+0.6 for graft, $p<0.05$) 2 years post-surgery. Nerve transfer donors had no loss of strength post-operatively. The operative time (2h19m+25m vs. 8h15m+1h31m), length of hospital stay (1.1+0.4 vs. 3.4+0.5 days) were significantly lower and overall cost was ~50% less in the nerve transfer group.

Conclusions: Triple nerve transfers for upper trunk OBPI is a feasible option with functional outcomes at least equivalent to that of traditional nerve grafting for shoulder flexion and abduction and faster recovery and better outcomes for shoulder external rotation, elbow flexion and forearm supination. Furthermore, nerve transfers are significantly less expensive than nerve graft reconstruction in this patient population.

106. Assessment of the Psychometric Properties of the Brachial Assessment Tool (BrAT) a New Patient-reported Outcome Measure for Adult Traumatic Brachial Plexus Injury

Bridget Hill, MD¹; Julie Pallant, MD²; Gavin Williams, MD³; Scott Ferris, MD⁴; John Olver, MD³; Andrea Bialocerkowski, MD¹

¹*Menzies Health Institute, Griffith University, Queensland, Australia;* ²*University of Melbourne, Melbourne, Australia;*

³*Epworth Monash Rehabilitation Unit, Melbourne, Australia;* ⁴*Alfred Healthcare, The Alfred, Melbourne, Australia*

Introduction: People with Brachial Plexus Injury (BPI) form a very heterogeneous group, with a wide spectrum of ability to use their affected limb. While a number of patient-reported outcome measures have been used to assess outcome following adult traumatic BPI, none has been psychometrically evaluated for this population. This paper outlines the development of a new BPI specific patient-reported outcome measure, the BrAT, based on the International Classification of Functioning, Disability and Health (ICF) definition of activity.

Method: The development of the BrAT followed a number of steps including:

- Item generation - involving adults with BPI and clinical experts
- Item reduction - using a consensus based approach
- Pilot testing of a 51 item pro-forma by adults with traumatic BPI
- Rasch analysis to determine content validity and unidimensionality. Items were removed in a series of iterations based on misfit to the model, local dependency, targeting to ability, importance and difficulty as determined by people with BPI.
- Classical test theory to determine the psychometric properties of test retest, construct validity and responsiveness

Results: One hundred and six adults with a traumatic BPI completed a 51-item BrAT proforma. Participants mean age was 40 years (range 18-82) and mean time post injury was 121 weeks (range 10 - 740 weeks). Injury severity ranged from pan plexus to those with infraclavicular injury. Items retained represented 16 of the 29 ICF Comprehensive Core Set for Hand Conditions (CCS-HC) activity categories.

Conclusion: Preliminary analysis shows the BrAT to be a unidimensional; targeted patient reported measure of the upper limb following adult traumatic BPI that assess a cross section of day-to-day activity as defined by the CCS-HC.

ASPN Poster Session

P1. Interdisciplinary Treatment of Post-Concussion Headaches

Ivica Ducic, MD, PhD¹; Jeremy C. Sinkin, MD²; Kevin Crutchfield, MD³

¹The George Washington University, McLean, VA; ²Medstar Georgetown University Hospital, Washington, DC; ³LifeBridge Health, Sinai Hospital, Baltimore, MD

Introduction: Chronic headaches following concussion are debilitating and difficult to treat. Most commonly employed therapeutic modalities include pharmacologic, physical, and psychological interventions directed towards concussion itself. While most common residual sequelae of mild brain injuries following any trauma (including sports injuries, falls, hits or car accident) is chronic headaches, presenting itself as occipital, temporal frontal neuralgia or a form of headache, resistant to common medical interventions. Peripheral nerve surgery has never before been reported as an effective long-term treatment for the management of post-concussion headaches.

Methods: A retrospective review of 28 consecutive patients with post-concussion headaches who underwent peripheral nerve surgery was performed. Procedures included occipital, temporal and or frontal nerve decompression; while some patients also required selective nerve excision where direct trauma-destroyed nerves. Sports related injuries including soccer, lacrosse, basketball, and base ball were cause in 70% of patients, MVA 18% and 12 % falls/hits. Pre and post-operative quality of life and the level of headache pain evaluated on visual analog scale (VAS) were done and results compared. Minimal follow up was 14 months.

Results: Bilateral problems were present in 86% of patients; occipital area was involved in 100% of patients, while 60% of patients had temporal and 50% frontal areas involved. The average VAS headache pain reduced from 5.2 preoperatively, to 1.2 ($p < .05$). 19 patients (86%), had at least a 50% reduction in their VAS following peripheral nerve surgery. Thirteen patients (59%) were pain free at time of final follow-up. There were no surgical complications. Patient who failed decompression, were offered nerve excision, thus additional 2/3 of patients who failed decompression were helped. No complications were observed.

Conclusions: Peripheral nerve surgery is certainly not the first treatment choice in post-concussion headache patients. Results presented in this study indicate, nerve surgery should be an important part of the algorithm, although currently not embraced or even considered by many as a treatment choice. Interdisciplinary future studies are needed to further prove on larger patient population its role in sync with medical treatment options.

P2. Benefits of Open Anterior Release of the Superior Transverse Scapular Ligament for Decompression of the Suprascapular Nerve during Brachial Plexus Surgery

Kate Elzinga, MD; Michael Morhart, MD, FRCSC; Jaret Olson, MD, FRCSC,
University of Alberta, Edmonton, AB, Canada

Introduction: The suprascapular nerve (SSN) originates from the upper trunk of the brachial plexus. It is formed by the roots of C5 and C6 at Erb's point and then passes downward beneath the trapezius and through the suprascapular notch to reach its target organs. The SSN provides motor innervation to the supraspinatus and infraspinatus muscles and sensory innervation to the acromioclavicular and glenohumeral joints and shoulder capsule. Entrapment of the SSN can result in loss of abduction and external rotation of the humerus, neurogenic pain, and significant impairment of shoulder function.

Most commonly, SSN decompression is performed via an open posterior approach or arthroscopically. We will describe the benefits of release of the superior transverse scapular ligament at the suprascapular notch through an open anterior approach during brachial plexus reconstruction.

Methods and materials: Reconstruction of the SSN in brachial plexus patients often involves nerve grafting or nerve transfers. To restore shoulder abduction and external rotation, a branch of the spinal accessory nerve is commonly transferred to the SSN. To allow reinnervation of the SSN, any potential compression points should be released to prevent a double crush syndrome. For that reason, the authors perform a release of the superior transverse scapular ligament at the suprascapular notch in all patients undergoing upper trunk reconstruction. Performing the release through a standard infraclavicular brachial plexus approach avoids the need for an additional posterior incision or additional arthroscopic procedure.

Results: The anterior open release of the superior transverse scapular ligament at the suprascapular notch allows decompression of the SSN at this common point of entrapment. The release adds approximately five minutes to the overall surgical time, is well visualized through an infraclavicular approach, and is associated with minimal morbidity. It alleviates the concern of a double crush syndrome following nerve grafting or nerve transfer of the SSN. Following SSN reconstruction, supraspinatus and infraspinatus muscle function, neurogenic pain, and patient quality of life have shown significant improvements.

Conclusions: SSN decompression via the open anterior release of the superior transverse scapular ligament at the suprascapular notch is an important element of upper trunk reconstruction at the time of initial brachial plexus surgery.

P3. Prevention of Above Knee Amputation Stump Neuroma and Reduction of Phantom Pain Risk; Proximal Sciatic Nerve Neurolysis and End-to-End Coaptation with Degradable Nerve Protector

John R. Barbour, MD

Georgetown University, Washington, DC

Introduction: Appropriate management of truncated nerve endings at the time of extremity amputation is critical to prevent painful neuroma formation. Poor outcomes can be attributed to scar formation within the nerve as well as tethering of the nerve to surrounding tissue. While the events are multi-factorial, a common basis for neuroma formation is disorganized growth of axon cylinders into proliferating granulation tissue. This has been shown to be preventable by an epineurial sleeve, implantation into muscle fibers, or neural coaptation to adjacent nerve fascicles. Isolation of a nerve from its surrounding environment may prevent scar ingrowth, minimize potential for nerve entrapment, and reduce the impact of aberrantly regenerating nerve fibers. We present a technique for terminal nerve protection to provide an environment resistant to neuroma formation and potentially reduce the incidence of post-amputation phantom pain.

Materials and Methods: Eight patients requiring initial or revision of above knee amputation underwent neurolysis of the sciatic nerve and coaptation of the peroneal and tibial components in an end-to-end fashion. All patients underwent proximal neurolysis of the sciatic nerve to avoid the area of trauma, and wrapping of the terminal nerve with a degradable nerve protector. Pre-operative and post-operative pain assessments were made on all patients assessing for neuropathic symptoms and signs of phantom limb pain. Patients were followed for a minimum of six months (range 6-23 months).

Results: Standardized pain questionnaires were collected on each patient at the time of most recent follow-up. The mean pre-operative pain score on a 0-10 scale for all patients was $4.8 \pm 1.0/10$, and all patients reported typical neuropathic symptoms (Burning, Stabbing, Tingling) on selected descriptive word associations. Mean post-operative pain scores were all reduced and the average reduction was 3.7 ± 0.7 points. All patients with pre-operative pain reported an immediate reduction and no patients have reported recurrence of the symptoms ($n=8$, mean pain score 1.1 ± 0.3 points) or onset of phantom pain.

Conclusions: Prevention of post-operative neuroma is a major focus for peripheral nerve specialists. End-to-end nerve coaptation is an effective technique for abating neuronal fibrosis and reducing clinical neuroma formation. Engineered nerve protectors are designed to provide an interface between the nerve and the surrounding tissue, mechanically resist compression from surrounding tissue and exclude scar tissue ingrowth. In selected patients considered high risk

P4. Intraneural Ganglion of the Sural Nerve: A Case Report and Systematic Review

Ryckie G. Wade, MBBS, MclinEd; Xueli Jia, PhD, MRCSEd; Philip Robinson, MBChB, FRCR; Ian M. Smith, MSc, FRCS
Leeds General Infirmary, Leeds, United Kingdom

Introduction: Intraneural ganglion of the sural nerve is rare. We report a case, systematically review the literature and highlight the relevance of the articular branch theory in its management

Case Report: A 45-year-old man spontaneously developed a painful mass over the right lateral ankle. He was a healthy non-smoker, with no significant medical, drug or family history. A longitudinally oriented fusiform mass was noted between the Achille's tendon and lateral malleolus. His sural nerve function was clinically intact. An ultrasound scan demonstrated an 8x2x1 cm multiloculated cystic mass within the sural nerve, suggestive of intraneural ganglion and magnetic resonance imaging (MRI) with T2-weighting demonstrated a communication with the ankle joint (Figure 1). At operation, the mass was exposed via a longitudinal epineurotomy and the cyst was enucleated sparing the fascicles (Figure 2). The pedicle of the ganglion accompanying an articular branch of the sural nerve to the talofibular joint was crushed, ligated and divided. Histology confirmed an intraneural ganglion.

Systematic Review: Eight case reports met our inclusion criteria. The most common symptoms of a sural intraneural ganglion was pain and paraesthesia, with a minority reporting antecedent trauma. Ultrasonography can readily diagnose a sural intraneural ganglion. MRI demonstrates the articular nerve branches to the ankle which is hypothesised to carry the pathological tract between the ganglion and synovial joint. Of the eight reported cases, seven intraneural ganglions were surgically excised and one was aspirated under ultrasound guidance. Two excised ganglions recurred after 16 months probably due to incomplete excision of the communicating tract between the joint and ganglion.

Conclusion: Suspected cases of intraneural ganglion require an ultrasound and T2-weighted MRI to delineate the articular branches of the sural nerve. Surgeons should comprehensively excise the ganglion and preserve the nerve where possible. Tracts between the ganglion and ankle joint (which travel with the articular branches) should be crushed, ligated and divided, and the joint capsule ablated in order to reduce the risk of recurrence.

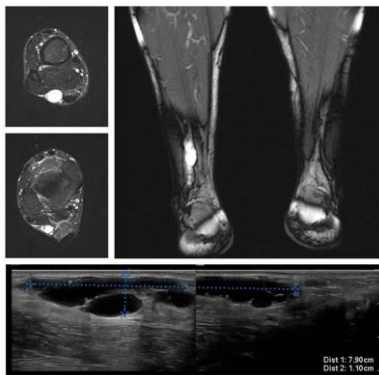


Figure 1. T2 weighted MRIs (upper panel) and ultrasonography (lower panel) of the sural intraneural ganglion.

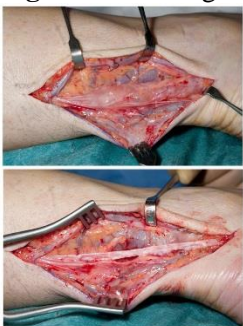

Figure 2. Intraoperative photographs showing the intraneural ganglion and nerve sparing resection.

P5. Application of Schwann Cells in Nerve Conduits for Nerve Defect Repair: Practical and Translational Considerations

Bin Chu, MD¹; Robert J. Spinner, MD²; Michael J. Yaszemski, MD, PhD²; Anthony J. Windebank, MD²; Huan Wang, MD, PhD²

¹Huashan Hospital, Fudan University, Shanghai, China; ²Mayo Clinic, Rochester, MN

Introduction: Nerve conduits have been used as an alternative to autologous nerve graft for repairing nerve defects. Its success has mainly been seen in sensory nerves of shorter gaps. To enhance nerve conduit performance, the microenvironment possessed by a nerve autograft should be reproduced. One such strategy is to supplement the conduit with Schwann cells (SCs). Animal studies have shown SCs facilitate regeneration when applied inside nerve conduits. For clinical use of a combination product, autologous Schwann cells should be used. There are several practical considerations including the source, purity and bioactivity of the cells, and the way these cells are delivered in the conduit. We developed a protocol to expand SCs from sural nerve and compared the yield, purity and bioactivity of these cells to sciatic nerve derived SCs. The suitability of various carriers in delivering SCs was also evaluated.

Methods: SCs were obtained from sural nerve and sciatic nerve of adult Lewis rats using our modified protocol. Cell yield, purity and expressions of P75, S100 and GFAP of sural nerve derived SCs (SuSCs) and sciatic nerve derived SCs (SciSCs) were quantified. Cell bioactivity was determined by PC12 cell/SCs co-culture assay. These parameters were compared between SuSCs and SciSCs. These cells were suspended in Matrigel® (DM), platelet rich plasma (PRP) and fibrin glue (FG), respectively, and loaded into PCLF conduits. Cell survival and proliferation in the conduits were evaluated *ex vivo*. These SCs-filled conduits were used for bridging critical size nerve defect in syngeneic rats.

Results: Cell yield from sciatic nerve was higher than that from sural nerve. Purity of SciSCs and SuSCs were both above 94%. Expressions of P75, S100 and GFAP were comparable for SciSCs and SuSCs. PC12 cell differentiation in SuSCs co-culture and in SciSCs co-culture was similar. For multiple passage cultures, cell purity ranged from 97.2% to 88.6% from P0 to P3. Cell marker expression showed similar trend. Bioactivity did not change significantly. Cell survival was 76.73±2.15% in DM, 73.70±1.53% in PRP, and 74.60±1.87% in FG. Cell doubling time was 4.60±0.35 in DM, 5.04±0.60 in PRP, and 4.77±0.52 in FG. Preliminary *in vivo* data indicated SuSCs had comparable capacity in supporting nerve regeneration as SciSCs.

Conclusions: Culturing SCs from sural nerve can achieve comparable purity, cell marker expression, cell bioactivity and *in vivo* nerve regeneration capacity. PRP and FG are proper media for cell delivery. These are key to the clinical applicability of this strategy.

P6. Brief Electrical Stimulation Promotes Nerve Regeneration Following in-Continuity Nerve Injury

Yuval Shapira, MD; Rajiv Midha, MD, MSc, FRCS(C)

University of Calgary, Calgary, AB, Canada

Introduction: Peripheral nerve injuries are a common cause for life long disability following trauma. Most human nerve injuries leave the nerve in gross continuity although often severe internal tissue disruption occurs resulting in poor functional outcome owing to reduced muscle re-innervation and tainted axon regeneration. A recently developed experimental model for neuroma in continuity (NIC) injuries in rodents allow us to confirm the important detrimental role of axonal attrition and misdirection by demonstrating strong correlations with reduced functional recovery following nerve injuries.

Hypothesis: The therapeutic modality of brief electrical stimulation (ES) will reduce attrition and misdirection of regenerating axons to enhance appropriate functional re-innervation of motor end-organs and thereby promote behavioral recovery in a rodent NIC injury.

Methods: Inbred Lewis rats were randomly assigned to one of four groups: NIC injury immediately followed by brief ES; NIC injury without applying ES (sham stimulation); sham-operated controls with nerve exposure, neurolysis and no NIC injury; sciatic nerve transection and capping with no repair. Brief ES (1 hour at 20 Hz, 0.1 msec duration, 3V intensity), sufficient to result in antidromically conducted action potentials, was applied immediately proximal to a sciatic nerve NIC injury in the 1st group. Outcome measurements included serial behavior evaluation (ladder rung test) and compound muscle action potentials (CMAP) and terminal retrograde spinal cord motor neuron labeling and histo-morphological analysis for axonal regeneration.

Results: Applying brief ES after NIC injury resulted in earlier recovery and significantly improved locomotion function at 4 and 6 weeks. At 8 weeks, brief ES resulted in higher CMAP amplitude ratio compared with NIC injury without stimulation. By 12 weeks there was no significant difference between the two groups in behavior function or electrophysiological tests. Histomorphological analysis reveals no significant difference although a trend to higher percentage of neuronal tissue was demonstrated in the brief ES group. Counts of retrogradely motor neuron labeling from spinal cord is ongoing to assess for axonal attrition and misdirection of motor neurons.

Conclusion: Application of brief ES for in-continuity nerve injury promotes faster recovery, akin to the effects seen with brief ES with complete transaction nerve injury and nerve repair. The findings support a potentially broader clinical application of this therapeutic modality. A RCT in humans has demonstrated that patients with severe carpal tunnel and decompression have improved motor unit recovery when given brief ES compared to sham stimulation.

P7. The Result of Treatment of Thoracic Outlet Syndrome

Yoonbae Kong, MBBS; Seok-Hwan Song, PhD; Yoon-Min Lee, MS
Yeouido St. Mary Hospital, Seoul, South Korea

Introduction: As clinical manifestations of thoracic outlet syndrome are vague upper extremity pain or symptoms, the diagnosis is often delayed or misdiagnosed as cervical HNP, shoulder pathologies or peripheral neuropathy. In that reason, many patients spend time for unnecessary or in vain treatments. There are no definite guideline of treatment when to perform surgery or how long sustain conservative care. We report the results of thoracic outlet syndrome treated by conservative care or surgical treatment.

Materials & Methods: Twenty cases diagnosed as thoracic outlet syndrome were review retrospectively since 1999. Light exercises of upper extremity such as stretching of neck and shoulders or athletic good without weight were recommended at initial visit. Surgical method included resection of anterior and middle scalene muscles, and neurolysis of brachial plexus. As the case of cervical rib syndrome, resection of cervical spine was performed also. Nine patients were performed surgery and the others had conservative treatment in outpatient clinic. Postoperative improvement of symptoms and the follow up period, and the results of conservative treatment with exercise or medication were reviewed.

Results: The average age was 43 years. Nine patients with surgical treatment were improved nearly normal status within 6.5 months (range 2-21 months) after surgery. Two patients complained mild discomfort of involved upper extremity and others had no complications. Reoperation was unnecessary in all cases. Among eleven patients treated by conservative methods, seven patients were free of symptoms just by light exercise of shoulder and neck, and four patients had sustained symptoms with mild improvement.

Conclusion: Thoracic outlet syndrome is sometimes difficult to diagnose due to vague symptoms. But if the diagnosis is confirmed by careful physical examination, radiologic studies or nerve conduction studies, doctors can recommend conservative care and after two or three months later, reassess the patients condition. According to the results of conservative treatment, surgical treatment could be considered. When surgical treatment is performed, complete exploration of brachial plexus is essential and resection of anterior and middle scalene muscle is really helpful for successful results. And other pathologic lesions such as cervical rib or atypical compressive structures must be removed for complete decompression of brachial plexus. By this treatment policy for thoracic outlet syndrome, patients meet with good clinical results.

P8. Application of Epineural Sheath Conduit Supported with Bone Marrow Stromal Cells for Peripheral Nerve Regeneration and Prevention of Denervation Atrophy in Diabetic Rat Model

Mirosław Lukaszuk, MD¹; Joanna Cwykiel, MSc²; Maria Siemionow, MD, PhD, DSc²

¹*Plastic Surgery, Cleveland Clinic, Cleveland, OH;* ²*University of Illinois at Chicago, Chicago, IL*

Background: Untreated diabetes leads to development of multiple complications, including diabetic neuropathy. Nerve regeneration in diabetic patients remains a clinical challenge, considering a constant negative impact of diabetic hyperglycemia on the tissue healing. This study aimed to assess the effect of rat epineural sheath conduit (rESC) supported with bone marrow stromal cells (BMSC) on neuropathic nerve regeneration and denervation atrophy in a diabetic rat model.

Methods: In this study, fifty-eight Zucker Diabetic Fatty (ZDF) rats were used with inclusion criteria for established diabetes: casual glycemia >200 mg/dl (twice) and post-fasting glycemia >110 mg/dl. A 20mm sciatic nerve defect was created and rats were divided into 4 groups: Group 1- no repair (n=10), Group 2- nerve autograft (n=16), Group 3- rESC filled with saline (n=16), Group 4- rESC supported with isogenic rat bone marrow stromal cells (4×10^6 /injection; n=16). Nerve regeneration assessments included pinprick and toe-spread tests performed at 3-week intervals and somatosensory evoked potentials (SSEP) at 6 and 12 weeks post-op. Nerve samples were harvested at 6 and 12 weeks for immunohistochemistry and histomorphometric analysis. Muscle denervation atrophy was assessed by Gastrocnemius Muscle Index (GMI) and micromorphometry (mean fiber area index, MFA).

Results: Sciatic nerves repaired with rESC showed significantly improved recovery of the sensory and motor function compared to the controls. At 6 weeks nerve latencies were comparable in Groups 3 and 4. At 12 weeks, latency in Group 3 was shorter compared to the autograft control group. The expression of S-100 and the presence of parallel myelinated nerve fibers inside the rESC at 6 and 12 weeks post-op were confirmed. The presence of BMSC in the rESC, observed at 6 weeks post-op was associated with better functional tests scores. GMI and MFA indices showed significant difference in the muscle atrophy with the strongest atrophy in no-repair group and the mildest in the autograft group. Repair with rESC prevented the development of muscle atrophy comparable to the standard method of repair and resulted in increased muscle reinnervation by 12% according to the weight and by 42% with respect to MFA assessment.

Conclusions: We confirmed, that repair of nerve gaps in the diabetic rats using rESC, resulted in functional outcomes comparable with standard autologous method of nerve repair. Application of rESC combined with the BMSC in the repair of 20mm sciatic nerve defect in diabetic conditions reduced muscle denervation atrophy, which was comparable to the autograft control.

P9. Role of Epineurium on Neuroma Formation

Bilge Kagan Aysal, MD¹; Huseyin Karagoz, MD, PhD¹; Cihan Sahin, MD¹; Fikret Eren, MD¹; Bora Ozel, MD¹; Gizem Narli, MD¹; Zafer Kucukodaci, MD¹; Erdal Karaoz, PhD²

¹*Gulhane Military Medical Academy, Haydarpaşa Training Hospital, Istanbul, Turkey;* ²*Regenerative Medicine and Stem Cell Research Center, LIV Hospital, Istanbul, Turkey*

Neuroma is a painful and tender mass on a nerve ending after peripheral nerve injury. Many studies have been conducted to prevent neuroma and studies focus on epineural layer of the peripheral nerve in recent years. However, there is confusion about role of epineurium to prevent neuroma because although most of the studies reported successful results using epineural barrier, some other studies reported good results with removing the epineurium. We aimed to investigate the role of epineurium on the neuroma formation.

Fifty-five Sprague-Dawley rats were divided into 5 groups, each containing 11 rats. In all groups, 20 mm sciatic nerve defect was created. Experimental groups were included 1) negative control: proximal nerve stump was left “free” following transection, 2) positive control: the proximal nerve stump was implanted into the adjacent muscle (gold standard treatment method in clinical practice), 3) epineural ligation: epineurium of the proximal stump was ligated after trimming 5mm long axons, 4) epineural stripping: epineurium of the 5mm long proximal nerve stump was removed with stripping, and 5) epineural capping: proximal stump was strictly capped with epineural graft which had been harvested from excised nerve segment.

After the 6 months follow-up period, tissue samples were taken from the nerve endings. Histopathological and immunohistochemical (staining with S-100 and calcitonin gene related peptide (CGRP) antibody) examinations were conducted for the assessment. Gene expressions of ciliary neurotrophic factor and CGRP receptor component protein were analyzed with real time PCR. The outcomes were compared after statistical analysis.

Different amount of neuroma formations were observed in all groups. There was no difference between the positive and negative control groups. Best results were obtained in ligation group. Both of ligation and stripping of the epineurium were found as effective to prevent neuroma formation, and these two groups revealed better results than controls. However, pain parameters of the stripping group were as high as control groups. Most apparent neuroma formation was observed in the capping group.

One of the interesting results of the study is that muscle implantation of the nerve isn't protective in terms of neuroma formation; however muscle can be protective against external physical trauma as a cushion and can prevent pain. Epineurium may have a preventive role for neuroma formation, however strictly suturing of the epineural graft to the nerve end is concluded to increase the neuroma formation rather than preventing.

P10. Chronic Electrical Muscle Stimulation (EMS) Following Nerve Injury and Repair Does Not Diminish Synkinetic Reinnervation

Michael P. Willand, PhD¹; Joseph Catapano, MD²; Tessa Gordon, PhD¹; Gregory H. Borschel, MD¹

¹The Hospital for Sick Children, Toronto, ON, Canada; ²University of Toronto, Toronto, ON, Canada

Introduction: Functional recovery after surgical repair of transected nerves is reduced when axon growth is misdirected to reinnervate muscles other than their original targets. Canine models of laryngeal nerve transection injury have suggested that EMS following injury promotes reinnervation of original targets. However, these conclusions were based on functional measurements and there remains no direct evidence that EMS improves muscle reinnervation by the original motoneurons. In this study, we investigated whether EMS using a natural activation pattern increases the number of motoneurons regenerating to reinnervate their original target muscle.

Methods: Prior to injury, the right soleus muscle in two groups of Sprague Dawley rats were injected with True Blue (TB) tracer to label the original soleus motoneurons in the spinal cord. One week later, the right lateral gastrocnemius soleus (LGS) nerve was transected, immediately repaired, and the soleus muscle was implanted with intramuscular electrodes attached to an implanted mini-stimulator. In one group, the denervated soleus muscle was subjected to EMS with a paradigm mimicking the natural activation of the muscle: 12 hours (h) of continuous daily EMS at 20 Hz (10 seconds on, 20 sec off) followed by 12 h of intermittent EMS (10 sec on, 1 h off). Two months after the injury, the right soleus nerve was retrograde labelled with FluoroRuby (FR) just proximal to the soleus muscle to label the motoneurons that had regenerated axons into the soleus nerve. The motoneurons of the contralateral uninjured lateral gastrocnemius and soleus muscle were labelled with TB and FR respectively to compare the spatial distribution of the contralateral motoneuron pool with the injured side. The soleus nerve was also harvested for histomorphometric analysis.

Results: Intramuscular injection of the soleus muscle resulted in a labeling efficiency of 75% of the uninjured contralateral side, which was labeled using the gold standard well technique. Double labeled motoneurons, representing motoneurons that originally innervated the soleus muscle, were no different between groups (EMS: 10.9±2.3% vs Sham: 15.5±9.9%). Visualizing 3D spatial distributions of labeled neurons in both groups indicated that more axons originated from the LG motoneuron pool, concomitant with a motoneuron pool 3x larger than the soleus pool. Histomorphometric axon counts (EMS: 200±68 vs Sham: 163±47) and fiber diameters were no different between groups.

Conclusions: While our previous work supports the use of EMS to reduce muscle atrophy, our experimental model does not support the use of EMS to counteract misdirection occurring with nerve regeneration.

P11. Neuropathological Characteristics of Brachial Plexus Avulsion Injury With and Without Concomitant Spinal Cord Injury

Zarina S. Ali, MD¹; Victoria E. Johnson, MBChB, PhD¹; William Stewart, MBChB, PhD²; Eric L. Zager, MD¹; Gregory G. Heuer, MD, PhD¹; Maura T. Weber, BA¹; Arka Mallela, MS¹; Douglas H. Smith, MD¹

¹*University of Pennsylvania, Philadelphia, PA;* ²*The University of Glasgow, Glasgow, United Kingdom*

Neonatal brachial plexus injury (BPI) most commonly occurs as a result of birth trauma and can result in significant lifetime morbidity. In the case of avulsion injury, therapeutic options are limited, in part, since little is known regarding the acute and evolving neuropathological processes it induces. In particular, direct damage to the spinal cord frequently occurs secondary to the mechanical forces associated with avulsion, and may independently contribute to neuropathological and clinical outcomes. Here, we describe the neuropathological changes that may drive the clinical sequelae of upper trunk avulsion injury with or without concomitant spinal cord injury in a novel pediatric porcine model. Twenty-eight day old piglets underwent unilateral C5, C6 and C7 nerve root avulsion or avulsion with limited myelotomy on the right side. Functional assessment was performed over 6 weeks post-injury, followed by detailed histopathological analysis of the spinal cord, nerve roots, and associated skeletal muscle. Following avulsion, all animals demonstrated right forelimb monoparesis. However, the addition of concomitant spinal cord injury conferred greater motor neurological deficit, manifest as deficits in the long tracts, including hindlimb weakness. Consistent with clinical observations, avulsion with myelotomy resulted in a more severe histopathological phenotype, with a complex neuropathology including greater motor neuron death, progressive axonopathy, and florid and persistent glial activation. Taken together, these data demonstrate the neuropathological features of nerve root avulsion injury that may account for poor functional outcome. Interestingly, in marked contrast to adult, small animal models of avulsion, even following the most severe neonatal BPI in this piglet model, there was a degree of motor neuron survival in the relevant cord levels. Notably, if this observation is also true of human neonatal BPI, repair of the avulsion might permit restoration of function. In addition, this model provides a clinically relevant platform for further examination of the complex temporal course of inflammatory and glial responses post-avulsion and may inform potential therapeutic strategies for neonatal BPI over a substantial window of opportunity.

P12. Motor Nerve to the Masseter: A Pediatric Anatomic Study

Neil Sachanandani, MD¹; Gregory Borschel, MD²; Ronald Zuker, MD²; Alison Snyder-Warwick, MD¹

¹University School of Medicine, Saint Louis, MO; ²The Hospital for Sick Children, Toronto, ON, Canada

Introduction: The masseteric nerve provides a robust local neural source for facial reanimation procedures. The intraoperative identification of this nerve has been facilitated by the consistency of its anatomic location in adult patients. The purpose of our study is to determine the location of the masseteric nerve in the pediatric population using surgical landmarks.

Materials and Methods: Intraoperative measurements of the anatomic location of the masseteric nerve were performed prospectively in pediatric patients undergoing facial reanimation from June 2014 to June 2015. Patient age and the three dimensional location of the masseteric nerve were recorded. The distances of the nerve anterior to the tragus and inferior from the inferior aspect of the zygomatic arch were measured. The nerve depth was measured from the superficial muscular aponeurotic system (SMAS).

Results: The mean age of the children in our sample was 10.59 years (range: 4.43 to 16.92 years old). The anterior distance in relation to the tragus was $2.98 \pm .07$ cm. The inferior position in relation to the zygomatic arch was $1.02 \pm .06$ cm. The depth from the SMAS was 1.35 ± 0.1 cm.

Conclusions: The position of the masseteric nerve in relation to fixed surgical landmarks is similar to that of previously established findings in the adult population. The finding of 3 cm anterior to the tragus and 1 cm inferior to the zygomatic arch holds true in the pediatric population. This information aids intraoperative nerve identification in the pediatric population.

P13. Enhancement of Nerve Regeneration After Delayed Repair With Controlled Release of Neurotrophic Factors

Kasra Tajdaran, MASc¹; Matthew D. Wood, PhD²; Molly Shoichet, PhD¹; Tessa Gordon, PhD³; Gregory H. Borschel, MD³
¹University of Toronto, Toronto, ON, Canada; ²Washington University School of Medicine, Saint Louis, MO; ³The Hospital for Sick Children, Toronto, ON, Canada

Purpose: Peripheral nerve injuries frequently lead to functional and sensory dysfunction. Delays in surgical repair following nerve transection reduce axonal regeneration, which is in part, due to reduced neurotrophic support. Previously, local application of exogenous neurotrophic factors, including glial cell line derived neurotrophic factor (GDNF) was shown to have a positive effect on axon regeneration after delayed repair. Here we investigated a novel delivery system for GDNF following delayed repair using drug-loaded poly(lactic-co-glycolic acid) (PLGA) microspheres (MSs) embedded in a fibrin gel, which serves to localize the MSs around the nerve injury site and allows sustained GDNF release.

Methods: The characteristics of the drug delivery system including its biocompatibility and GDNF release profile were studied with cell toxicity assays and ELISA. The toxicity assay was performed by incubating PC-12 cells with the media released from PLGA MSs *in vitro*. A delayed nerve repair model was used in which the rat common peroneal (CP) nerve was transected and regeneration was prevented by ligation for two months. Thereafter, the CP nerve stumps were coapted. The three experimental groups were implanted with GDNF-containing MSs, free GDNF or empty MSs in fibrin gel, at the repair site. In a positive control group, the CP nerve was coapted immediately after transection. Four weeks after repair, the numbers of neurons that regenerated their axons were determined using retrograde labeling 15 mm distal to the repair site.

Results: Using ELISA, GDNF release from MSs was detected over 14 days *in vitro*. PC-12 cells incubated *in vitro* with released media samples from the drug delivery system had similar viability to control cells cultured with normal media demonstrating that the drug delivery system was not toxic. Consistent with this, the numbers of motor and sensory neurons that regenerated their axons *in vivo* was the same as when there was no treatment with microspheres. The numbers of regenerating neurons increased when GDNF was administered in fibrin gel, but this increase was not significant. In contrast, GDNF administered within microspheres increased the numbers significantly, almost to those after immediate nerve repair.

Conclusion: Addressing the deleterious effects of delayed repair holds promise for removing one of the major barriers to improve nerve regeneration. GDNF microspheres incorporated into fibrin gels was able to double the number of regenerated motor and sensory neurons as compared to the control groups after delayed nerve repair. They offer a potential treatment of chronic peripheral nerve injuries.

P14. Evaluation of a Surgical Technique to Rapidly Restore Axonal Continuity using High-Resolution DTI

David Colton Riley, BS; Ravinder Bamba; Nathaniel Kelm; Bruce Shack, MD; Wesley P. Thayer, MD, PhD
Vanderbilt University, Nashville, TN

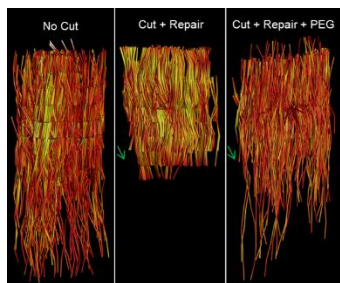
Hypothesis: Polyethylene glycol (PEG) restores axonal continuity following neurotmesis.

Methods: The objective of this study was to evaluate the efficacy of PEG-fusion using DTI parameters, including fractional anisotropy (FA), diffusion tensor tractography (DTT), and principle diffusion vectors for three groups: unoperated control (nocut; n=4), negative control (cut+repair; n=4), and PEG treated (cut+repair+PEG; n=4). The left sciatic nerves of female porcine (Yorkshire) were completely transected and repaired using standard microsurgical techniques. Following repair, PEG was injected into the neurotomy; negative controls did not receive PEG. Nerves were immediately excised and placed in fixative. Image data reconstruction and diffusion tensor calculations were performed using in-house written code in MATLAB. DTI metrics including FA, mean, axial, and radial diffusivity were computed on a voxel-wise bases.

Results: Following 100% transection of porcine sciatic nerve, we report that PEG immediately (within minutes) restores axonal continuity as assessed by high-resolution DTI. FA was significantly decreased at the site of injury in both PEG and negative control groups compared to unoperated controls ($p < 0.01$). The drop in FA at the zone of injury indicates a loss in axonal continuity. However, PEG treated nerves were associated with a statistically significant increase in FA ($p < 0.05$) at the site of injury compared to negative controls. Additionally, PEG treated nerves demonstrated a significant increase in the number of DTI tracts that traveled through the zone of injury compared to negative controls, however PEG treated nerves were associated with a significant decrease in the number of tracts compared to un-operated control nerves. While an increase in FA and DTI tracts at the site of injury compared to negative controls indicate that PEG successfully restores axonal continuity, the decrease in FA and DTI tracts compared to unoperated controls suggest that PEG does not restore continuity to all axons. Principle diffusion vectors in negative control animals appeared more homogenous at the zone of injury compared to PEG treated. However, in unoperated control nerves, principle diffusion vectors were homogeneous throughout.

Conclusion: Here we present findings that the introduction of PEG into the neurotomy rapidly restores axonal continuity. Furthermore, the aforementioned data suggest that high-resolution DTI is capable of detecting acute peripheral nerve injuries. Taken together, our findings suggest that PEG fusion and DTI might produce a paradigm shift in the clinical management and treatment of traumatic injuries to peripheral nerves.

Figure 1 - Representative tractography of nerves harvested immediately following repair for: no cut, cut+repair, and PEG treated groups.



P15. Clinical Utility and Accuracy of High-Resolution Ultrasonography in the Diagnosis of Peripheral Nerve Lesions

Gabriel Beauchemin, MD; Johan Michaud, MD; Jenny C. Lin, MD, PhD

University of Montreal, Montreal, QC, Canada

High-resolution ultrasonography of peripheral nerves is a promising new imaging modality for the investigation and diagnosis of peripheral nerve lesions such as tumors or injuries by compression or trauma. Advantages of this technique over other modalities such as magnetic resonance imaging or CT-scanning include the ability to distinguish and follow individual nerve fascicles as well as the ability to dynamically examine a long segment of the affected nerve. The ultrasonographer can compare the affected side with the unaffected side, and orthopedic material will not cause artifacts in the images. Ultrasounds are less expensive and more accessible than MRI, and are very well tolerated by patients. In our centre, high-resolution ultrasonography has become an important tool in the diagnosis of peripheral nerve lesions and also for pre-operative planning. In this study, we have correlated the intraoperative findings of patients with peripheral nerve lesions with the reported findings on pre-operative high-resolution ultrasonography. These were compared with the reported findings on pre-operative MRI when available. In total, 33 patients who had a pre-operative high-resolution ultrasound were included in the study. The overall correlation of intraoperative findings with the reported abnormalities identified by high-resolution ultrasound was excellent. The nerve lesions characterized by high-resolution ultrasound include schwannomas, intraneural cysts, traumatic neuromas, neuromas-in-continuity and nerve compressions. Affected nerves include the median, ulnar and radial nerves, posterior and anterior interosseous nerves, femoral, posterior tibial and common peroneal nerves. Ultrasound images and corresponding intra-operative photographs will be presented, as well as our indications for high-resolution nerve ultrasound in the diagnosis of peripheral nerve lesions.

P16. The Effect of Size Discrepancy of Human Epineural Conduit on the Functional Outcomes of Nerve Regeneration in Athymic Nude Rat Model. A Preliminary Report

Marcin Strojny, MD; Rafal Gendek, MD, PhD; Joanna Cwykiel, MSc; Erzsebet Szilagyi, MD, PhD; Malgorzata Cyran, MD; Wojciech Malewski, MD; Huseyin Karagoz, MD, PhD; Maria Siemionow, MD, PhD, DSc

University of Illinois at Chicago, Chicago, IL

Introduction: Nerve autograft is a gold standard in peripheral nerve regeneration. However, it presents drawbacks, such as limited availability, donor site morbidity and scarring. Nerve allografts provide an unlimited source of nerve tissue, which can be matched to the recipient's injured nerve to support nerve recovery. This study aimed to assess the effect of **human Epineural Sheath Conduit (hESC) adjusted with tissue adhesive or suture** on restoration of 20mm long nerve defect in an athymic nude rat model.

Methods: The size ratio between human and a rat sciatic nerve is 10:1. Restoration of 20mm of nude rat sciatic nerve defect with hESC filled with saline was performed in 5 groups: Group 1: autograft controls (n=4), Group 2: mismatched size diameter hESC (n=2), Group 3: hESC with diameter adjusted with tissue adhesive (n=4), Group 4: hESC with diameter adjusted with nylon 10-0 suture (n=2), and Group 5: matched diameter hESC (n=4). hESC was created from human sciatic nerve and its 1-2mm branches (Group 5). Toe-spread and pinprick analyses were performed at 1, 3, 6, 9, 12 weeks post-op. At 12 weeks follow-up, nerve samples were collected for immunohistochemistry. Muscle denervation atrophy was assessed by Gastrocnemius Muscle Index (GMI). Samples for toluidyne blue staining and for fluorescent immunostaining for GFAP, NGF, S-100, laminin B, CD3 and CD4 were harvested at 12 weeks post-surgery.

Results: Macroscopic evaluation of nerve conduits at 12 weeks showed no tissue adhesion or local signs of inflammation and good vascularization in all groups. Additionally, the shape and integrity of the conduit were preserved. The best sensory and motor recovery following hESC application was observed in groups with hESC diameter adjusted with tissue adhesive (Group 3) and matched diameter hESC (Group 5), pinprick 1.75 and 1.75; toe-spread 0.5 and 0.75, respectively. hESC without diameter adjustment (Group 2) and hESC adjusted with sutures (Group 4) showed the worst regeneration. GMI measurements were the highest for autograft group (Group 1–0.35) followed by matched diameter hESC (Group 5–0.32) and hESC adjusted with tissue adhesive (Group 3–0.277). Toluidyne blue and immunofluorescent staining are currently under evaluation.

Conclusions: We confirmed the feasibility of hESC creation and diameter adjustment using different techniques. hESC conduit with adjusted diameter using tissue adhesive showed sensory and motor recovery comparable to hESC conduit with matched diameter to the rat sciatic nerve. Our new hESC conduit provides an alternative option to the autograft nerve gap repair.

P17. Intra-neural Ganglion Cysts: A Systematic Review and Reinterpretation of the World's Literature

Nicholas M. Desy, MD¹; Huan Wang, MD, PhD¹; Mohanad A. Ibrahim Elshiekh, MD²; Shota Tanaka, MD³; Tae Woong Choi, MD⁴; B. Matthew Howe, MD¹; Robert J. Spinner, MD¹

¹Mayo Clinic, Rochester, MN; ²New York Methodist Hospital, Brooklyn, NY; ³The University of Tokyo, Tokyo, Japan; ⁴Korea University Anam Hospital, Seoul, South Korea,

Introduction: The etiology of intra-neural ganglion cysts has been controversial. In recent years, substantial evidence has been presented to support the articular (synovial) theory for their pathogenesis. We sought to (1) perform a systematic review of the world's literature on intra-neural cysts; and (2) reinterpret available published MRIs by other authors to identify unrecognized joint connections.

Materials and Methods: In part 1, all cases were analyzed for demographic data, duration of symptoms, the presence of a history of trauma, whether an EMG or NCS was performed, the type of imaging, surgical treatment, presence of a joint connection, intra-neural cyst recurrence and postoperative imaging. Two univariate analyses were completed: (1) to compare the proportion of intra-neural ganglion cyst publications per decade and (2) to assess the number of recurrences from 1914 to 2003 compared to the years 2004 to 2015. Three multivariate regression models were used to identify risk factors for intra-neural cyst recurrence. In part 2, we analyzed all available published MRIs and obtained MRIs of selected cases in which joint connections were not identified by the original authors, specifically looking for unrecognized joint connections. Two univariate analyses were done: (1) to determine a possible association between the identification of a joint connection and obtaining an MRI and (2) to assess the number of joint connections reported from 1914 to 2003 compared to 2004 to 2015.

Results: In part 1, 417 articles (645 patients) were selected for analysis. Joint connections were identified in 313 intra-neural cysts (48%). Both intra-neural ganglion cyst cases and cyst recurrences were more frequently reported since 2004, both of which were statistically significant. Percutaneous aspiration as well as failure to disconnect the articular branch or address the joint was statistically significant for cyst recurrence. In part 2, we identified 43 examples of joint connections that initially went unrecognized: 27 based on our retrospective MRI reinterpretation of published cases and 16 of 16 cases from our sampling of original MRIs of published cases. Overall, joint connections were more commonly found in patients who received an MRI and were more frequently reported during the years 2004 to 2015, both of which were statistically significant.

Conclusions: This comprehensive review of the world's literature and the MRIs further supports the articular (synovial) theory and provides baseline data for future investigators.

P18. Carpal Tunnel Syndrome and Open Median Nerve Decompression: Innervation and Vascularisation of the Fat Tissue Overlying the Carpal Ligament and Consequences for Surgical Handling

Ildefonso Muñoz Romero, MD¹; Robert Notenboom, MD, PhD²; Willem Pondaag, MD, PhD²; Martijn Malessy, MD, PhD²
¹Neurological Center at the American British Cowdray Medical Center, Mexico, Mexico; ²Leiden University Medical Center, Leiden, Netherlands

Introduction: During open carpal tunnel surgery (OCTS), we noted the presence of fat tissue between the palmar aponeurosis and the transverse carpal ligament (TCL). This fat can be easily damaged during exposition of the TCL. Whether it plays a role in the aetiology of postoperative OCTS pain is unknown.

Methods: A microanatomical dissection of the carpal tunnel region was performed in ten embalmed cadaver arms. Tissue samples of the fat tissue between the palmar aponeurosis and the TCL were immune-histochemically characterized. A panel of antibodies against calcitonin gene-related peptide, vaso-intestinal peptide and substance P was used to discriminate between afferent and efferent nerve fibers. Three-dimensional reconstructions were made by computer-assisted microscopy from sections immunostained for S-100 protein to determine the nerve distribution pattern.

Results: Our anatomical dissections showed that a distinct fatty structure under the palmar aponeurosis is overlying the TCL loosely attached to it. This fat pad is a separate structure, which is different from the subcutaneous fat and is a continuation of the fat overlying the roof of Guyons canal. The blood supply of the fat pad originates solely from the ulnar artery and consists of one to four branches. The innervation comes from the palmar branch of the ulnar nerve. This branch exits the ulnar nerve between 2 to 20 cm proximal to the fat pad and runs in the ulnar artery's sheath. The palmar branch gives off numerous small branches to the base of the fat pad at the level of the pisiform bone. The loose relation to the TCL and the vascularisation and innervation from the ulnar side allows easy mobilisation from radial to ulnar over the TCL without jeopardizing its integrity. The fat pad showed an abundant number of substance P positive Pacini corpuscles.

Conclusion: The fat tissue between the palmar aponeurosis and the TCL is a distinct anatomical entity. It is innervated by the palmar cutaneous branch of the ulnar nerve and vascularized by the ulnar artery. We hypothesize that this fat pad serves as a soft cushion, which also allows sliding movements between the palmar aponeurosis and the TCL. Its rich neural innervation reflects an important role in proprioception, somatic sensation of the wrist and pain perception. Mobilisation of the fat pad at the radial side during OCTS will preserve its integrity and might reduce postoperative OCTS pain.

P19. Learning Peripheral Nerve Surgery: Assessment of Educational Video Content with Use-Pattern Analytics and User Surveys

Amanda M. Gryniewicz, MS; Andrew Yee, BS; Elspeth Hill, MD, MRes, PhD; Susan E. Mackinnon, MD; Ida K. Fox, MD
Washington University School of Medicine, Saint Louis, MO

Purpose: While online surgical educational strategies continue to gain in popularity, little attention has been paid to use patterns, user preferences or quality assurance. In the past five years, we have produced over 100 educational videos that include over 40 technical surgical case modules. The purpose of this study was to investigate how this video content is accessed and used and to begin to define its clinical utility and impact.

Methods: Online video analytics were compiled from three video platforms (YouTube, Vimeo, vumedi) that were used to host the video content. Statistical reports include information on demographics, usage patterns, and popular content trends. Institutional human studies review board permission was obtained and an online survey was distributed to current video module users. This survey evaluated the utility and impact of the video content. Questions focused on user perceptions of the impact of the surgical videos on their own practice. Information on self-identified improvement in technical competency, decreased operative time, amongst other metrics. Finally, participants were asked whether they were able to successfully implement an unfamiliar procedure into their practice after reviewing the available video content.

Results: Preliminary viewing analytics reported over 1.7 million total video views worldwide with over 200,000 of these by medical professionals. International users accounted for 70% of video viewing traffic with 59% of that from underdeveloped countries with densely populated cities and a high prevalence of traumatic nerve injuries. Individual users (as identified by unique IP address access) initially viewed the videos that show an entire surgical procedure; they later shifted to more abbreviated viewing patterns. Survey results are pending. Preliminary data include significant free text reports documenting the effectiveness of the surgical video modules including surgeons' self-reported ability to incorporate new techniques into their surgical armamentarium after simply watching the available content.

Conclusion: Video education is becoming mainstream for surgical training as adoption of new camera technologies becomes easier. We present our video analytics and user survey results as the first-step towards describing the benefits of video education in surgical training and continuing education as compared to traditional learning methods for case preparation.

P20. Screening the Diabetic for Polyneuropathy. Results from the Rotterdam Diabetic Foot Study

Willem D. Rinkel, MD; Johan W. van Neck, PhD; J. Henk Coert, MD, PhD

Erasmus Medical University Center, St. Franciscus Gasthuis, Rotterdam, Netherlands

Introduction: We analysed baseline measurements of diabetics included in a cohort to study the deterioration of sensation of the feet, over time. Diabetic sensorimotor polyneuropathy (DSP) is formulated as the inability to sense the 10 g monofilament, having an altered vibration threshold and/or having complaints of burning, aching, tingling or numbness. We believe that an elevated cutaneous threshold is the greatest risk factor, which is preceded by positive symptoms and a loss of two-point discrimination. The aim of this study is to assess how the commonly used instruments estimate the existence of DSP, the most important risk factor for foot ulceration.

Methods: We assessed the sensation of 826 feet, with each instrument examining different nerve fibres. The Rydel-Seiffer tuning fork detects the vibration threshold on two sites of both feet (dorsal distal hallux and medial malleolus), cutaneous threshold (one point static discrimination (S1PD) on five locations of the foot with monofilaments ranging from 0,008 – 300 grams. The test sites (pulp of first and 5th toe, medial heel (above callus), first web and lateral foot) were chosen corresponding to the nerve distribution of the foot. Subjective neuropathy complaints were assessed via the Michigan Neuropathy Screening Instrument (MNSI).

Results: Screening on 5 sites per foot (S1PD (≥ 10 g)), resulted in a prevalence of DSP of 7% (left) and 7,2% (right) in our population. When only one test location is assessed for a pathological cutaneous threshold, the prevalence of DSP ranges from 11,3 to 22,6%. We detect a lower cutaneous threshold at the lateral foot and first web. When we choose a tuning fork to detect DSP, age corrected vibration thresholds results in a prevalence of 39,2% (left) or 42,1% (right). 20% of patients scoring DSP on the MNSI, did not have elevated cutaneous thresholds of the hallux on both feet.

Conclusion: In general, the deterioration of sensation of the feet is distributed evenly between the left and right feet in the population studied, when comparing the cutaneous- and/or vibration threshold. Different screening instruments give different estimates of DSP. Not surprising regarding the different fibres they test. We advocate seeing these different instruments as detectors of different stages of DSP.

AAHS #1 Proximal Interphalangeal Arthroplasty for Osteoarthritis; a Comparison of Silicone, Pyrocarbon and Surface Replacing Arthroplasty

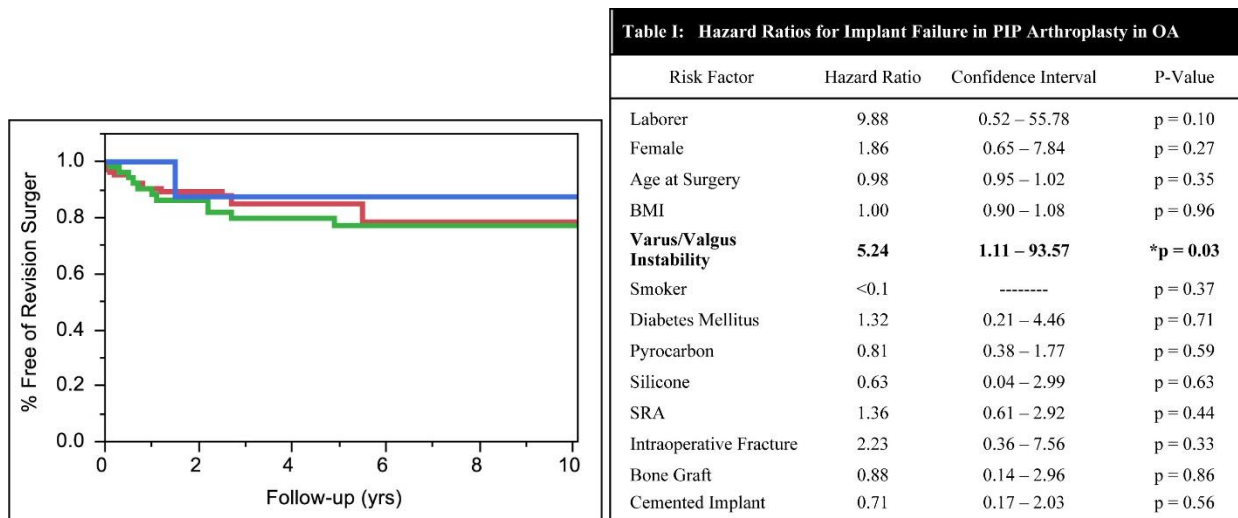
Eric Wagner, MD; John Weston, MD; Matthew Houdek, MD; Steven L. Moran, MD; Marco Rizzo, MD
 Mayo Clinic, Rochester, MN

Hypothesis: Despite the increasing prevalence osteoarthritis (OA), the surgical treatment options for proximal interphalangeal (PIP) joint OA remain arthroplasty and arthrodesis. The purpose of this investigation was to evaluate the results PIP arthroplasty in patients with OA, comparing the outcomes of 3 different implants examining survivorship, patient-related factors and clinical outcomes.

Methods: We performed a review of 169 primary PIP arthroplasties by 8 surgeons in 103 patients for osteoarthritis at our institution from 1998 to 2012. The mean age at surgery was 65 years, BMI 26, with 51% involving the dominant extremity, 84% females, 5% smokers, 2% laborers, and 6% with diabetes mellitus (DM). Implants utilized included 108 pyrocarbon, 53 surface replacing arthroplasties (SRA), and 8 silicone. Patient characteristics were similar between the pyrocarbon, SRA, and silicone groups: age (65, 65, 66), females (84%, 83%, 88%), and DM (4%, 8%, 25%), respectively.

Results: There were 26 revision surgeries performed at a mean 1.3 years postoperatively. The 2, 5 and 10 year survival rates were 88%, 82%, and 80%, respectively. The 5-year survival rates for the pyrocarbon, SRA, and silicone implants were 85%, 77%, and 88% (p=0.69), respectively (**Figure 1, Table 1** silicone (blue), pyrocarbon (red) and SRA (green)). There were 8 intraoperative fractures that complicated the primary arthroplasty. Postoperatively, there were 2 periprosthetic fractures, 4 dislocations, 10 heterotopic ossification, and 7 infections. Silicone implants were associated with an increased infection rate (p=0.03). In those unrevised patients, at a mean 5.3 years (2-11) follow-up, pain levels improved from preoperatively to postoperatively (p<0.01). PIP total arc of motion did not significantly change from preoperatively (47°) to postoperatively (44°) (p=0.67). There also was no significant change in grip (p=0.34) or pinch strength (p=0.32). There were no significant differences according to implant type regarding pain (p=0.44), as well as grip or pinch strength (p>0.21). The total arc of PIP motion in the pyrocarbon, SRA, and silicone groups was 42°, 57°, and 42° (p=0.29), respectively.

Summary Points: Arthroplasty in the treatment of osteoarthritis with PIP provides predictable pain relief, with preservation of PIP motion, and reasonable medium-term implant survival There were no differences between 3 different types of implants with regards to survival, complications, pain relief or PIP motion.



AAHS #2 Are Surgeons Price-Sensitive? A Randomized Controlled Study on Factors Driving Surgeon Implant Selection

Amy Wasterlain, MD¹; Eitan Melamed, MD²; Raj Karia, MPH¹; Kathryn Birenbaum, MD¹; John T. Capo, MD¹
¹NYU Hospital for Joint Diseases, New York, NY; ²Johns Hopkins Bayview Medical Center, Baltimore, MD

Introduction: Surgical costs are under scrutiny by the public, and healthcare providers are increasingly being held accountable for containing medical costs. Surgical implants are often the largest component of total procedure cost, yet previous studies have revealed that surgeons' knowledge of implant prices is poor. Our study aims to (1) understand the drivers behind implant choice, and (2) assess whether educating surgeons about implant costs affects their implant choices.

Methods: We surveyed 226 orthopaedic surgeons across 6 continents. The survey presented 8 clinical cases of upper extremity fractures with history and radiographs, followed by surgical implant options. Surgeons were randomized to receive either a version that included each implant's average selling price ("price-aware" group), or a version without any mention of price ("price-naïve" group). Surgeons were asked to select a surgical implant and to rank factors affecting implant choice. Six cases offered different classes of implants (eg, Kirschner wires, volar locking plate, or spanning external fixator for a distal radius fracture). Two cases offered different implant models within the same class (eg, volar locking plate implants with fixed or variable angle screws). Descriptive statistics and univariate analyses were performed.

Results: Cost-effectiveness was ranked as the most important factor in implant selection by 19% of price-aware vs 6% of price-naïve respondents. Familiarity with the implant was the most common reason for choosing an implant in both groups (35 vs 46%). Implant selection was similar between price-aware and price-naïve surgeons for cases comparing different classes of implants ($p=0.26$), but it differed significantly for cases comparing models within the same implant class. When offered different models of distal radius volar locking plates, 25% of price-naïve surgeons selected the most expensive plate vs only 7% of price-aware surgeons ($p<0.001$). Similarly, the most expensive distal humerus plate was selected by 25% of price-naïve surgeons vs only 13% of price-aware surgeons ($p=0.01$). On average, price-aware surgeons selected implants that were 9-11% cheaper than price-naïve surgeons.

Conclusions: Although price does not alter a surgeon's decision to use a certain class of implant (eg, locking plate vs external fixator), price awareness does significantly influence surgeons' choice of a specific implant model within a general class (eg, volar locking plates with different features). Merely including prices with a list of implant options increases surgeons' perception that price is important. This implies that a real, untapped opportunity exists to reduce surgical expenditures simply by enhancing surgeons' awareness of implant costs.

ASPN #1 Electrical Stimulation Enhances Axon Regeneration And Functional Recovery Following Cubital Tunnel Surgery In Humans - A Randomized Controlled Trial

Hollie A. Power, MD; Michael J. Morhart, MSc, MD; Jaret L. Olson, MD; K. Ming Chan, MD

University of Alberta, Edmonton, AB, Canada

Introduction: Brief post-surgical electrical stimulation (ES) enhances motor and sensory axonal regeneration in animal models following axotomy and crush injury. Although improved physiological outcomes with ES have also been shown in humans following carpal tunnel release, there was no significant difference in functional recovery compared to those who underwent surgery alone. The underlying reason is that thenar muscle strength only plays a small role in hand dexterity. In contrast, the ulnar nerve innervates the majority of hand muscles and makes a vital contribution to hand strength. In this study, we investigated the hypothesis that ES following cubital tunnel surgery in patients with severe ulnar neuropathy would result in better muscle reinnervation and functional recovery compared to surgery alone.

Methods: Patients with severe axonal loss from ulnar nerve compression at the elbow (McGowan grade III) were randomly assigned to the treatment or control group in a 2:1 ratio. Those in the control group received cubital tunnel surgery alone, while patients in the treatment group received 1 hour of 20Hz ES following surgery. Stimulation was delivered via two stainless electrodes placed adjacent to the ulnar nerve intraoperatively. Patients were followed yearly for 3 years. At each visit, axonal regeneration was quantified using motor unit number estimation (MUNE) and functional recovery was evaluated using grip strength and key pinch strength. Statistical analysis was performed using non-parametric tests, with statistical significance set at $p < 0.05$.

Results: Twenty-four patients were enrolled in the study: 8 received surgery alone and 16 received surgery and ES. There was no significant difference in demographics between the two groups. At three years following surgery, MUNE was significantly higher in the treatment group (182 ± 25 , mean \pm SE) compared to controls (93 ± 14 , $p < 0.05$). In terms of functional recovery, grip strength was significantly improved in the treatment group (43 ± 3 kg) at 3 years post-operatively compared to controls (39 ± 3 kg, $p < 0.05$). Key pinch strength was also significantly better in the treatment group (5.2 ± 0.5 kg) compared to controls (4.4 ± 0.8 kg, $p < 0.05$).

Conclusions: Our results suggest that post-surgical ES enhances axonal regeneration, muscle reinnervation and functional recovery following cubital tunnel surgery in humans. We propose that ES may be a clinically useful adjunct to surgical decompression for severe ulnar neuropathy, where functional recovery with conventional treatment is poor.

ASPN #2 Neurolysis Outcomes in Leprosy Patients: Prospective Study of Sensory and Motor Changes Following “Double CRUSH” Decompressions

Eric Wan, BS; Gedge D Rosson, MD; A. Lee Dellon, MD
Johns Hopkins University, Towson, MD

Purpose: Since the mid-1950s, for “leprosy,” retrospective case series reported outcomes following decompression of single anatomic sites of compression, and, more recently studies comparing efficacy of steroid versus single surgical site decompression have been reported. The purpose of the present study is to apply, prospectively, concepts developed from the successful treatment of diabetics with neuropathy and multiple sites of chronic nerve compression to patients with leprosy neuropathy.

Methods: Working in the indigenous leprosy area in Guayaquil, Ecuador, a protocol was developed that could be applied prospectively to a cohort of 20 patients with leprosy neuropathy who had been medically treated for infection but who had not received steroid treatment for neuropathy. An IRB-approved protocol was established in which each patient received surgery upon one leg and one arm simultaneously, with the goal of decompressing nerves at multiple anatomic sites of known compression, e.g., median and ulnar nerve at the wrist and elbow, peroneal nerve at knee and lower leg, tibial nerve at the four medial ankle tunnels. A total of 88 nerves were decompressed. Outcomes measured were changes in one and two-point static-touch, muscle strength change by manual motor testing and grip strength, comparison between operated and non operated side, and changes in score of validated “instruments” to measure quality of life, disability and pain (Rand36, Q Dash, and VAS, respectively). Outcome measurements were obtained by someone other than the surgeon at 12 and 24 months post-operatively.

Results: Eighteen of 20 patients returned for post-operative sensory evaluation. There were no post-operative complications. 72% of patients have sensory improvement demonstrated by PSSD testing. 65% of patients returned for motor testing, and 100% reported motor improvement and demonstrated motor testing score of > 4/5. 64% of decompressed nerves improved in sensibility: 78% of 18 median nerves, 53% of 17 ulnar nerves, 63% of 16 radial nerves, 71% of 14 common peroneal nerves, and 56% of 16 tibial nerves. Among those patients with completed outcome instruments, quality of life improved, hand disability decreased and pain scores decreased significantly, $p < .05$.

Conclusions: Application of double crush concept to decompression of multiple peripheral nerves is feasible in the population with leprosy neuropathy, and, in this small cohort of patients, gave improvement in sensory and motor function in the majority of patients.

ASRM #1 Correlation between Indocyanine Green (ICG) Patterns and Real-time Elastography Images in Lower Extremity Lymphedema Patients

Nobuko Hayashi, MD; Takumi Yamamoto, MD; Akitatsu Hayashi, MD; Hidehiko Yoshimatu, MD
Plastic and Reconstructive Surgery, University of Tokyo Hospital, Tokyo, Japan

Background: ICG lymphography is becoming a popular modality with clear visualization of superficial lymph flows, but unfortunately not available in all institutions. Elastography is a relatively new ultrasonographic technique to evaluate tissue elasticity, which visualize fluid retention as a red region in lymphedema patients. The aim of this study was to evaluate the correlation between elastography and ICG lymphology.

Methods: The study was a retrospective observational study. Thirty-six legs in 18 patients with secondary lower extremities lymphedema (LEL) and 20 legs in 10 healthy volunteers were examined with elastography. Thirty-six legs in 18 secondary LEL patients were examined with ICG lymphography. Elastography was performed on both legs at the following 3 sites: medial thigh (MT), medial leg (ML), and anterior ankle (AA). The area of red region in the subcutaneous tissue demonstrated by elastography was calculated with Image J software (National Institute of Health, Bethesda, MD). ICG lymphography findings were classified into the following 4 patterns: linear (ICG1), splash (ICG2), stardust (ICG3), and diffuse (ICG4) patterns.

Results: As ICG pattern progressed, red region area was likely to increase. There was correlation between ICG patterns and red region area according to the severity at bilateral MT ($r_s = 0.665$), ML ($r_s = 0.623$), AA ($r_s = 0.668$). Significant difference was demonstrated among group means of red region area by analysis of variance (healthy vs. ICG1 vs. ICG2 vs. ICG3 vs. ICG4: 14.4 ± 5.7 vs. 15.1 ± 10.3 vs. 25.2 ± 6.2 vs. 30.8 ± 9.4 vs. 35.0 ± 2.8 ; $P < 0.001$).

Conclusions: The area of red region in the subcutaneous tissue shown with elastography, which represents fluid, increases with aggravation of lymphedema demonstrated by ICG patterns. Since elastography is performed by ultrasonography which is available in most institutions, elastography could be a useful alternative evaluation for lymphedema severity when ICG lymphography is not available.

Fig.1

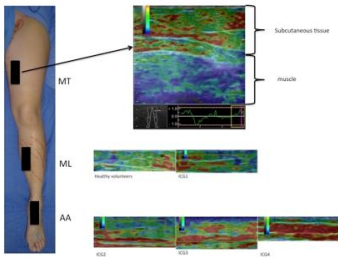
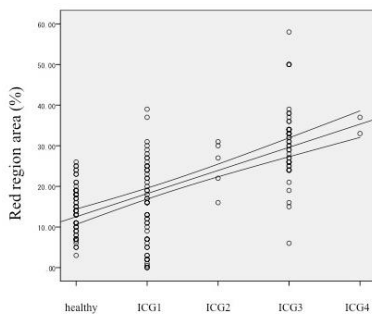


Fig.2



ASRM #2 A Single Institution Experience with 116 Consecutive Free-Flap and Pedicled Phalloplasties

Bauback Safa, MD, MBA, FACS¹; Andrew J. Watt, MD¹; Curtis Crane, MD²

¹The Buncke Clinic, San Francisco, CA, ²Brownstein & Crane Surgical Services, Greenbrae, CA

Introduction: Numerous phalloplasty techniques have been described for the female-to-male transgender population. Three of the most common flaps used today are the radial forearm flap, the anterolateral thigh flap, and the musculocutaneous latissimus dorsi flap. While there has been a large series of radial forearm flaps published in the past, there has not been a large series published in the United States. Also, no large series has been published comparing outcomes of these three flaps.

Materials and Methods: A retrospective review of all female-to-male phalloplasties from April 2013 to June 2015 was done. Complications including total flap loss, partial flap loss, flap take-back, hematomas, urethral strictures, fistulas, and meatal stenosis were reviewed. Outcomes measured included flap survival, sensory return, the ability to urinate through the phallus, and patient satisfaction.

Results: In total, 116 phalloplasties were performed at our institution. These included 71 radial forearm flaps (61%), 43 anterolateral thigh flaps (37%), and 2 musculocutaneous latissimus dorsi flaps (2%). There were no flap losses (0%) and four partial flap losses (3%). None of the partial losses exceeded 30% of the flap. Five flaps (4%) were re-explored for vascular compromise (three for arterial compromise, two for venous compromise) and all flaps were salvaged. The take-back rate for the first 16 flaps was 19%; the take-back rate for the remaining 100 flaps was 2%. The hematoma rate was 6% (n=7; three donor site hematomas, four groin hematomas). Of the 73 radial forearm flaps, the common femoral or superficial femoral artery were used as recipient vessels (end-to-side) in 71 cases (97%); a side branch was used in two cases (3%). The saphenous vein or a branch off the sapheno-femoral junction was used for all venous anastomoses. Urethral fistula and stenosis rates were 16% and 20% respectively. The rate of meatal stenosis was 5%. Of the radial forearm and ALT flaps that have reached an end-point of nerve regeneration, 99% have had return of tactile sensation; 85% have had return of erogenous sensation. There were no significant differences between the two groups. Neither latissimus musculocutaneous flap patients had return of tactile or erogenous sensation.

Conclusions: To our knowledge, this is the largest presented series of phalloplasties in the United States. This series shows that both the radial forearm and the anterolateral thigh flap (in select patients) can be viable options for an aesthetic and functional phalloplasty with good sensation and low fistula rates compared to other published series.

Scientific Paper Session III

21. Morphometric Evaluation of the Corrugator Migraine Trigger Point

Ashley M. Stasiak, MD¹; Theodore A. Kung, MD²; Kavitha Ranganathan, MD²; Eric E. Adelman, MD²; Jeffrey E. Janis, MD³; Paul S. Cederna, MD²

¹University of Southern California, Los Angeles, CA; ²University of Michigan, Ann Arbor, MI; ³Ohio State University Wexner Medical Center, Columbus, OH

Introduction: Migraine headaches are often linked to a specific trigger point involving the corrugator muscle and the supraorbital and supratrochlear nerves. Some have postulated that hypertrophy of the corrugator muscles leads to nerve compression and subsequent migraine headaches. However, it is unknown whether anatomic differences in the corrugator trigger points of migraine patients contribute to the initiation of symptoms. The purpose of this study is to perform morphometric evaluation of the corrugator muscles in migraine patients and to compare these anatomic findings to those of controls patients without migraine headache.

Methods: A retrospective review was conducted to identify patients diagnosed with migraine headache by a neurologist as well as control patients without migraine headache. Each patient underwent a computed tomography (CT) scan for inclusion in the study. Exclusion criteria included any intracranial abnormalities, atypical pain syndromes, previous craniofacial trauma, or psychiatric hospitalization. Using a three-dimensional imaging processing program (Vitrea Core), morphometric evaluation of the corrugator muscles was performed in a randomized and blinded fashion on 90 migraine headache patients and 90 control patients. To account for variation in skull size, measurements were normalized to zygoma-to-zygoma distance. When the sidedness of the corrugator trigger was documented, further subgroup analysis was performed in these patients. Statistical comparisons were performed using t-tests.

Results: The average age was 42 years and 38 years for migraine subjects and controls, respectively ($p=0.08$). Migraine patients were more commonly female (72%) and had other neurologic (20%) or psychiatric disorders (47%). Among all migraine patients, the mean corrugator volume was 1.12 ± 0.30 cm³ compared to 0.97 ± 0.25 cm³ in controls ($p=0.0004$) whereas the mean maximum thickness was 5.62 ± 1.02 mm compared to 5.35 ± 0.95 mm in controls ($p=0.07$). The mean disparity between left and right corrugator volume and thickness in migraine patients was statistically equivalent to controls. In 28 patients, the specific sidedness of the corrugator trigger point was documented and mean measurements from the symptomatic side (either left or right) were considered together compared to the mean contralateral asymptomatic side: the mean symptomatic corrugator volume was 0.95 ± 0.18 cm³ versus 0.98 ± 0.15 cm³ ($p=0.60$); the mean symptomatic corrugator thickness was 5.26 ± 0.87 mm versus 5.40 ± 1.00 mm ($p=0.58$).

Conclusions: Mild corrugator hypertrophy may contribute to migraine headaches. However, our results suggest that muscle hypertrophy in itself does not play a major role in triggering migraine headaches. Instead, other factors such as muscle hyperactivity or peripheral nerve sensitization may be more causative.

22. A Novel Surgical Approach to Chronic Temporal Headaches

Ziv Peled, MD

Peled Plastic Surgery, San Francisco, CA

Introduction: Peripheral nerve decompression for the treatment of chronic headaches has been established as a viable option for many patients with symptoms refractory to more conservative treatment modalities. One of the compression points identified as a cause of such headaches is the anterior temporal region in the vicinity of the zygomaticotemporal nerve. The published literature describes excision of this nerve through either an endoscopic approach or a transpalpebral approach. The goal of this study was to assess outcomes after surgical treatment of the zygomaticotemporal nerve through a temporal approach which allows for decompression as well as excision thereof.

Methods: Between September 2012 and October 2014, 19 patients underwent zygomaticotemporal nerve decompression/neuroplasty or excision/implantation for chronic headaches. Data on headache frequency, duration and severity were prospectively collected and used to calculate a Migraine Headache Index (MHI) score, a validated measure of headache pathology. Patients with less than three months of follow-up were excluded from the study. Data were analyzed using a two-tailed t-test for significance.

Results: Mean post-operative follow-up from the 19 patients was 14.6 months. Analysis of the mean MHI scores from the group demonstrated a significant improvement in MHI scores from the pre-operative to the post-operative assessments (140.2 to 50.3, respectively, $p < 0.0001$). 7 patients (37%) reported complete resolution of their severe headaches. 85 % of patients reported at least a 50% reduction in their headache symptoms. There were no post-operative complications in this series.

Conclusion: Surgical treatment of the zygomaticotemporal nerve can be successfully performed through a temporal approach. The results of this series mirror those of previously published studies demonstrating its efficacy in treating headaches caused by ZTN neuralgia. The advantages of this approach over other approaches include a hidden scar, the ability to access the auriculotemporal nerve through the same incision and the ability to perform a neuroplasty/decompression as well as transection/implantation.

23. Surgical Management of Peripheral Nerve Tumors within the Neurofibromatosis Population

Marc Soares, MD; Jordan Frey, MD; Jeffrey Allen, MD; Sheel Sharma, MD

New York University Medical Center, New York, NY

Background: Peripheral nerve tumors of the extremities represent a therapeutic challenge, as surgical management risks permanent deficits with potentially significant functional impairment. This is particularly a concern in patients affected by neurofibromatosis (NF), as this population is genetically prone to multiple peripheral nerve tumors that impart significant disability. Hesitation to surgically treat symptomatic tumors exists from fear of irreversible neurologic impairment. We seek to characterize our experience with surgical management of these tumors in the extremities within the NF population.

Methods: A retrospective review of a single-surgeon experience between 2011-2014 of peripheral nerve tumor excisions within the extremities was performed. Demographic, clinical, and pathologic criteria were collected. Patient reported outcomes were surveyed to assess therapeutic efficacy.

Results: 49 peripheral nerve tumors were removed from 22 patients over a four-year period with a mean follow-up of 8 months. 12 patients (55%) were NF1, 8 patients (36%) patients were NF2, and 2 patients (9%) had schwannomatosis. Pain was the most common indication for surgery (73%), and 18% of patients had abnormal neurologic exams. 43% of tumors involved cutaneous nerves while 57% involved either motor or named sensory nerves. 81% of tumors were greater than >2.0cm, while 24% were greater than 5.0cm, 6% of tumors were plexiform. Surgical techniques included “shelling-out” peripheral nerve tumors from involved fascicles, microdissection, and techniques including epineurial repair and nerve grafting. Plexiform neurofibromas were aggressively debulked. Intraoperatively, 60% of cases utilized nerve monitoring. Pathologic analysis revealed that 60% of masses were neurofibromas, 36% schwannomas, and 4% peripheral nerve sheath tumors. 45% of patients had preoperative imaging. 3 patients (13%) reported sensory defects post-resection that subsequently improved, one patient (5%) reported transient motor weakness post-op which also improved. 65% of eligible patients participated in our patient-reported outcome survey. Findings included perceived improvement in post-operative health (1.27 versus 2.72, $p=0.01$), a decrease in body pain (1.81 versus 1.07, $p=0.02$), and reduction in pain that interferes with ADLs (1.45 versus 0.68, $p=0.04$). No patient regretted their decision to pursue surgical treatment, scoring an average of 4.8/5 points in favor of surgery to address a future peripheral nerve tumor.

Conclusions: Surgical management of extremity peripheral nerve tumors is challenging in the NF population. We demonstrate that both small and large tumors can be treated safely with an acceptable complication rate providing not only pathologic diagnosis but also significant improvements in quality of life for these unique patients.

24. Growth Associated Gene Expression Declines Concurrent with Reduced Regenerative Capacity in a Rat Model of Chronic Nerve Injury

Tessa Gordon, MD¹; Wolfram Tetzlaff, MD²

¹University of Alberta, Edmonton, Canada; ²University of British Columbia, Vancouver, BC, Canada

Introduction: The regenerative capacity of injured neurons and the regenerative support provided by Schwann cells declines when surgical repair is delayed and over time and distance. Injured neurons undergo morphological changes that reflect altered gene expression including the upregulation of growth associated genes (GAGs) that include the cytoskeletal proteins, actin and tubulin, and neurotrophic factors such as glial and brain derived neurotrophic factors. The question that we asked is whether this expression is sustained or whether there is a regression with time that might, in turn, account for the progressive reduction in the capacity of chronically injured neurons to regenerate their axons.

Methods: In Sprague Dawley rats, sciatic nerves were transected and the nerve stumps ligated and sutured to innervated muscle to prevent regeneration for periods of up to 6 months. In a subgroup of rats, the proximal nerve stump was refreshed and again ligated to prevent nerve regeneration. At 7 days and months after axotomy, the expression of actin, tubulin, neurofilament, and GAP-43 in the motoneurons that supplied the experimental axotomized sciatic nerve and those that supplied the contralateral intact sciatic nerve was determined using *in situ* hybridization.

Results: When expressed relative to the RAG expression in the motoneurons supplying the contralateral intact sciatic nerve, the expression of tubulin, actin and GAP-43 mRNA was increased to a maximum and that of neurofilament was reduced within 7 days. Thereafter the RAG expression of each of the upregulated genes declined and the down-regulated genes increased with an exponential time course to reach basal levels equal to the contralateral sciatic motoneurons. This decline was reversed when the ligated nerves were refreshed by a transection injury but the expression of the tubulin, actin, and GAP-43 genes again declined and the neurofilament gene expression increased, the rate of the change in expression being significantly faster after the refreshment injury than after the first injury.

Conclusions: These findings demonstrate the transient nature of expression of RAGs and that, whether or not the ligated nerves were refreshed, the exponential decline in the expression reaches basal levels, the decline corresponding with the time course of decline in the regenerative capacity of chronically injured neurons. Therefore, the transient expression of RAGs accounts, at least in part for the relatively short window of opportunity when the regenerative response of injured neurons is maximal and when, in turn, functional return is optimal.

25. Excellent Recovery in Motor Nerve Gaps Reconstructed Using Human Processed Nerve Allograft

Renata V. Weber, MD

Institute for Nerve, Hand and Reconstructive Surgery, Rutherford, NJ

Introduction: Motor nerve injuries are far less common than sensory and mix nerve injuries. Those requiring a nerve graft reconstruction represent a minute subset. We present three patients who underwent reconstruction of motor nerve defects using processed human nerve allografts in which excellent recovery was achieved.

Materials and Methods: From March 2008 to June 2015, 3 patients underwent motor nerve gaps reconstruction with processed human nerve allograft. Patient 1, a 64 year old male with a left recurrent parotid gland tumor, had the lower facial nerve branches reconstructed with four 1-2 mm wide allografts between 25 to 30 mm in length. Patient 2, an 18 year old male with a lacerated biceps branch of the musculocutaneous nerve, was repaired using a 3-4 mm x 15 mm allograft. Patient 3, a 45 year old male with a traumatic laceration of the facial nerve and no viable fascicles in the proximal stump underwent 2 motor nerve transfers, the hemi-hypoglossal to mandibular branches nerve transfer requiring a 1-2 mm x 20 mm interposition graft. No graft rejection or infection occurred. Results were graded using the Medical Research Council Classification (MRCC).

Results: Meaningful recovery was seen in the first 2 patients at the typical 1 inch/mo rate. The last patient has an appropriately advancing Tinel. The first facial nerve recovery (M5) showed recovery equal to the unaffected side for zygomatic and buccal branches and mild weakness (M4) to the marginal mandibular branch by 3 months, while the ungrafted upper nerve branches achieved meaningful recovery (M5) by 9 months. The biceps branch injury showed motor recovery by EMG studies at 6 months. M5 recovery was seen in elbow and shoulder flexion/extension, abduction and adduction at the 10 month follow-up visit.

Conclusion: The use of processed human nerve allograft for sensory nerve gap reconstruction has gained a wider acceptance over the last few years. Its use in motor and mixed motor nerve defects is still limited and even considered controversial. In the case of these two patients, M4+ motor nerve recovery through a nerve allograft as long as 30 mm was achieved without rejection or infection of the allograft. We suggest that a processed human nerve allograft is a viable option for motor nerve reconstruction.

26. Glenohumeral Dysplasia Following Neonatal Brachial Plexus Palsy: Presentation During Infancy And Predictive Features

Matthew Iorio, MD¹; Menashe Sarah, MD²; Ramesh Iyer, MD²; Sarah Lewis²; Suzanne Steinman, MD²; Kathryn Whitlock, MD²; Raymond Tse, MD²

¹Harvard Medical School, Boston, MA; ²Seattle Children's Hospital, Seattle, WA

Introduction: Glenohumeral dysplasia (GHD) is thought to occur as progressive maladaptive changes from muscular imbalance in children with neonatal brachial plexus palsy (NBPP). Studies and treatment have focused on children over 1 year of age who have reduced passive range of motion.

We have observed GHD in infants, younger than 3 months of age, and in infants who have retained normal range of motion. The purpose of this study was to determine the presence, extent, and predictive factors for GHD in infants undergoing surgical exploration for NBPP.

Methods: We included all consecutive infants undergoing brachial plexus exploration at our institution over a 3-year period. Indications for surgery followed the Toronto protocol. Preoperative MRIs were assessed to determine skeletal changes including: glenoid morphology, glenoid version, percent humeral head anterior to the scapula, and Water's classification. Demographic, therapy, and surgical data included: age, palsy type, range of shoulder motion, and root avulsions. Spearman correlation was calculated for association of age with Water's classification. Associations between skeletal changes and demographic, therapy, and surgical data were assessed using separate univariate and multivariate linear regression models.

Results: Of 116 infants that presented to our institution, 19 underwent surgical exploration (16%). The distribution of palsy type by Narakas classification was: 21% Type I, 26% Type II, 16% Type III, and 37% Type IV. At exploration 63% had an avulsion of at least one root level. The median age at the time of MRI was 16 weeks with interquartile range 14 to 46 weeks.

74% had GHD of Water's class 2 or worse. Age was associated with severity of GHD ($r=0.58$, $p=0.01$) as 50% of infants younger than 6 months and 100% of infants 6 months or older had GHD.

Less severe GHD was associated with more severe palsies as indicated by Narakas classification ($p=0.02$) and number of root avulsions ($p=0.02$).

In this group of subjects, external rotation was almost universally absent whereas other shoulder movements were present to varying degrees. More severe GHD was associated with greater total shoulder active range of motion ($p=0.01$) and greater pectoralis major muscle mass ($p=0.03$).

Conclusions: GHD is common in infants undergoing surgical exploration of their brachial plexus. It develops early in life and can occur in the absence of restricted range of motion.

Predictors include increasing age and factors related to muscular imbalance.

Early screening of all infants with NBPP and early treatment of GHD may improve outcomes.

27. Recovery of Hand Function After Surgical Reconstruction Of Brachial Plexus In Obpp

Mohamed Mostafa Kotb, MD

Assiut University Hospital, Assiut, Egypt

Introduction: Obstetric brachial plexus palsy (OBPP) is an injury with deleterious medical, psychological and socioeconomic sequelae both for the patient and his or family. The loss of feeling or the simplest God-given skills such as muscle control in an infant's arm and hand can affect families for an entire lifetime.

Patients and Methods: 43 patients with total obstetric brachial plexus palsy underwent brachial plexus exploration and reconstruction. The distribution of the patients between the two genders was almost equal, with 22/43 males (51.1%) and 21 females (48.9%). The right side was affected in 27 (62.7%) cases and left side in 15 (35.3%) cases. Bilateral affection was noticed in 1 (2.3%) case in which the left side was treated conservatively and the other side was explored surgically. The Mean age at surgery was 15.8 months (3-96 months). The mean follow-up period was 3.7 years.

Surgical procedures included neurolysis; neuroma excision and interposition nerve grafting and neurotization, using spinal accessory nerve, intercostal nerves and cross neck C7 root. Nerve suture was done in all cases using 10/0 Nylon suture.

Evaluation of hand function using the Toronto scale, Raimondi grading system and Limb integration into the normal daily activities

Results: Satisfactory recovery was obtained in 61.1% for finger flexion; 31.4% for wrist extension and 45.8% for fingers extension. Using the Raimondi scoring system, out of 32 cases 16 achieved a score of 3 or more (functional hand), 16 cases had a score of 2 or less. As regards limb integration into the normal daily activities 3 cases were poor, 8 cases were fair, 14 were good and 8 were excellent. Limb integration did not significantly correlate with any of the regained upper limb functions except a positive significant correlation with shoulder external rotation.

Summary and Conclusion: Supra and infra clavicular explorations should be conducted in every case for possible existence of double level lesion. In total palsy the earlier the intervention the better the results. Apparently intact C8 and T 1 root should be left alone if the patient has partial recovery, no horner sign and was operated early enough (3 or 4 month age). An apparently intact non functioning root with no positive response to electrical stimulation and especially in the presence of Horner syndrome should be neurotized with the best available intraplexal donor.

28. Motor Recovery After Birth-Related Brachial Plexus Resection and Grafting

Christine V. Schaeffer, BS; Darlene M. Sparkman, MD; Ann Schwentker, MD

University of Cincinnati College of Medicine, Cincinnati, OH

Background: This study assesses the impact of preoperative motor function on the outcome and rate of recovery following nerve grafting for birth-related brachial plexus injury (BRBPI). With the advent of nerve transfer procedures, the suitability of excision and grafting for patients who have begun to demonstrate motor recovery has been debated, with some authors feeling that the risk of downgrading function by resecting conducting nerve fibers is too great.

Methods: The records of BRBPI patients who underwent nerve grafting after neuroma resection were reviewed. From 2004 to 2009, 72 BRBPI patients underwent neuroma excision and grafting. 56 had both preoperative and greater than 6 month postoperative Active Movement Rating Scale (AMS) data (median follow up of 25.5 months). For each movement assessed, patients were divided into two groups, those with preoperative movement (+, AMS ≥ 2), and those without (-, AMS 0 or 1). Changes in AMS scores over time were analyzed using a Two Way Repeated Measures ANOVA.

Results: Neuroma resection did result in temporary loss of motor function in all (+) patients, as expected. However, by six months postoperatively, patients with evidence of preoperative motor recovery (+) had significantly higher AMS scores for shoulder abduction ($p < 0.001$), shoulder external rotation ($p = 0.021$), and elbow flexion ($p = 0.002$) compared to those with no preoperative motion (-). Motor recovery was also faster in these patients ($p < 0.001$). There was no statistical difference in shoulder flexion in the (+) compared with the (-) group.

Conclusions: Although neuroma resection does result in temporary loss of function in those patients who have already begun to recover motor function, patients with birth-related brachial plexus injury and evidence of preoperative motor function (+) demonstrated faster postoperative motor recovery and increased postoperative motion compared to patients with preoperative paralysis (-). Therefore, resection and grafting does not downgrade function long term, even when functional axons are cut, and has the potential to bring new axons into the arm. Further studies directly comparing nerve transfers with resection and grafting will be required to determine the preferred procedure in this patient population.

29. Elbow Flexion Reconstruction by End-to-Side Neurorrhaphy in Phrenic Nerve Transfer

Mou-Xiong Zheng, MD; Wen-Dong Xu; Yun-Dong Shen; Jian-Guang Xu; Yu-Dong Gu
Huashan Hospital, Fudan University, Shanghai, China

Purpose: Phrenic nerve transfer (PNT) has been proved to be an effective approach for the treatment of brachial plexus avulsion injuries (BPAI). But there have been major concerns about the possibility of deterioration of the pulmonary and diaphragm functions after PNT. In the current study, we performed end-to-side neurorrhaphy in PNT for BPAI patients while minimizing the potential damage to the diaphragm function. We prospectively assessed the efficacy of end-to-side neurorrhaphy for PNT in reconstructing the elbow flexion by regenerating the anterior division of the upper trunk (ADUT) or the musculocutaneous nerve (McN) in a series of five patients.

Methods: From January to June 2008, five patients with BPAI underwent PNT with an end-to-side fashion, to regenerate the ADUT (3 patients) or the McN (2 patients). The operative delay after injury was from 1 month to 6 months (mean 2.5 months). The follow-up duration was 24 months. The regeneration outcomes of ADUT or McN were evaluated with an electromyography (EMG) test. The recovery of elbow flexion power was recorded according to the British Medical Research Council (MRC) grading system. Pulmonary function tests (PFTs) were used to assess the respiratory function. Chest fluoroscopy and phrenic nerve conduction studies were performed in the evaluation of phrenic nerve and diaphragm functions.

Results: At the final visits after two years, all patients regained various degrees of biceps strength (M4 in 2, M3 in 1, M2 in 1 and M1 in 1 patient). At 24 months after surgery, the average prolongation of latency of PN was 2.88 s, and the average decrease of amplitude from before the operation was 32.4%. The diaphragm function and PFTs were normal in all patients.

Conclusions: PNT with end-to-side neurorrhaphy could provide functional biceps recovery in a majority of patients, with preservation of donor nerve function.

30. Can Mackinnon/Oberlin-II Double Fascicular Distal Nerve Transfer for Elbow Flexion Restoration Be Used for C5-C8 Acute Brachial Plexus Injuries?

Tommy Nai-Jen Chang, MD; Kee-Min Yeow, MD; Frank Fang, MD; Johnny Chuieng - Yi Lu, MD; David Chwei-Chin Chang, MD

Chang Gung Memorial Hospital, Chang Gung Medical College and Chang Gung University, Taoyuan, Taiwan

Introduction: Elbow flexion dysfunction is common in brachial plexus injury when C5-C7, C5-C8, or total roots (C5-T1) spinal nerve involved. The Mackinnon/Oberlin-II Double fascicular distal nerve transfer has proven to be a good reconstructive option and is widely used. However, the recommended indication for this technique currently is directed to C5-C6 and C5-C7 injuries. It is not known if this technique can be used in C5-C8 injuries since the donor nerve (C8) is potentially injured as well.

Material and Method: Between 2008 and 2014, 30 patients were evaluated by clinical, imaging, electromyographic, and nerve conductive studies. The patients were divided into two groups according to the diagnosis of spinal nerve injury by magnetic resonance imaging (MRI). Group I (n=17) were patients with C8-T1 intact and uninjured. Group II had injuries to C8-T1 (n=13). Patients in both groups were predominantly male (16:1 vs. 12:1) with similar average age (32.24 ± 12.66 years old vs. 29.62 ± 12.07 years old). The time intervals between injury and operation were closely matched (4.93 ± 2.20 vs. 4.42 ± 1.37 months). Preoperatively, the patients in group II had weaker function of median/ulnar nerve innervated muscles, weaker nerve conduction in both the median nerve (9.82 ± 2.96 vs. 8.13 ± 3.55 mV) and ulnar nerve (8.86 ± 3.61 vs. 6.86 ± 3.60 mV). However, the measured differences did not reach the level of statistical significance. Demographic data, preoperative neurologic examination, electromyographic and nerve conductive studies, and grip strength were recorded and analyzed.

Results: All patients achieved M4 level motor recovery except for one patient in group II who achieved M3. However, the recovery of group I was faster than group II (10.94 vs. 12.14 months to reach M3, 16.2 vs. 18.87 months to reach M4). Regarding donor site morbidity, group I had postoperative grip power of 19.5 kg (56% of the normal contralateral side), whereas group II had inferior grip power of only 17.5 kg (41.9% of the normal contralateral side).

Discussion: The Mackinnon/Oberlin-II double fascicular distal nerve transfer is an effective option for restoration of elbow flexion even when the donor nerve (C8) has evident injury. The indication of this technique may be extended to include acute C5-C8 brachial plexus injuries.

31. A Longitudinal Study of Pain, Personality and Plasticity following Peripheral Nerve Injury

Dimitri J. Anastakis, MD¹; Ruma Goswami, PhD²; Joel Katz, PhD¹; Karen D. Davis, MD²

¹University of Toronto, Toronto, ON, Canada; ²Toronto Western Research Institute, Toronto Western Hospital, Toronto, ON, Canada

Improving outcomes following peripheral nerve injury (PNI) and repair will require greater understanding of the complex interplay between somatosensory recovery, pain, personality and brain plasticity.

We conducted a longitudinal examination of patients at two time points; weeks after PNI and repair (T1) and at one-year post-injury (T2). **Aim:** examine the link between somatosensory function and pain to brain plasticity and personality in patients following PNI and repair.

Materials and Methods: 10 patients participated. All had complete transections of the median ± ulnar nerve and underwent surgical nerve repair within 0-3 days post-injury. Ten age and gender matched controls were used for comparison. All participants provided informed REB approved consent.

Behavioural and MRI testing was performed three weeks after surgery (T1). 6/10 patients completed MRI and behavioural testing one-year post-injury (T2). Controls underwent assessments at one time point.

Results: At T1, patients' unaffected digit had a lower CPT compared to controls, indicating greater cold sensitivity. There was a significant correlation between pain catastrophizing and cold pain threshold (CPT) at T2.

At T1, patients exhibited a reduction in right insular gray matter thickness compared to controls. At T2, patients showed an increase in bilateral insula thickness back to control levels compared to paired patients at T1.

Conclusions: Half the PNI patients continued to experience neuropathic pain at one year post-injury. Catastrophizing was strongly correlated with pain intensity within weeks of injury and to CPT a year after PNI. Rapid reductions in insular cortical thickness were observed within weeks of PNI injury and repair, followed by thickening to control levels at one-year post-injury. These results illustrate the complex phenomena of somatosensory recovery, pain, personality and brain plasticity over time, and future interventions aimed at behaviour surrounding pain and altering cortical structure may improve pain intensity, disability and functional outcomes following PNI.

32. Intra-individual Comparison between Open and Endoscopic Release in Bilateral Carpal Tunnel Syndrome: A Meta-Analysis

Kejia Hu, MD, MD; Wen-Dong Xu, MD

Huashan Hospital, Fudan University, Shanghai, China

Purpose: To evaluate the efficacy, functional outcomes and safety after both endoscopic carpal tunnel release (ECTR) and open carpal tunnel release (OCTR) in the opposite hands of the same patients using a meta-analysis of data from randomized controlled trials.

Materials And Methods: Electronic searches of the Cochrane Register of Controlled Trials, PUBMED, and EMBASE (published between 1966 and May 2015) were used to identify randomized controlled trials that evaluated endoscopic vs open methods used in the opposite hands for treatment of bilateral carpal tunnel release. Studies to be used were independently identified by two researchers. The methodological quality of the studies was assessed by the Cochrane Collaboration tool for assessing risk of bias. Pooled relative risk (RR) and 95% confidence intervals (CIs) for safety and efficacy outcome variables were calculated by fixed-effect or random-effect methods with RevMan v.5.1. Five randomized controlled trials involving 142 bilateral hands with CTS were included.

Results: This meta-analysis indicated that ECTR resulted in significantly better Boston Carpal Tunnel Questionnaire functional status scores (BCTQ-f) than OCTR (RR = 0.13, p = 0.02), but did not significantly increase the symptom severity scores (BCTQ-s) (RR = 0.06, p = 0.25). ECTR needed more operative time (RR = -1.27, P = 0.008) compared with OCTR, comparing the same patient, serve as their own internal control, the results indicated that there were no statistical differences between the two procedures in VAS pain scores (RR = 0.02, p = 0.75), hand grip strength (RR = 0.17, p = 0.88), digital sensibility static 2PD (RR = 0.34, p = 0.07) and complication rates (RR = 0.01, P = 0.47).

Conclusion: Our meta-analysis specifically included the randomized controlled trials compared the patients who have bilateral CTS experience OCTR in one hand and ECTR in another, demonstrated that ECTR and OCTR were similar in complication rates, relief of symptoms, and recovery of strength and sensibility. However, ECTR resulted in better recovery of function but need more operative time than OCTR.

33. Facial Paralysis Clinician Assessments: Weighing the Variables

Caroline A. Banks, MD¹; Charles R. Hadlock, PhD²; Tessa Hadlock, MD¹

¹Harvard Medical School/Massachusetts Eye and Ear Infirmary, Boston, MA; ²Bentley University, Waltham, MA

Introduction: A widely accepted clinician-graded scale for facial function assessment would be a welcome tool for reporting, comparing, and assessing facial function amongst patients with facial paralysis. The recently described “eFACE” scale provides a 16-point visual analog scale with accompanying graphical outputs, and yields individual category scores, along with sub-scores for static, dynamic, and synkinesis elements, as well as a total score, all based upon 100-point scoring; the instrument is universally available for mobile phones, tablets, and computers. The current investigation seeks to correlate eFACE individual category scores, sub-scores, and total scores to expert-rated facial disfigurement, in an effort to understand the relative contributions of each of the features to facial paralysis-related disfigurement, and to provide an objective means of guiding surgical improvement based upon the eFACE scale.

Methods: Two hundred consecutive patients presenting to a tertiary care facial nerve center, and confirmed to have a unilateral facial movement disorder, underwent facial function assessment using the eFACE scoring system by two independent facial nerve surgeons. Likewise, the experts independently assigned a disfigurement score to each patient, with “0” representing the most extreme disfigurement possible from a facial nerve disorder, and “100” representing no discernible disfigurement. The scores were averaged, and a multivariate regression analysis was performed to fit the eFACE individual scores and subscores to the disfigurement ratings.

Results: Multivariable linear regression analysis using the three sub-scores of static, dynamic, and synkinesis categories yielded an equation showing excellent agreement with the clinicians’ estimate of disfigurement severity ($R^2 = .766$), matching previously published results. While the highest R^2 resulted from including all 16 scores ($R^2 = 0.788$), stepwise multivariate linear regression analysis revealed that among the 16 individual scores, the six most key contributors to overall disfigurement included, in descending order: oral commissure position at rest, lower lip asymmetry with saying “ee”, palpebral fissure width at rest, nasolabial fold orientation with smiling, oral commissure movement with smiling, and brow elevation with attempts at brow raising, with only a trivial decrease in prediction accuracy ($R^2 = 0.769$).

Conclusions: We have established a mathematical relationship between facial features and overall expert-graded disfigurement in facial paralysis, both defining the relative importance of these features to overall appearance, and permitting prediction of overall disfigurement related to facial paralysis. For those using the eFACE clinician-graded scale, predictions of the specific effects of various interventions on expert-rated disfigurement are now possible, and may guide therapy.

34. Qualitative and Quantitative Analysis of Smile Excursion in Facial Reanimation: A Systematic Review and Meta-Analysis of One- Versus Two- Stage Procedures

Hamidreza Natghian, MD¹; Jian Fransén, MD¹; Shai Rozen, MD²; Andrés Rodríguez-Lorenzo, MD, PhD¹

¹Uppsala University, Uppsala, Sweden; ²UT Southwestern Medical Center, Dallas, TX

Background: Free muscle transfer has become a standard of care for smile restoration in long-lasting facial paralysis. The selection of the surgical strategy between a two-stage versus a one-stage procedure has been debated. The former provides spontaneous smile by using the contralateral facial nerve as neurotizer but needs longer rehabilitation time, the need of a nerve graft and often weaker smile excursion. The latter uses the masseter nerve as neurotizer, provides early smile recovery and often a stronger smile, but spontaneous smile can only be achieved by some patients through cortical plasticity. The aim of this study is to compare the outcomes of smile excursion both quantitative and qualitative in one-stage versus two-stage free muscle transfers through literature review.

Methods: A comprehensive review of published literature was conducted from 1973 until October 2013. Inclusion criteria included those articles in which one- or two-stage procedures with free muscle transfer were performed for smile restoration in paralyzed face and the outcomes were expressed by measurement of smile excursion in mm or other scoring system that evaluated the smile. A meta-analysis was performed by a quantitative and qualitative evaluation of the outcomes of the smile restoration. For the quantitative analysis, smile excursion in mm between one-stage and two-stage procedures was compared and forest plot was done using Comprehensive Meta Analysis 2.0 (Biostat, Inc. 14 North Dean Street, Englewood, NJ 07631 USA). P-value under 0.05 were considered statistical significant. For the qualitative data, a descriptive analysis was performed by presenting qualitative data of the outcome translated to our own 7 type ordinal categorical scale with relatable nomenclature, ranging from *Failed/absent* to *Excellent*.

Results: The abstracts or titles of 1982 articles were screened. 23 articles met our inclusion criteria. For the purpose of meta-analysis, 6 articles, comprising 192 patients. The mean difference of oral commissure muscle excursion pre-versus postoperative muscle transfer compared for one- and two-stage procedures showed 12,7 mm for one-stage procedures and 7,5 mm for two-stage procedures (Figure 1). The results of the forest plot showed statistically significant favour to one-stage (Figure 2). For the systematic review 17 articles were included and the analysis showed a tendency for superior result for one-stage procedures (Figure 3).

Conclusion: The results of this review have to be interpreted with great caution. It might however indicate both in quantitative and qualitative studies some advantage of the one-stage procedure.

35. A Novel Approach To Synkinesis – Targeted Conduction Blockade Using High Frequency Alternating Current

Nate Jowett, MD, MSc, FRCSC; Christopher J. Knox, BSc; Tessa A. Hadlock, MD

Harvard Medical School / Massachusetts Eye and Ear Infirmary, Boston, MA

Introduction: Synkinesis following aberrant neuronal regeneration limits reanimation outcomes. This study investigates whether high frequency alternating current (HFAC) may be used to achieve a localized conduction blockade of the rat facial nerve.

Materials and Methods: Following calvarial titanium plate implantation to allow for head fixation, the left facial nerve was exposed in eight Wistar rats and affixed with neural cuffs at the main trunk, zygomatic, and buccal branches under general anaesthesia (Fig. 1). Following recovery, whisking and blinking displacements were quantified in the head-fixed rat while HFAC was applied to the main trunk and electrical stimulation signals were independently delivered to the proximal main trunk and distal branches.

Results: HFAC delivery to the main trunk resulted in a > 90% decrease in the amplitude of spontaneous and induced whisking and blinking displacements, without affecting receptivity of distal nerve branches to stimulation (Fig. 1). Reversibility of the neural conduction blockade was near instantaneous, with return of normal function noted on a millisecond timescale.

Conclusion: HFAC delivery to the rat facial nerve results in an effective, localized, and reversible conduction blockade. When paired with targeted distal stimulation signals, HFAC may provide a means to inhibit synkinesis in the electronic reanimation of the paralyzed hemi-face.

36. Medical Students and Physicians in Primary Care Specialties Perceptions of Plastic Surgeons as Peripheral Nerve Specialists

Andy Chao Hsuan Lee, BS; David B. Drake, MD; Brent R. DeGeorge, MD, PhD
University of Virginia, Charlottesville, VA

Introduction: Peripheral nerve surgery falls within the scope of multiple surgical sub-specialties. The purpose of this study is to survey the knowledge of both medical students and primary care providers regarding their management of both of upper and lower extremity compression neuropathies. Better educating medical students and primary care providers early in their training regarding the role of plastic surgeons as peripheral nerve specialists may improve future referral patterns.

Methods: Separate online surveys were administered to two cohort groups: (1) medical students, and (2) current residents and attending physicians in primary care disciplines (family medicine and internal medicine) at a large academic medical center (Image 1). The surveys included demographic questions customized to level of training/practice and a series of 5 clinical scenarios, including upper and lower extremity peripheral neuropathies. In each scenario, the participants were prompted to indicate their preference for indicated diagnostic studies, initial management plans, sub-specialty for appropriate ambulatory referral, and prior exposure to the clinical scenario. In addition, medical students were inquired regarding their prior exposure to surgical sub-specialties.

Results: 248 medical students (38.3%) and 54 primary care resident and attending physicians (13.5%) responded to the survey. Overall, students more commonly identified orthopedic surgeons as the appropriate sub-specialty for peripheral nerve specialty referral (Table 1). Clinical exposure to plastic surgery increased likelihood of referral to a plastic surgeon for both upper and lower extremity peripheral neuropathies (9%-35% with prior plastic surgery exposure vs. 0%-1% without, $P < 0.01$) (Table 2). 69.2% of medical students going into surgical specialties have been exposed to plastic surgery at completion of their medical school curriculum, compared to only 12.0% of those going into primary care specialties ($P < 0.01$) (Image 2). Among primary care residents and attending physicians, referral to orthopaedic surgery accounted for significantly more referral patterns for the 5 clinical scenarios, (46% to 67% for orthopedic surgery vs. 0% to 6.4% for plastic surgery, $P < 0.05$) (Table 3).

Conclusions: Medical students who have been exposed to plastic surgery more readily recognize peripheral nerve surgery as within the scope of plastic surgery. Medical students who aspire to go into primary care specialties do not have a high rate of exposure to plastic surgery during their medical school training. Improved education of both medical students and residents in primary care specialties, may improve the perception of plastic surgeons as peripheral nerve specialists, which may ultimately restructure referral patterns.

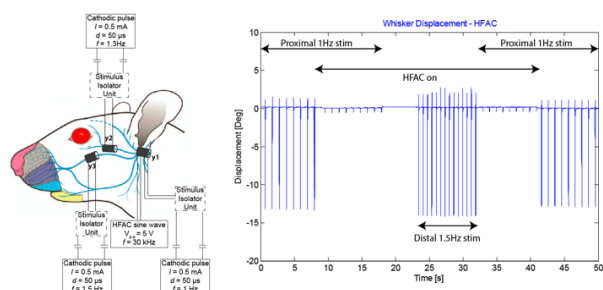


Fig 1. Design (left) and results (right) of high frequency alternating current (HFAC) blockade of the facial nerve in an anesthetized rat. Left: Cuff electrodes y1, y2, and y3 are implanted around the main trunk (y1), zygomatic (y2), and buccal branches (y3). A 1 Hz stimulation signal is delivered proximally through y1, a HFAC neural blockade signal is delivered distally through y1, and distal stimulation signals are delivered to y2 at 1.5 Hz to trigger blink and y3 at 1.5 Hz to trigger whisking. Right: Whisker displacement under various paradigms: from $t = 0$ to 8 s, proximal stimulation through y1 is applied without HFAC at 1 Hz. When HFAC is turned on ($t = 8$ s), displacement is reduced by $> 90\%$ and ceases when the proximal stimulation signal is switched off ($t = 18$ s). At $t = 23$ s, the distal stimulation signal at 1.5 Hz is applied through y3: return of normal function is demonstrated despite proximal HFAC signal delivery. At $t = 32$ s, distal stimulation is switched off and proximal stimulation at 1.0 Hz is switched back on. At $t = 42$ s, HFAC is switched off, and near instantaneous return of whisker displacement is demonstrated.

Image 1. Survey Questions

1. What is your gender?
2. Year in Medical School or Level of Training
3. **For Medical Students only:** Anticipated Career; **For Residents and Attendings only:** Specialty
4. **For Medical Students only:** Have you had a surgical rotation or shadowed a surgeon? If yes, which surgical specialties have you had exposure to? (you may select more than one)

Carpal Tunnel Syndrome

A 50 year old right hand dominant secretary presents with pain and paresthesia in the right thumb, index, long and radial half of the ring fingers. The symptoms are worse at night. You suspect carpal tunnel syndrome.

5. What additional studies would you obtain to confirm your diagnosis? (you may select more than one answer)
6. If you established the diagnosis of carpal tunnel syndrome, what treatment course would you recommend for this patient? (you may select more than one answer)
7. If you established the diagnosis of carpal tunnel syndrome, would you refer this patient for further management?
8. Assuming you would refer the patient, what specialty would you refer this patient to for further management? (you may select more than one answer)
9. **For Medical Students only:** Have you been lectured on carpal tunnel syndrome in the past? (in either classroom setting or clinical setting); **For Residents and Attendings only:** Have you diagnosed and treated a patient with carpal tunnel syndrome in the past?

Common Peroneal Nerve Compression

A 45 year old man presents with chronic right foot drop with paresthesia and sensory loss over dorsum of right foot and lateral leg. You suspect common peroneal nerve compression.

10. What additional studies would you obtain to confirm your diagnosis? (you may select more than one answer)
11. If you established the diagnosis of common peroneal nerve compression, what treatment course would you recommend for this patient? (you may select more than one answer)
12. If you established the diagnosis of common peroneal nerve compression, would you refer this patient for further management?
13. Assuming you would refer the patient, what specialty would you refer this patient to for further management? (you may select more than one answer)
14. **For Medical Students only:** Have you been lectured on common peroneal nerve compression in the past? (in either classroom setting or clinical setting); **For Residents and Attendings only:** Have you diagnosed and treated a patient with common peroneal nerve compression in the past?

Sural Nerve Compression

A 65 year old woman presents with chronic pain and paresthesia in the posterolateral right leg and the lateral border of right foot. The discomfort is worse at night and with exertion. Patient reports history of recurrent right ankle sprain and fifth metatarsal fracture. You suspect sural nerve compression.

15. What additional studies would you obtain to confirm your diagnosis? (you may select more than one answer)
16. If you established the diagnosis of sural nerve compression, what treatment course would you recommend for this patient? (you may select more than one answer)
17. If you established the diagnosis of sural nerve compression, would you refer this patient for further management?
18. Assuming you would refer the patient, what specialty would you refer this patient to for further management? (you may select more than one answer)
19. **For Medical Students only:** Have you been lectured on sural nerve compression in the past? (in either classroom setting or clinical setting); **For Residents and Attendings only:** Have you diagnosed and treated a patient with sural nerve compression in the past?

Cubital Tunnel Syndrome

A 55 year old office manager with pain and paresthesia in the fourth and fifth digits of right hand and right elbow pain. The symptoms are worse at night and with prolonged right elbow flexion. Patient reports he spends a significant amount of time leaning his elbows at work. You suspect cubital tunnel syndrome.

20. What additional studies would you obtain to confirm your diagnosis? (you may select more than one answer)
21. If you established the diagnosis of cubital tunnel syndrome, what treatment course would you recommend for this patient? (you may select more than one answer)
22. If you established the diagnosis of cubital tunnel syndrome, would you refer this patient for further management?
23. Assuming you would refer the patient, what specialty would you refer this patient to for further management? (you may select more than one answer)
24. **For Medical Students only:** Have you been lectured on cubital tunnel syndrome in the past? (in either classroom setting or clinical setting); **For Residents and Attendings only:** Have you diagnosed and treated a patient with cubital tunnel syndrome in the past?

Deep Peroneal Nerve Compression

A 55 year old non diabetic male presents with pain and paresthesia over the dorsum of right foot and the first dorsal webpace. The pain is worse with right plantar flexion. You suspect deep peroneal nerve compression (anterior tarsal syndrome).

25. What additional studies would you obtain to confirm your diagnosis? (you may select more than one answer)
26. If you established the diagnosis of deep peroneal nerve compression, what treatment course would you recommend for this patient? (you may select more than one answer)
27. If you established the diagnosis of deep peroneal nerve compression, would you refer this patient for further management?
28. Assuming you would refer the patient, what specialty would you refer this patient to for further management? (you may select more than one answer)
29. **For Medical Students only:** Have you been lectured on deep peroneal nerve compression in the past? (in either classroom setting or clinical setting); **For Residents and Attendings only:** Have you diagnosed and treated a patient with deep peroneal nerve compression in the past?

For Residents and Attendings only

30. In the past year, how many patients did you refer to orthopedic surgeons for lower extremity neuropathy?
31. In the past year, how many patients did you refer to plastic surgeons for lower extremity neuropathy?
32. In the past year, how many patients did you refer to orthopedic surgeons for upper extremity neuropathy?
33. In the past year, how many patients did you refer to plastic surgeons for upper extremity neuropathy?

Table 1. Referral Pattern by Medical Students

Referral Specialty of Choice/ Clinical Scenario	Carpal Tunnel Syndrome	Common Peroneal Nerve Compression	Sural Nerve Compression	Cubital Tunnel Compression	Deep Peroneal Nerve Compression
Orthopedic Surgery	63.4%	54.3%	68.1%	49.5%	61.7%
Neurosurgery	6.8%	15.9%	12.8%	10.8%	14.3%
Plastic Surgery	5.8%	1.2%	1.4%	2.7%	2.3%
General Surgery	5.2%	6.1%	6.4%	2.7%	2.3%
Vascular Surgery	0.0%	1.8%	2.1%	0.0%	5.3%
Physical Medicine and Rehabilitation	39.3%	42.7%	34.8%	43.2%	34.6%
Anesthesiology	2.1%	0.0%	0.7%	2.7%	1.5%
Chronic Pain Specialist	7.9%	6.1%	16.3%	9.0%	9.0%
Sports Medicine	9.4%	11.6%	12.8%	9.0%	9.0%
Neurology	17.8%	40.2%	31.2%	30.6%	35.3%
Dermatology	0.5%	0.0%	0.0%	0.0%	0.8%
Other	4.2%	1.2%	0.7%	2.7%	0.8%

Table 2. Percentages of Medical Students Selecting Plastic Surgery for Referral for Peripheral Neuropathy Based on Prior Exposure to Plastic Surgery

Clinical Scenario/ Prior Exposure to Plastic Surgery	Prior Plastic Surgery Exposure (N=26)	No Prior Plastic Surgery Exposure (N=163)	P value
Carpal Tunnel	35%	1%	0
Common Peroneal Nerve	8%	0%	0.000865
Sural Nerve	9%	0%	0.001315
Cubital Tunnel	16%	0%	0.000112
Deep Peroneal Nerve	13%	0%	0.000127

Image 2. Medical Students' Exposure to Different Surgical Specialties by End of 4th Year

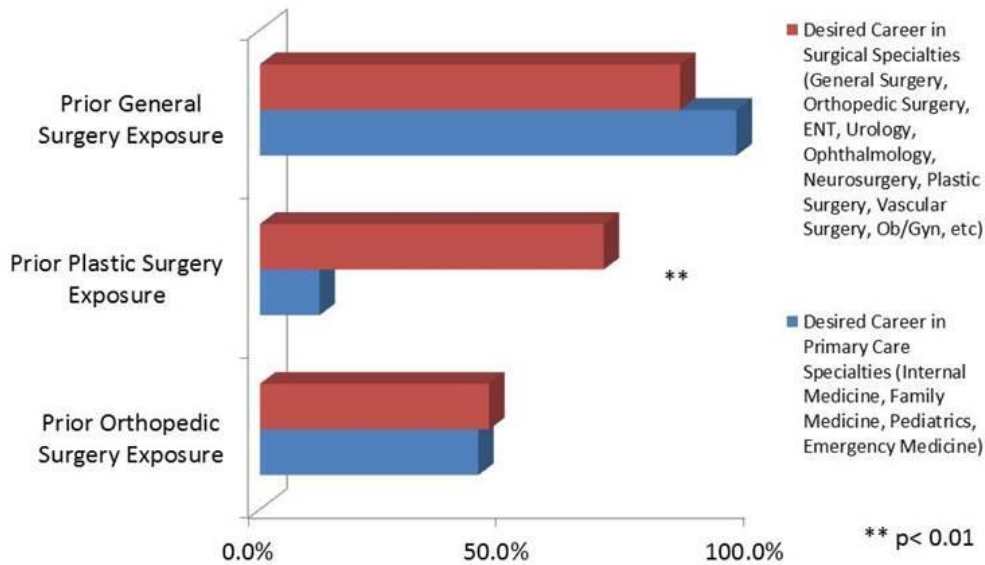


Table 3. Referral Pattern by Primary Care Attendings and Residents

Referral Specialty of Choice/ Clinical Scenario	Carpal Tunnel Syndrome	Common Peroneal Nerve Compression	Sural Nerve Compression	Cubital Tunnel Compression	Deep Peroneal Nerve Compression
Orthopedic Surgery	72.3%	45.7%	60.5%	48.5%	46.9%
Neurosurgery	0.0%	15.2%	18.4%	9.1%	12.5%
Plastic Surgery	6.4%	2.2%	0.0%	0.0%	0.0%
General Surgery	0.0%	0.0%	0.0%	0.0%	0.0%
Vascular Surgery	0.0%	2.2%	2.6%	0.0%	3.1%
Physical Medicine and Rehabilitation	25.5%	39.1%	42.1%	42.4%	40.6%
Anesthesiology	0.0%	2.2%	0.0%	3.0%	3.1%
Chronic Pain Specialist	4.3%	4.3%	10.5%	3.0%	6.3%
Sports Medicine	2.1%	6.5%	15.8%	12.1%	6.3%
Neurology	6.4%	32.6%	18.4%	15.2%	21.9%
Dermatology	0.0%	0.0%	0.0%	0.0%	0.0%
Other (please specify)	21.3%	8.7%	5.3%	9.1%	9.4%

ASPN/ASRM Combined Scientific Paper Session

ASPN #1 Pain after Breast Surgery Related to Intercostal Nerves

Eric H. Williams, MD¹; Justin M. Broyles, MD¹; Andrew G. Taylor, BS²; Laurence Glickman, MD³; A. Lee Dellon, MD, PhD¹

¹Johns Hopkins University, Towson, MD; ²Dellon Institute for Peripheral Nerve Surgery, Towson, MD; ³Long Island Plastic Surgery, Long Island, NY

Purpose: Breast procedures are amongst the most common surgeries done by Plastic Surgeons. While most aspects related to augmentation, reduction and reconstruction have been described well, prevalence of post-operative, persistent pain remains unknown and outcomes related to surgical approaches remains unreported. Our experience has been that persistent post-operative breast pain is related to the intercostal nerves, and the purpose of this presentation is to increase awareness of the existence of this problem and approaches to relieve this pain.

Methods: A retrospective analysis of the patients of four surgeons involved with peripheral nerve surgery was done. Descriptive analysis was utilized. The cohort contained 11 patients stratified according to the index surgical procedure: augmentation (3), reduction (1), lumpectomy (1), reconstruction (6). Outcomes were assessed with a numerical analog score, with a minimum pain score improvement of > 3 out of 10 points. Physical examination demonstrated painful trigger points along the pathway of one or more intercostal nerves. Prior to surgery, each patient improved > 5 points after a xylocaine/Marcaine local anesthesia block of the suspected intercostal nerves. At surgery, one or more intercostal nerves were resected and implanted into adjacent muscles (serratus or latissimus).

Results: At a mean of 22.3 months (3 to 58 month range), there were 6 excellent, 3 good, and 2 poor results. Intercostal nerves resected included the intercostal-brachial (5 patients), 3rd (10 patients), 4th (6 patients), 5th (9 patients), 6th (7 patients), 7th (1 patient). Multiple intercostal nerves were resected as follows: 2 nerves (6 patients), 3 nerves (3 patients), 4 nerves (1 patient), 5 nerves (1 patient). There were no post-operative complications.

Conclusions: Intercostal neuromas can be the source of breast pain following Plastic Surgery procedures. The same clinical and diagnostic approach can be used in patients with breast pain as in patients with upper or lower extremity pain. Plastic Surgeons whose practice pattern includes breast surgery should be aware of hope for their patients with chronic post-operative pain by applying a Peripheral Nerve Surgery approach.

ASPN #2 Influence Of Surgical Video Education On Operative Efficiency And Competency In Novice Surgeons: A Randomized Controlled Trial

Amanda M. Gryniewicz, MS; Andrew Yee, BS; Elspeth Hill, MD, MRes, PhD; Kevin Z. Li, BA; Susan E. Mackinnon, MD; Ida K. Fox, MD

Washington University School of Medicine, Saint Louis, MO

Purpose: Surgical training adheres to an apprenticeship model and requires countless hours of training for a surgeon to learn and perform a technical procedure with proficiency. With the implementation of the 80-hour work week and other factors, there has been increased pressure for residents to learn efficiently and become technically competent in more limited time. Video education is a potential new method of surgical training, yet the direct procedural implications of instructional videos have not been assessed. The purpose of this study is to quantify the educational impact of the instructional surgical videos on residents when performing a procedure independently.

Methods: After obtaining institutional review board approval, study participants were recruited from surgical residents in their first/second year of their residency to perform a carpal tunnel release (CTR) as the primary surgeon in a cadaver model. No previous experience with the CTR surgery was allowed.

Participants completed a number of steps, including a pre- and post-intervention survey (to assess baseline knowledge) and an objective assessment of baseline surgical skill. Participants were randomized to one of three study intervention groups: (1) surgical textbook, (2) surgical video, and (3) surgical textbook and video. Following the intervention, they performed a videotaped carpal tunnel release in a cadaver model. Blinded reviewers graded participants on a previously validated global surgical skill and technique scale, and then CTR-specific factors (placement of incision, degree of release, and presence of collateral damage) were reviewed. Following the cadaver operation, participants graded themselves on the two scales of operative performance for comparison and were administered a post-procedural survey on their learning experience.

Results: Quantitative results are pending. Preliminary data strongly suggest that novice surgeons who were administered the surgical video intervention demonstrated a significant advantage over those who were administered the surgical textbook alone. We anticipate differences in technical efficiency, competency, and retention of step-by-step knowledge of the procedure.

Conclusion: Surgeons are time-pressured individuals that require an efficient and effective resource that describes the technical nuances of a procedure. While traditional text resources are today's standard, surgical videography is becoming more mainstream due to the recent adoption and integration of new camera technologies in the operating room and the advantages of this more visual and efficient learning experience. Further advances in surgical video education could ultimately have distinct implications for continuing medical education as well as resident case preparation, technical knowledge, and patient outcomes.

ASPN #3 Secondary Surgery following Gracilis Muscle Transplantation for Facial Paralysis in Children

Tommy Nai-Jen Chang, MD; Erin Klar; Emily S. Ho; Gregory H. Borschel, MD; Ronald M. Zuker, MD

The Hospital for Sick Children, University of Toronto, Toronto, Canada

Introduction: There is a paucity of literature on revision and ancillary procedures conducted in children following gracilis muscle transplantation for facial paralysis using cross-face nerve graft or motor nerve to masseter muscle. The purpose of this study was to characterize the secondary surgical procedures conducted at a single tertiary urban paediatric hospital in children following gracilis muscle transplantation for facial reanimation.

Materials and Methods: A retrospective case series was conducted on all children born after January 1979 that required secondary surgery following gracilis muscle transplantation that was performed prior to January 2014. Surgical procedures were categorized into 1. complete revisions of either the cross-face nerve graft or gracilis free flap, and 2. ancillary procedures for aesthetic and functional concerns. Secondary procedures related to immediate post-op swelling, infection or abscess drainage were excluded.

Results: Twenty-seven children required secondary surgery. Twenty-two (81%) patients had primary reconstruction of the gracilis muscle transplantation using cross-face nerve graft, and 5 (19%) had motor nerve to masseter muscle. There was no difference in the distribution of children with respect to the location of initial surgery and etiology (acquired or congenital) between the two surgical approaches. However, a higher proportion of males and bilateral cases had masseter-innervated gracilis transplantation. Thirty secondary procedures were conducted on the 27 children. Average age at the time of surgery was 11.6 + 4.4 years (5.1 - 19.4 years). Eighteen procedures (60%) were conducted on children who had primary surgery for facial reanimation at an outside institution. Sixteen (53%) complete revisions were conducted: 4 isolated cross-face nerve graft and 12 gracilis flap with or without revision of cross-face nerve graft. Complete revisions were not required for masseter-innervated cases. Fourteen ancillary procedures were conducted including debulking, adhesiolysis, scar revision, and muscle repositioning.

Conclusion: Complete revisions and ancillary procedures following paediatric gracilis muscle transplantation were equally common. This series included children referred to our centre after their primary procedure. Complete revisions were required following cross-face nerve graft and gracilis muscle transplantation, but not in cases that used the motor nerve to masseter muscle to innervate the gracilis.

ASRM #1 Extended Periarterial Sympathectomy: Evaluation of Outcomes

Collier Stephens Pace, MD; Wyndell Merritt, MD

VCU Medical Center, Richmond, VA, USA

Introduction: Periarterial sympathectomy is a proposed surgical treatment for patients who fail medical management of Raynaud Syndrome, however there is little agreement regarding the indications or extent of dissection. Due to the segmental nature of arterial sympathetic innervation, we routinely perform an extended periarterial sympathectomy which includes adventectomy of the ulnar artery starting 8-10cm proximal to the wrist crease (including the nerve of Henle), the superficial arch, common volar vessels, 3-5mm of the proper digital arteries, and the dorsal radial artery through the anatomic snuff box to the first dorsal interosseous muscle. This is done in concert with vein graft reconstructions of occluded radial or ulnar arteries. The purpose of this study is to examine the outcome of extended periarterial sympathectomy in our patients. We hypothesize that the majority of patients, after failing medical management, will demonstrate improvement in ischemic pain and sensibility, along with healing of digital ulcerations.

Methods: A retrospective chart review was performed on 40 patients who underwent 48 periarterial sympathectomies (8 bilateral) since 1980. The data collected include: demographics, comorbidities, previous therapy, operative details, and surgical outcomes. Additionally, we contacted available patients for a phone survey.

Results: Of the 48 cases, 64.6% were female, 43.8% were former or current smokers, and 50% had known connective tissue disease. Vein graft reconstructions were performed in 21 of 25 cases with radial or ulnar artery occlusions. Ischemic pain improvement was reported in 93.8% of cases, and 66.7% completely healed all digital ulcers or amputation stumps after a single operation. Of the 31 cases where amputation was unnecessary (64.6%), 21 had Semmes Weinstein Monofilament (SWM) testing data available. For the most symptomatic finger tip, mean SWM sensibility improved from 4.37 preoperatively, to 3.48 postoperatively ($p=.0009$). Mean follow-up was 2.6 years. Of 6 patients contacted by telephone, all reported a decrease in frequency and severity of Raynaud attacks, while 5 of the 6 patients reported a decrease in pain.

Conclusions: Extended periarterial sympathectomy is an effective procedure for ischemic pain and digital ulceration in patients with Raynaud Syndrome who fail medical management. Our data demonstrate long-term improvement in ischemic pain and sensibility, along with a high rate of ulcer healing and patient satisfaction. Patients with Raynaud Syndrome, and their health care providers, should be educated regarding the potential benefits of periarterial sympathectomy to optimize outcomes for this challenging condition.

ASRM #2 Facial Nerve Axonal Analysis and Anatomic Localization of Donor Nerve - Optimizing Axonal Load for Cross Facial Nerve Grafting in Facial Reanimation

Austin Hembd, MS¹; Purushottam Nagarkar, MD¹; Salim Saba, MD²; Dinah Wan, MD¹; Brandon Isaacson, MD¹; J. Walter Kutz, MD¹; Sachin Gupta, MD¹; Charles White, MD¹; Shai Rozen, MD¹

¹UT Southwestern Medical Center, Dallas, TX; ²American University of Beirut

Introduction: Several variables may affect aesthetic and functional outcomes of the cross facial nerve graft followed by a free muscle transfer for facial reanimation. Previous studies by independent groups demonstrated that among the more important variables effecting improved outcome was axonal load of the donor nerve. Axonal counts of 900 and above correlated to improved function but localization of this point along the nerve has not been previously described. This study attempts to measure the axonal counts of the facial nerve branches innervating the zygomaticus major muscle at multiple points along their paths to determine the ideal anatomic location for harvest.

Methods: 14 fresh unpreserved cadaveric heads (28 hemi-faces) were dissected to expose the facial nerve from the stylomastoid foramen to terminal branches into the mimetic muscles. The zygomatic branches were harvested in 2 cm sections from the pes anserinus to muscle insertion, noting the position of the nerve relative to anatomic landmarks (zygomatic arch, posterior border of ramus, lateral border of zygomaticus major, and the parotid gland) at each point. Nerve samples were paraffin fixed, sectioned, and stained with SMI-31 anti-neurofilament stain, thereafter scanned and analyzed for axonal counts using an Aperio Digital Pathology scanner and ImageScope software (Leica Biosystems Inc., Buffalo Grove IL). Manual verification of counts was carried out on a randomly selected sample of nerve sections. Data analysis was carried out in Microsoft Excel (Microsoft Corp, Redmond WA).

Results: The mean axonal number at the pes anserinus was 4220. Every facial nerve specimen had multiple branches innervating the zygomaticus major. 27 of 28 specimens had at least one extra-parotid zygomatic branch with greater than 900 axons—10 specimens had one branch, 16 had two and one specimen had three branches. A branch with greater than 900 axons could be found at a mean of 46mm anterior to the posterior border of the ramus, 13mm below the arch, and 14mm from the lateral border of the zygomaticus major. The likelihood of finding an adequate branch in a 30x20mm rectangle around this mean location (i.e. 30 to 60mm from the posterior border of the ramus and 5 to 25mm below the arch) was 85%.

Conclusion: Zygomatic branches with adequate axonal load as donor nerves for facial reanimation procedures can be found in most specimens. Intraparotid dissection is rarely necessary. Branches with adequate axon counts can be reliably found within the 30x20mm area described above.

ASRM #3 Sensory Recovery in Neurocutaneous Flaps for Heel Reconstruction Using End-To-Side Neurrorhaphy

Xuecheng Cao, MD

Jinan Military General Hospital, Jinan, China

Purpose: To retrospectively investigate the outcome of sensory recovery in neurocutaneous flaps after reversed transferring for foot heel reconstruction and end-to-side neurrorhaphy.

Clinical Materials: Eleven foot heel defect patients were included for the study, with the age ranged from 24 – 45 and averaged 32 years old. Of these, 9 suffered from traumatic defect, and 2 for congenital reason (myelomeningocele). The sural nerve, which was isolated and incised about 5 cm long proximally to the flap, after conventionally reversed transferring of the flap to the heel, was end-to-side anastomosed to the tibial nerve (with windowed) at the medial ankle. Ten patients were followed-up for at least 6 months. All the flaps were survived. The sensory recovery was assessed by patient satisfaction and static two-point discrimination.

Results: Sensory recovery began at one month after operation, and at 6th month, the two-point discrimination was 1.5 ± 0.3 cm. the patient satisfactory rate was high.

Conclusion: Sensory reconstruction by end-to-side Neurrorhaphy for distally-based neurocutaneous flaps for foot heel repair is a reliable method.

Scientific Paper Session IV

37. The Use of Processed Nerve Allografts for Management of Localized Pain in the Foot and Ankle

Jason M. Souza, MD; Chad A. Purnell, MD; Andrew W. Choi, BS; Gregory A. Dumanian, MD, FACS
Northwestern University, Feinberg School of Medicine, Chicago, IL

Background: Localized nerve pain in the foot and ankle has received increased attention as a source of chronic disability after trauma. It has also been identified as the most common complication following orthopedic and podiatric interventions in the foot and ankle. The superficial location of the injured nerves and lack of suitable tissue for nerve implantation and burial frequently make this pain refractory to conventional methods of neuroma management. Here we describe a novel strategy for management of painful nerve injuries in the foot and ankle using processed nerve allografts to bridge nerve gaps created by resection of both end neuromas and neuromas-in-continuity.

Methods: We carried out a retrospective review of a prospectively maintained database of all patients who received a processed nerve allograft for treatment of painful neuromas in the foot and ankle between May 2010 and December 2014. Patient demographic and operative information was obtained, as well preoperative and postoperative pain assessments using both a conventional ordinal scale, as well as PROMIS (Patient Reported Outcomes Measurement Information System) Pain Behavior and Pain Interference assessments.

Results: 26 patients were identified, with postoperative pain assessments occurring at a mean of 15 months after surgery. Injuries to the sural (10) and superficial peroneal (8) nerves were the most common diagnoses, with 3cm nerve allografts being used as the interposition graft in the majority of cases. Preoperative pain was severe in these 26 patients, with a mean pain score of 7.6/10 on an ordinal scale. Preoperative PROMIS Pain Behavior and Pain Interference scores corresponded to the 89th and 92nd percentiles with respect to the general population. Eight patients had end neuromas and 18 patients had neuromas in continuity. Postoperatively, patients reported an ordinal pain score of 5.0/10, with Pain Behavior and Pain Interference scores in the 59th and 57th percentile, respectively. When the data were paired, ordinal pain scores decreased by a mean of 2.3, while Pain Behavior scores decreased by 25 percentage points and Pain Interference decreased by 33.6 percentage points. All changes were significant ($p < 0.005$).

Conclusion: The painful sequelae of superficial nerve injuries in the foot and ankle can be effectively managed with complete excision of the involved nerve segment followed by bridging of the resulting nerve gap with a processed nerve allograft. This approach limits surgery to the site of injury, while providing a means with which to reconstitute the peripheral nerve anatomy and facilitate coordinated nerve regeneration.

38. Short-term Outcomes of the Nerve "Dwindling" Procedure using Long Processed Nerve Allograft in Recurrent Lower Extremity Neuroma

Emily M. Krauss, MD, MSc; Amy M. Moore, MD; Aouod Agenor, MD; Susan E. Mackinnon, MD
Washington University School of Medicine, Saint Louis, MO

Introduction: Lower extremity neuroma pose a therapeutic challenge due to high recurrence and significant psychological and social impact from chronic pain. Surgical procedures for neuroma range from simple excision to transposition and implantation into muscle and bone. We propose a novel surgical procedure for difficult to treat recurrent lower extremity neuroma using a long processed nerve allograft, based on the findings of length-dependent loss of axonal regeneration potential through processed nerve allografts.

Materials and Methods: Adult patients with symptomatic recurrent lower extremity neuroma without concomitant neuropathy were included in this study. Preoperative history and physical examination were performed including preoperative Visual Analogue Scales assessing pain and quality of life, and the Short Form 8 (SF-8) Health Survey. The symptomatic nerve territory was explored and the neuroma was identified and excised. A proximal crush injury was performed using a hemostat to elicit a second degree regenerative injury. AxoGen-processed nerve allograft, length 2.5 cm (1 patient), 3 cm (1 patient) to 5 cm (8 patients), was microsurgically coapted to the free nerve end and transposed proximally, tension-free, outside of the original zone of injury. Patients were immobilized in a bulky dressing in the initial post-operative period and assessed at 1-2 weeks, 6 weeks, 3 and 6 months post-operatively.

Results: Ten (10) patients with isolated recurrent lower extremity neuroma were treated surgically. Nine patients had more than two previous surgical procedures for their neuroma prior to consultation at our institution. Offending neuroma were located in the plantar web-space (3 patients), superficial peroneal (4 patients), saphenous (2 patients), and sural nerve territories (2 patients).

Life-altering pain was the presenting complaint of all patients in the study. Preoperative mean pain score was 7.8 out of 10, with a mean 76.8% negative impact on quality of life. Although the initial post-operative period illustrated significant variability in pain scores and quality of life impact, by three months post-operative the majority of patients reported improvement in quality of life, ranging from a 10-50% improvement compared to the preoperative period. Patients reporting quality of life improvement had a corresponding, although less dramatic, improvement in reported pain score on the Visual Analogue Scale.

Conclusions: Using long processed nerve allografts to constrain and redirect regenerating nerve fibers far outside of the zone of injury shows promise in short-term follow-up to reduce pain and improve quality of life in difficult to treat recurrent lower extremity neuroma.

39. The Management of Chronic Pain Caused by Peripheral Nerve Lesions: a Novel Application of Human Cadaveric Allografts

Jonathan I. Leckenby, MBBS, BSc, MRCS; Bettina Juon Personeni, MD; Curdin Furrer, MD; Esther Voeglin, MD
Inselspital University of Bern, Bern, Switzerland

Introduction: Chronic pain resulting from peripheral nerve lesions represents a difficult patient group to manage. After traditional conservative treatments have been exhausted, surgical intervention may be indicated. Surgical exploration and excision of the lesion can necessitate the use of grafts to ensure a tension free repair is achieved. Even though autologous grafts are the gold standard, their use may not be applicable due to the donor site morbidity and the risk of creating a secondary local or regional neurogenic pain problem. We present our 6 year experience of using Avance™ allografts to manage this patient group.

Methods: Data was collected prospectively for all patients who received an allograft repair of a peripheral nerve. The inclusion criteria for this study were as follows: to have surgical repair more than 21 days following injury, failed conservative treatment except in iatrogenic nerve lesions, have pre-operative pain and have a minimum follow-up of six months. Pre- and postoperative data was collected using the Numeric Rating Scale (NRS) for pain and both the modified Medical Research Council Classification (MRCC) and Semmes-Weinstein Monofilament (SWM) mapping. In all cases an ultrasound guided local anesthetic infiltration was performed on at least two occasions to verify that there was a neurogenic cause and where indicated were investigated with allodymography.

Results: A total of 77 allografts were used of which 33 fulfilled the inclusion criteria. 18 grafts were used to reconstruct digital nerve defects, 8 for upper limb defects and 7 for lower limb defects. The mean time interval between injury and reconstruction was 825 days (21-5968) with an average follow-up of 373 days (180-610). The mean pre-operative pain score was 5.6 (3-10) and the mean post-operative score was 2.2 (0-8); this was a significant improvement ($p < 0.001$). 67% of patients had a meaningful recovery and there was a significant improvement in two-point discrimination post-operatively ($p = 0.003$).

Conclusions: This study supports the use of allografts in chronic pain caused by peripheral nerve injuries. Both post-operative pain scores and improvement in sensibility were significantly better. The results suggest that early surgical intervention yields more favourable outcomes however this was not statistically significant ($p = 0.12$). Overall, allografts achieve excellent post-operative results and careful selection of patients is crucial in order for them to benefit from what is essentially elective surgery.

40. Regenerative Peripheral Nerve Interfaces for Neuroma Relief in Humans

Shoshana L. Woo, MD; Theodore A. Kung, MD; Paul S. Cederna, MD

University of Michigan, Ann Arbor, MI

Introduction: Regenerative peripheral nerve interfaces (RPNI) are nerve-muscle constructs that were originally designed for prosthetic control. Incidentally, by providing denervated muscle graft targets for peripheral nerve ingrowth, we have noted the additional benefit of neuroma prevention in our animal experiments. This technology has since been brought into the clinical realm. The current study describes the first series of human patients undergoing RPNI implantation for treatment of symptomatic neuromas.

Methods: This retrospective case series encompasses all patients who underwent RPNI implantation for treatment of symptomatic neuromas of the upper and lower extremities by a single surgeon between November 2013 and June 2015. Under institutional IRB approval, data were obtained via chart review and phone interviews using questions adapted from the publically available PROMIS instruments. Patient-reported outcomes were assessed for those with at least 3 months of follow-up.

Results: During the study period, 45 RPNI were implanted into the residual limbs of 16 amputees for neuroma relief (3 upper extremity, 13 lower extremity). Mean age was 53.5 years (range 30-76), with 7 females and 9 males. There were no major immediate complications except for 1 case of deep venous thrombosis in the context of baseline preoperative thrombophilia. There were 12 patients with at least 3 months of follow-up. All patients participated in a single phone interview conducted at an average of 8.0 ± 3.7 months postoperatively (range 3-19 months). Reported complications included delayed healing that resolved with local wound care (33%) and neuroma development in a new location (17%). Using the numeric pain rating scale (0-10), patients reported preoperative pain scores of 8.8 ± 1.6 for neuroma pain and 8.4 ± 2.3 for phantom pain. After surgical recovery, these pain scores dropped to 3.0 ± 2.2 and 4.28 ± 1.6 , respectively. Most patients described their satisfaction with RPNI surgery as “very high” or “high” (75%), indicating either a decreased (50%) or stable (50%) amount of analgesic medication use. The majority of patients would strongly recommend the surgery to a friend (83%) and would choose to do it again if given the option (92%).

Conclusions: We report the first human case series in which RPNI have been used to treat symptomatic neuromas. Results are promising, as the majority of patients have reported decreased pain scores and a high level of satisfaction after surgical recovery.

41. Surgical Peripheral Nerve Decompression for the Treatment of Diabetic Neuropathy of the Foot - A Randomized Controlled Trial

Timothy Best, MD, MSc; Corliss A. Best, MSc; Alyssa A. Best, BSc, MSc; Luke Fera, MD, BSc
Northern Ontario School of Medicine, Sudbury, ON, Canada

Purpose: Surgical decompression of the major peripheral nerves innervating the foot has been proposed as a treatment for diabetic peripheral sensorimotor polyneuropathy (DSP). This condition is a major cause of pain and disability in diabetics, and imposes a large economic burden to the health care system. Nonoperative treatment options to date are often ineffective. Case series have demonstrated the potential for nerve release surgery to alleviate pain in these patients, but to date no blinded study has been reported. The American Academy of Neurology has cautioned that this surgery is to be considered experimental and unproven, albeit promising. We conducted a blinded, randomized controlled trial to test the null hypothesis that surgical decompression of the common peroneal, deep peroneal, and tibial nerves has no benefit in ameliorating the symptoms of DSP.

Methods: 22 adult diabetics with good glycemic control, diagnosed to have DSP and no other identifiable cause of neuropathy, or other contributors to their foot pain, and an average pain score on a 10 point Likert scale of 5 or greater were studied. Consenting subjects were allocated to a study group using a simple blinded randomization technique. Control subjects received their standard medical care; operative subjects underwent surgical decompression. Evaluations were performed by a blinded, trained study nurse at 3, 6, 9, and 12 months for both groups. Symptoms including pain, clinical signs including vibration detection, nerve conduction studies, and quality of life questionnaires were evaluated.

Results: The average pain scores for the operative group over time were significantly lower than the control group, ($p=0.04$), and the null hypothesis was rejected. Results for the secondary outcome measures are being analyzed and will be included in the presentation.

Conclusions: In this blinded randomized controlled trial, surgical decompression of the common peroneal, deep peroneal and tibial nerves significantly reduced pain for patients with DSP.

42. WITHDRAWN

43. Surgical Decompression for Peroneal Neuropathy after Total Joint Arthroplasty

Grant M. Kleiber, MD; Susan E. Mackinnon, MD

Washington University School of Medicine, St. Louis, MO

Introduction: Total hip arthroplasty (THA) and total knee arthroplasty (TKA) are associated with numerous complications such as infection, venous thromboembolism, hardware failure, and nerve injury. Peroneal neuropathy is an uncommon but troubling complication of THA and TKA. Patients present with foot drop, pain, or both. This study examines the efficacy of common peroneal nerve decompression at the fibular head as a treatment of peroneal neuropathy resulting from hip or knee arthroplasty.

Methods: Thirty-eight patients treated surgically over a 6-year period for peroneal neuropathy secondary to THA or TKA were retrospectively identified. Medical records were reviewed with respect to surgical history, subjective pain questionnaires, dorsiflexion strength, and preoperative electromyography (EMG). Significant improvement in motor function was defined as attaining a modified MRC grade of greater than 3. Improvement in pain was defined as a pain score and quality of life impact score decreasing by at least 3 points. Potential predictive factors were identified such as gender, age, THA vs TKA, time since arthroplasty, and presence of motor unit potentials (MUPs) on EMG. Statistical significance was determined using Fisher's exact test.

Results: Patients presented for evaluation at our nerve center on average 10 months after arthroplasty. Foot drop was reported in 35 patients, and pain in 30. Out of 35 patients presenting with foot drop, 31 had abnormal EMG studies and, of these, 15 showed MUPs. Presence of MUPs was found to be a significant predictor of motor recovery after nerve decompression ($p < 0.0004$), with recovery of dorsiflexion in 13/15 patients (87%) with MUPs compared to only 2/17 (12%) without MUPs. Patients with a history of TKA were more than twice as likely to recover motor function after decompression as those who underwent THA (71% vs 32%, $p < 0.038$). Decompression had a greater impact on improvement of pain than recovery of motor function, with 22/30 patients (73%) experiencing a significant improvement in pain and 17/35 patients (49%) showing improvement in foot drop. No factors were found to correlate significantly with pain improvement.

Conclusions: Surgical decompression of the common peroneal nerve is a potential treatment for peroneal neuropathy after hip or knee arthroplasty. Patients presenting with foot drop following total knee arthroplasty are more likely to recover motor function after peroneal nerve decompression than those who present following total hip arthroplasty. Peroneal decompression is more efficacious for treating pain than foot drop. EMG is a valuable predictive measure to determine the likelihood of motor recovery after surgical decompression.

44. Management of Terminal Nerve Endings In Below Knee Amputation to Prevent Neuroma Formation; Primary End-to-End Coaptation, Muscle Implantation, or Targeted Re-innervation

John R. Barbour, MD

Georgetown University, Washington, DC

Introduction: Management of sensory nerve endings at the time of below the knee amputation is critical to prevent painful neuroma formation. Following transection, injured cutaneous nerves are exposed to a number of influences that can lead to unfavorable outcomes. Poor outcomes can be attributed to scar formation within the nerve as well as tethering of the nerve to surrounding tissue. While the events are multi-factorial, a common basis for neuroma formation is disorganized growth of axon cylinders into proliferating granulation tissue. Neuroma formation has been shown to be preventable by an epineural sleeve, implantation into muscle fibers, or neural coaptation to adjacent nerve fascicles. Isolation of a nerve from its surrounding environment may prevent scar ingrowth, minimize potential for nerve entrapment, and reduce the impact of aberrantly regenerating nerve fibers. We present a comparison of techniques for terminal nerve protection to provide an environment resistant to neuroma formation and reduce the risk of stump neuroma.

Materials and Methods: Eighteen patients underwent staged below-the-knee lower extremity amputation following trauma or vascular insufficiency. All patients reported pre-operative pain as measured on a visual analog scale. Identified nerves were the superficial peroneal, deep peroneal, posterior tibial, distal sural nerve. All patients underwent excision of the terminal nerve endings, proximal neuroplasty to avoid the area of trauma, and either muscle implantation of the nerve endings (n=6), primary end-to-end coaptation of the primary nerve endings (n=7), or targeted reinnervation of the terminal nerve endings into adjacent motor nerve trunks (n=5). Patients were followed for a minimum of six months (range 6-14 months).

Results: Standardized pain questionnaires were collected on each patient at most recent follow-up. The mean pre-operative pain score on a 0-10 scale for all patients was $7.2 \pm 1.4/10$, and most patients reported neuropathic symptoms (burning, stabbing) on selected descriptive word associations (n=11). Mean post-operative pain scores were all reduced and the average reduction was 5.7 ± 0.7 points. All patients reported a reduction of pre-operative pain and no patients have reported recurrence of symptoms (n=18, mean score 2.1 ± 0.6 points).

Conclusions: Prevention of stump neuroma is critical for maximal functional status following extremity amputation. In patients with expendable motor fascicles for targeted reinnervation, this represents an excellent option. Intra-muscular implantation or nerve coaptation are also effective but resulted in higher post-operative pain scores in this study. These techniques all represent safe and reasonable options for protection of the distal nerve and prevention of stump neuroma following amputation.

45. Prevention of Painful Neuroma and Phantom Limb Pain Following Transfemoral Amputation Through Concomitant Nerve Coaptation and Collagen Nerve Wrapping

James Economides, MD; Michael DeFazio, MD; John Barbour, MD
Georgetown University Hospital, Washington, DC

Introduction: Post-amputation pain (PAP) following above-knee amputation (AKA) presents a variable composite of residual limb and phantom sequelae that often compromise prosthetic tolerance, functional independence, and quality-of-life after limb loss. Recent appreciation for the contribution of peripheral nerve pathology in the development of PAP has led to an increased focus on the primary prevention of neuroma formation. We propose a novel method involving concomitant tibial (TN) and common peroneal nerve (CPN) coaptation, collagen nerve wrapping, and submuscular transposition at the time of amputation as a means to prevent residual limb pain and phantom sequelae resulting from neuroma formation.

Methods: A retrospective review of 17 patients who underwent AKA at a single institution from May 2014 through May 2015 was performed. Patients were separated into 2 cohorts for purposes of comparison; (1) Experimental: those who underwent coaptation of CPN to TN, collagen nerve wrapping, and submuscular transposition and (2) Control: those who underwent traction neurectomy alone. Post-operative visual analog pain scores, neuropathic pain medication use, neuroma formation, phantom limb sequelae, ambulatory status, and prosthesis use were compared between cohorts.

Results: Six patients underwent combined nerve coaptation and collagen nerve wrapping, whereas 11 underwent traction neurectomy alone. Average follow-up was 6 months. After 2 months, VAS scores were similar between the two groups (3 vs. 3.82; $p=0.88$); however, rates of neuroma (0% vs. 36.3%; $p=0.24$) and phantom pain (0% vs. 63.6%; $p=0.01$) were significantly lower in the experimental group. Four months after amputation, mean VAS scores (0.75 vs. 5.6; $p=0.02$), as well as rates of neuroma (0% vs. 54.5%; $p=0.04$) and phantom pain (0% vs. 63.6%; $p=0.01$) were significantly lower among patients who underwent peripheral nerve coaptation and collagen nerve wrapping. At final follow-up, rates of prosthetic limb use and ambulation for patients in the experimental and control groups were each 50% and 9% ($p=0.09$), respectively. The use of neuropathic pain medication; however, was noted to be similar in both cohorts (50% vs. 36%; $p=0.64$).

Conclusion: Concomitant peripheral nerve coaptation and collagen nerve wrapping is associated with lower VAS pain scores, phantom pain, and neuroma formation when compared to traction neurectomy alone. Benefits from this approach were observed as early as 2 months postoperatively and were maintained through follow-up at 6 months. The overall improvement in residual limb pain and phantom symptoms has real world application as these patients are more likely to tolerate a prosthetic limb and ultimately ambulate.

46. Evaluation of Cold Sensitivity, Pain and Quality of Life after Upper Extremity Nerve Injury

Christine B. Novak, PT, MS, PhD(c)¹; Susan E. Mackinnon, MD²

¹University of Toronto, Toronto, ON, Canada; ²Washington University School of Medicine, St. Louis, MO

Background: Cold sensitivity with severe pain has been reported following upper extremity trauma and contributes to poor outcome and quality of life (QoL). The purpose of this study was to evaluate the relationship between reported cold sensitivity, pain and impact on QoL after upper extremity nerve injury. We hypothesized that: 1) cold sensitivity and pain would have a negative impact on QoL; 2) patients who select a single descriptor of “coldness” would have more pain, higher cold sensitivity scores and greater impact on QoL.

Methods: This cross sectional study included adults more than six months after an upper extremity nerve injury. Assessment included the Pain Evaluation Questionnaire (pain descriptors, questionnaire, pain intensity, impact on QoL), and Cold Intolerance Severity Scale (CISS). Statistical analyses evaluated the relationships between the Pain Evaluation Questionnaire, CISS and independent variables.

Results: There were 70 patients (mean age 42 ± 16 years). There were high levels of pain, cold sensitivity and impact on quality of life reported. Patients selecting the adjective “coldness” had significantly higher CISS scores ($p = 0.005$), pain intensity ($p = 0.008$) and impact on QoL ($p < 0.006$). Impact on QoL and CISS ($r = 0.35$) were moderately correlated. There were significant correlations ($p < 0.01$) between level of cold-induced pain and CISS ($r = 0.78$); overall pain intensity ($r = 0.58$); pain descriptor score ($r = 0.49$); impact on QoL ($r = 0.32$).

Conclusions: Cold-induced pain is associated with higher cold sensitivity scores and greater impact on QoL. Reporting a single descriptor of “coldness” and ranking cold-induced symptoms were strongly associated to higher cold sensitivity scores and impact on health-related QoL. This may have important implications for quick screening to identify patients with cold sensitivity and future studies in larger patient samples are necessary to provide additional evidence.

47. Rethinking CRPS - Undiagnosed Peripheral Neuropathy

Emran Sheikh, MD¹; Ednan Sheikh, MD²; Renata V Weber MD

¹Multi Disciplinary Specialists, Rutherford, NJ; ²NJ Pain & Spine, Rutherford, NJ

Background: Given the challenges with characterizing the pain and syndromic findings in reflex sympathetic dystrophy, the term RSD has been reclassified into chronic regional pain syndrome (type I and II). This subclassifies the patients with the pain syndrome into a type which may be due to a specific nerve pathology (type II) versus those without a determined causalgia (type I). The identification of those with type I versus II is based largely on clinical history and findings. These can be nonspecific and result in overdiagnosis (*Galer BS 1999*). If no other diagnosis is specifically found, the pain is often labeled as CRPS. Furthermore, performing nerve conduction studies is difficult given the pain intensity and area.

Methodology: We reviewed our adult patients with limb pain with parasthesias (2012-2014). Patients who were diagnosed with carpal tunnel syndrome confirmed with nerve conduction testing were excluded. Thirty-three patients underwent surgical intervention after failing nonoperative treatment for clinical diagnoses of peripheral nerve compression.

Results: Of the thirty-three patients, twenty-five patients had presenting criteria for CRPS as defined by the modified International Association for the Study of Pain (*Harden RN, 2007*). One patient was excluded due to incompleteness of treatment. Twenty-one patients had an identifiable neck or limb trauma.

Of the 24 patients diagnosed with peripheral nerve compression, 20 involved the upper limb versus 4 lower limb. 75% patients underwent ulnar neuroplasty at the elbow, 70% carpal tunnel release, 40% scalenectomy, and 15% radial tunnel release. Three patients had a MABC neuroma. Two patients had a Guyon's canal release and one patient a pronator tunnel release. 65% of patients had concomitant tendinopathy (ten patients with trigger digits, two with deQuervain's tendinitis, and one with lateral epicondylitis at the elbow). One patient had contralateral cubital and carpal tunnel release.

Of the four patients with lower limb symptoms, surgery was performed for two infrapatellar neuromas one plantar neuropathy, and one piriformis syndrome.

In 92% of patients, there was resolution of parasthesias, color changes, allodynia, and significant increase in functional use of the limb. Patients no longer met CRPS criteria. Two patients had some persistent symptoms but were able to use the hand without allodynia.

Conclusion: Patients with CRPS findings should be specifically evaluated to find peripheral nerve compression diagnoses as well as concomitant tendinopathy. Surgical treatment for these specific diagnoses may be successful in resolving nerve symptomatology typical of patients labeled with the CRPS diagnosis.

48. The Role of Elective Amputation In Patients With Traumatic Brachial Plexus Injury

Andrés A. Maldonado, MD, PhD; Michelle F. Kirchner, MD; Robert J. Spinner, MD; Allen T. Bishop, MD; Alexander Y. Shin, MD

Mayo Clinic, Rochester, MN

Background: Despite undergoing complex brachial plexus surgical reconstructions and rehabilitation, some patients request an elective amputation. This study evaluates the role of elective amputation after brachial plexus injury.

Methods: A retrospective chart review was performed for all the 2140 patients with brachial plexus injuries treated with elective amputation between 1999 and 2012 at a single institution. Potential predisposing factors for amputation, amputation level and post-amputation complications were analyzed. Patients were evaluated using pre-amputation and post-amputation Disabilities of the Shoulder, Arm, and Hand scores in addition to visual analog pain scores.

Results: Three conditions were present in all nine of the patients who requested an elective amputation: 1. Pan-plexus injury; 2. non-recovery (mid-humeral amputation) or elbow flexion recovery only (forearm amputation) one year after all other surgical options were performed; 3. at least one chronic complication (chronic infection, non-union fractures, full-thickness burns, chronic neck pain with arm weight, etc.). Pain improvement was found in five patients. Subjective patient assessments and visual analog pain scores before and after amputation did not show a statistically significant improvement in Disabilities of the Shoulder, Arm, and Hand scores. However, four patients reported that their shoulder pain felt “better” than it did prior to amputation and two patients indicated they had no more chronic pain after surgery.

Conclusions: Elective amputation after brachial plexus injury should be considered as an option in the above circumstances. When the informed and educated decision is made, patients can have satisfactory outcomes regarding amputation.