

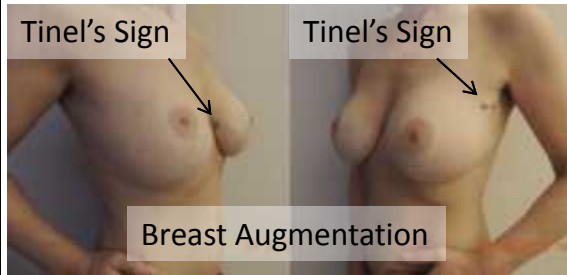
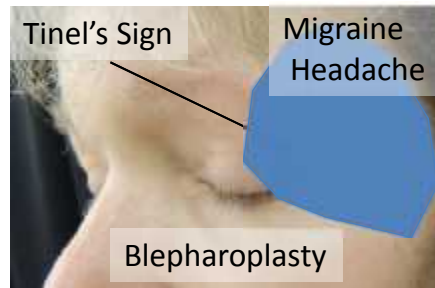
# Painful Neuroma After Cosmetic Surgery: Diagnosis and Treatment

G. Pietramaggiori, W. Raffoul, S. Scherer

Department of Plastic and reconstructive Surgery, University Hospitals of Lausanne - Switzerland

## INTRODUCTION

UP TO 40% OF COSMETIC PROCEDURES LEAD TO SENSITIVE NERVE DAMAGE

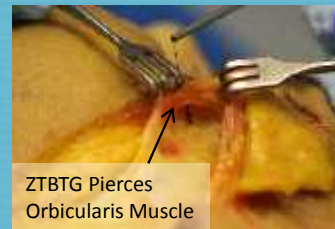
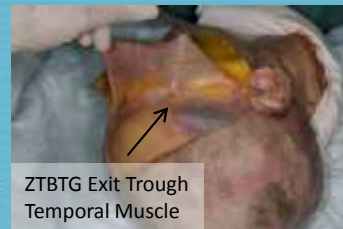

## METHODS

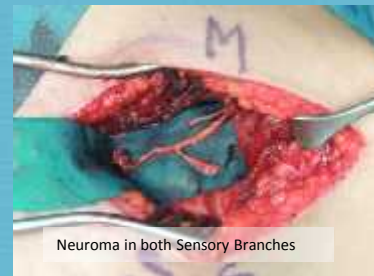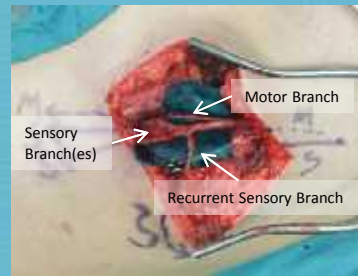
PATIENTS PRESENTED WITH INTENSE PAIN (VAS 7-8/10), IMMEDIATE ONSET AFTER SURGERY AND POSITIVE TINEL'S SIGN. A SPECIFIC NERVE BLOCK LEAD TO DIAGNOSIS OF NEUROMA.

## Anatomy Review

### Zygomatiko-Temporal Branch of Trigeminal Nerve (ZTBTN)

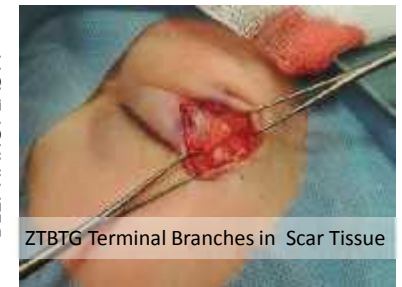

### Intercostal Nerves

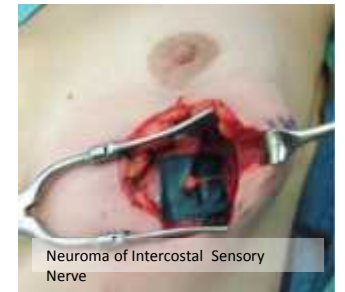

**RESULTS** SURGERY ADDRESSED THE NEUROMA BY NERUOMA EXCISION AND IMPLANTATION OF THE PROXIMAL STUMP INTO MUSCLE. PATIENTS EXPERIENCED PAIN RELIEF THAT REMAINED SIGNIFICANTLY LOWER IN INTENSITY (>5 VAS decrease ) AND FREQUENCY 6 MONTH AFTER SURGERY.

REVISION BLEPHAROPLASTY



REVISION BREAST AUGMENTATION



*Diagnosis: Nerve Blocks* ↓VAS > 5



## CONCLUSIONS

POSTOPERATIVE SEVERE PAIN THAT DOES NOT RESPOND TO CONVENTIONAL TREATMENT SHOULD BE INVESTIGATED AS POTENTIAL NEUROMA AND TREATED ACCORDINGLY.