

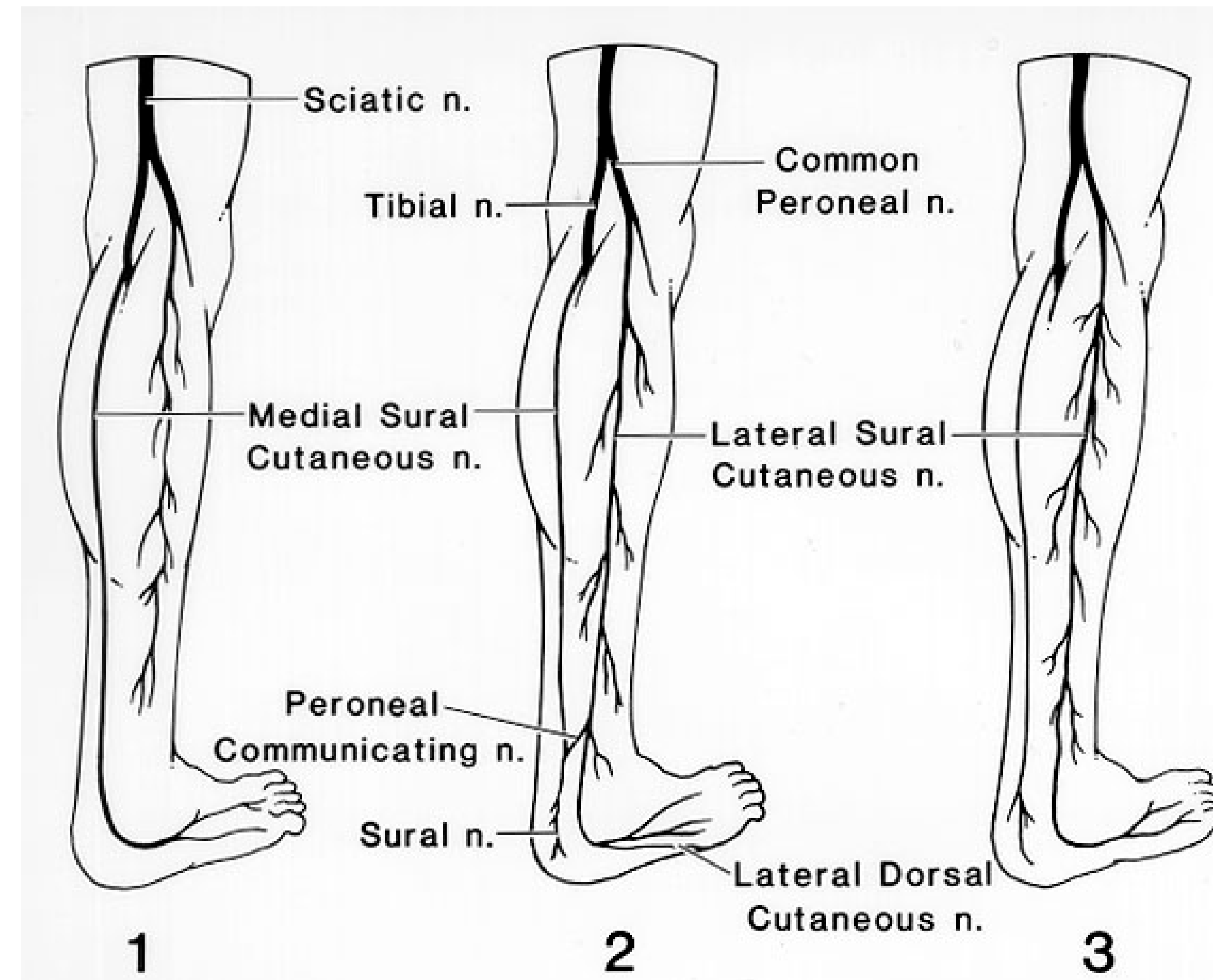


# Endoscopic Nerve Harvest for Treatment of War-Related Peripheral Nerve Injuries

Jennifer Sabino MD, Anna Romagnoli MD, George Nanos MD, Derek Ipsen DO, Patrick Basile MD, Ian Valerio MD

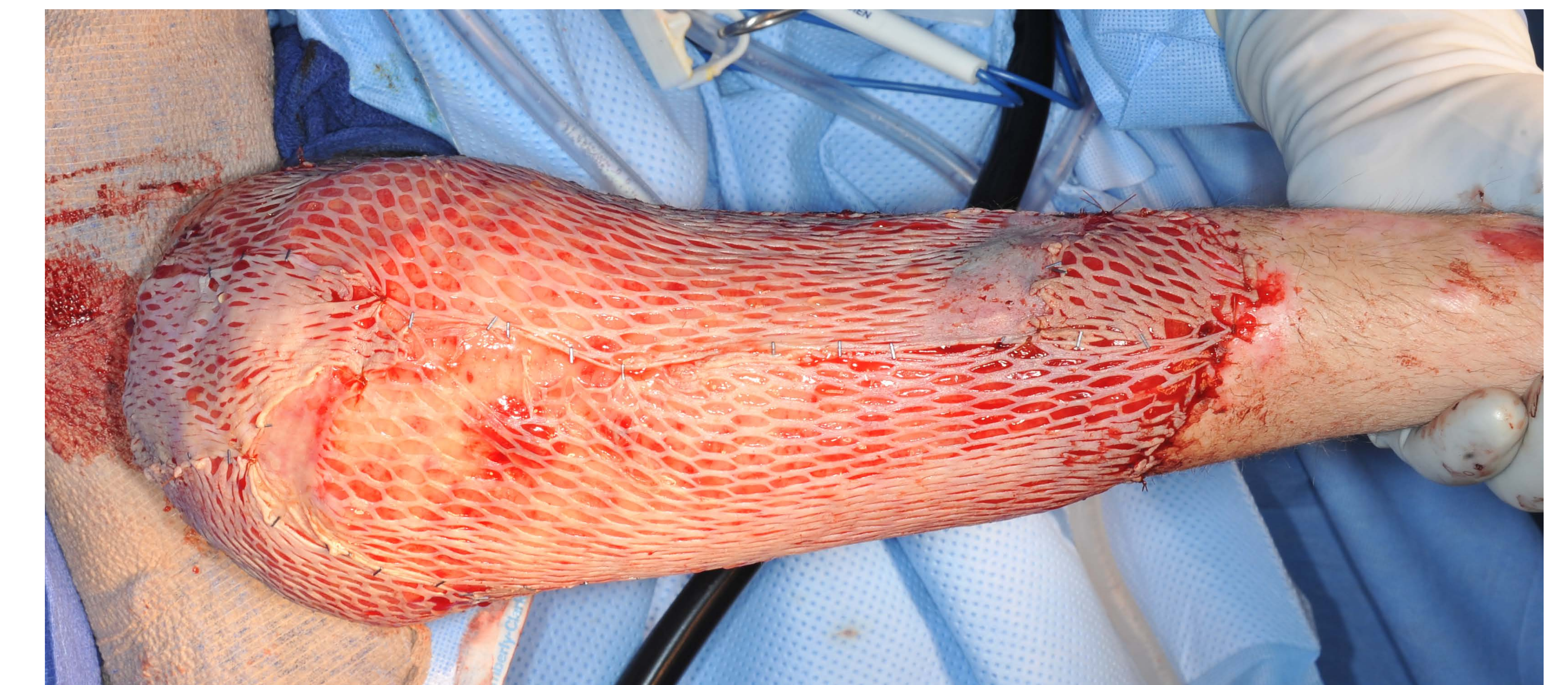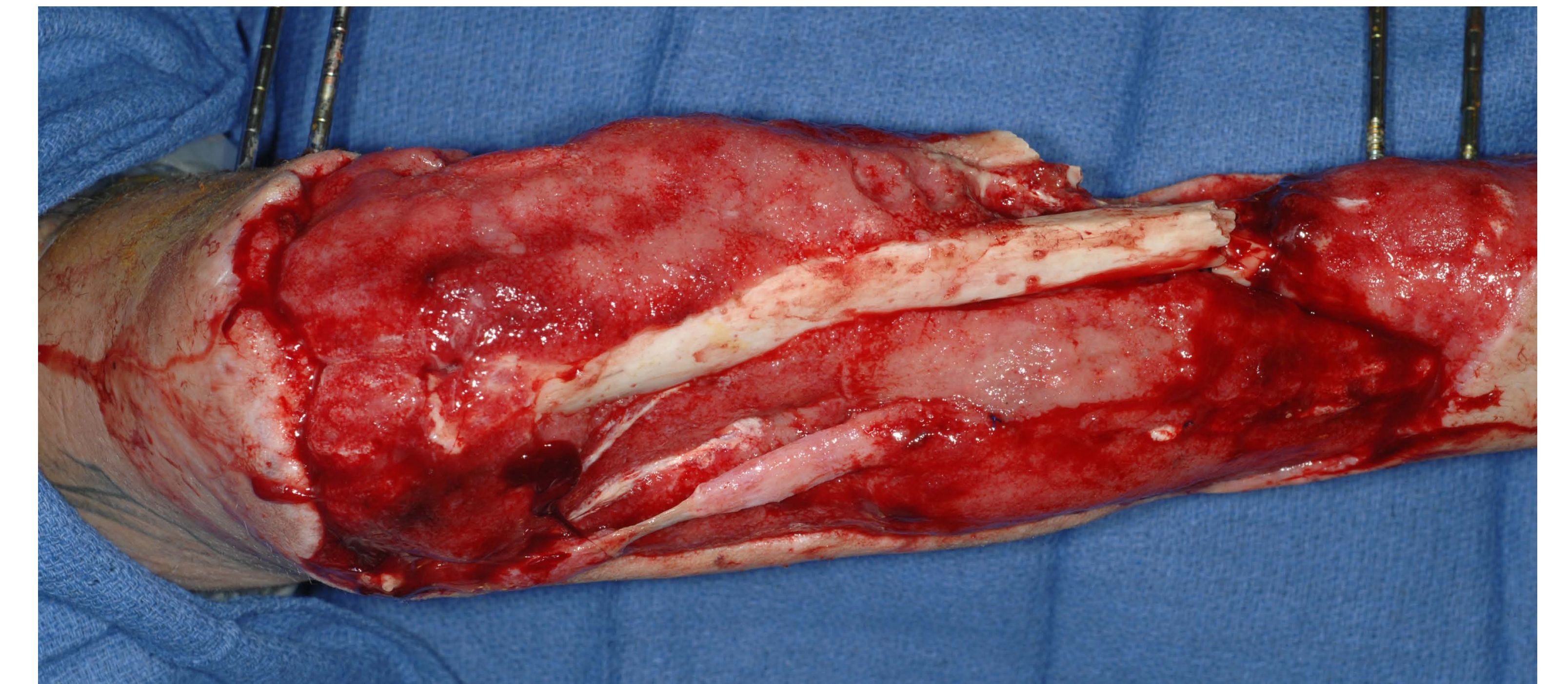Walter Reed National Military Medical Center, Bethesda, Maryland

**Introduction:** Advances in combat care results in more patients presenting to Walter Reed National Military Medical Center with corresponding high injury severity scores and multiple severely injured and/or mangled extremities. Simple and complex nerve repairs have been performed in conjunction with soft tissue transfers and complex orthopaedic procedures in an effort to salvage severely injured limbs. Reconstructive surgeons at WRNMMC have been performing an increasing number of endoscopic sural nerve harvesting to repair segmental nerve defects in both upper as well as lower extremity cases. The purpose of this study is to describe our experience with endoscopic sural nerve harvest cases in the setting of treating war-related peripheral nerve injuries.



Sural Nerve Anatomy

**Results:** From January 2010 to July 2013, 14 patients underwent endoscopic sural nerve harvesting for segmental nerve defects after war-related extremity trauma. All of the patients were male with an average age of 26 years and most commonly injured by explosive devices (36%). Nerves repaired included 6 median, 4 ulnar, 1 sciatic, 1 common peroneal, and 1 tibial nerve. In 43% of cases, the patients had concurrent vascular injuries which were repaired downrange. Median time from initial battlefield injury to definitive nerve reconstruction was 88 days (range 12-398 days). There were no significant postoperative complications secondary to nerve harvesting or nerve repair technique. Of note, 1 patient developed brachial artery graft thrombosis and another patient developed osteomyelitis of the ulna requiring further operative intervention, neither of which affected their nerve repair outcomes. The average follow up was 14 months in this series.



**Conclusion:** Endoscopic sural nerve harvesting is a useful procedure in the treatment of segmental nerve defects sustained as a result of war-related extremity trauma. The procedure is safe with favorable results and no significant complications in this analysis. Endoscopic sural nerve harvest should be considered in war and civilian limb salvage algorithms as a useful adjunct that can reduce donor site morbidity through a minimally invasive approach.

	<u>Mean</u>	<u>Median</u>	<u>SD</u>
Age (days)	25.7	24	6.4
Injury Severity Score	19.5	17	9.6
Procedures Prior	6.4	5	4.1
Days to Flap	19.7	19	8.6
Procedures After	4.3	3	2.9
Hospital Days	67.2	54	43.1

**Methods:** A retrospective review of injured Servicemembers treated for extremity injuries from 2010 through 2012 was completed. Patients who underwent endoscopic sural nerve harvesting for segmental nerve defects of the upper or lower extremity were reviewed. Data collected included patient demographics, concomitant injuries, location and severity of nerve injury or injuries. Outcomes reported included complications and functional measures.